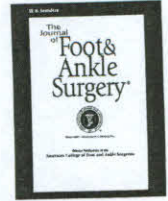




Contents lists available at ScienceDirect

The Journal of Foot & Ankle Surgery

journal homepage: www.jfas.org



Treatment of Posterior Tibial Tendon Dysfunction without Flexor Digitorum Tendon Transfer: A Retrospective Study of 34 Patients

Lawrence DiDomenico, DPM, FACFAS¹, Dawn Y. Stein, DPM², Mari Wargo-Dorsey, DPM²

¹ Section Chief, Division of Podiatry, Department of Surgery, St. Elizabeth Health Center, Youngstown; Private Practice, The Ankle and Foot Care Centers, Boardman, OH
² Resident, Heritage Valley Health System, Beaver, PA

ARTICLE INFO

Level of Clinical Evidence: 2

Keywords:

bone
double osteotomy
foot
gastrocnemius recession
morbidity
surgery

ABSTRACT

A retrospective study of patients who underwent gastrocnemius recession, double calcaneal osteotomy (Evans osteotomy and percutaneous calcaneal displacement osteotomy), and medial column fusion for the treatment of posterior tibial tendon dysfunction was conducted. The senior author performed the procedures between November 2002 and January 2009 on 34 patients who displayed at least Johnson and Strom stage II deformity and had undergone 12 months of failed conservative treatment. The coauthors evaluated the patients' radiographs before and after the operation. At a mean of 14 (range 3 to 44) months after surgery, radiographic measurements demonstrated statistically significant changes in the structural alignment of the feet. Based on our experience with these patients, we believe that a double calcaneal osteotomy combined with a gastrocnemius recession and stabilization of the medial column for the treatment of posterior tibial tendon dysfunction provides satisfactory correction, stability, and realignment of the foot. Furthermore, we feel that the use of flexor digitorum longus transfer, as well as triple arthrodesis, can be avoided without compromising the outcome when surgically treating posterior tibial tendon dysfunction.

© 2011 by the American College of Foot and Ankle Surgeons. All rights reserved.

The management of posterior tibial tendon dysfunction (PTTD) has proven to be difficult, as evidenced by the multitude of conservative and surgical treatment options available for its treatment. Failed treatment and recurrence of deformity and symptomatology are major problems associated with the conservative treatment of PTTD. Surgical correction by means of triple arthrodesis can correct the alignment of the foot, but not without sacrificing hindfoot motion.

PTTD is historically divided into 3 categories that correlate with suggested treatment options (1). Conservative treatment consisting of immobilization, bracing, orthoses, and nonsteroidal anti-inflammatory drugs (NSAIDs) is recommended during the first stage. When conservative measures fail, surgical intervention for late-stage I to stage II dysfunction must be considered. Several treatment options have been introduced throughout the years for every stage of the disease, in particular late-stage II disease. Previous studies have focused on repairing the posterior tendon (PT) coupled with a displacement calcaneal osteotomy to alleviate pain and to attempt to realign the foot. Johnson and Strom (1) favor the use of soft tissue procedures, such as a flexor digitorum longus transfer (FDLT), to augment the PT tendon.

Unfortunately, procedures such as a tenosynovectomy, tendon debridement, and FDLT can be used to provide initial pain relief, but they do not change the physical alignment of the foot (2). Therefore, the medial longitudinal arch remains in an unstable/sagging position, and the pain and deformity reoccur with time. Other investigators have combined osteotomies with soft tissue procedures for the treatment of PTTD stage II in an attempt to achieve correction of the deformity and relief of symptoms (3–5). The treatment of choice for stage III PTTD, historically, has been the triple arthrodesis, which can reposition the misaligned hindfoot and create stability. However, a major drawback with triple arthrodesis is the loss of motion in the entire hindfoot. The purpose of this retrospective cohort study was to determine whether or not a double calcaneal osteotomy (Evans osteotomy and percutaneous calcaneal displacement osteotomy) combined with a gastrocnemius recession and stabilization of the medial column can eliminate the need for triple arthrodesis and provide comparable long-term radiographic and clinical results.

Patients and Methods

The aims of this investigation were to measure radiographic variables that we feel represent the structural alignment of the foot, before and after surgical intervention for the treatment of advanced pes valgus deformity in patients suffering with PTTD. Although we recorded a number of clinical variables, including age, sex, side of involvement, complications, and duration of follow-up, our primary intent was to explore the influence of the surgery on selected radiographic measurements.

Financial Disclosure: None reported.

Conflict of Interest: None reported.

Address correspondence to: Lawrence DiDomenico, DPM, FACFAS, Private Practice, The Ankle and Foot Care Centers, 8175 Market Street, Boardman, OH 44512.
E-mail address: ld5353@aol.com (L. DiDomenico).

Patient Population

We conducted a retrospective study of consecutive patients who demonstrated PTTD and underwent double calcaneal osteotomy, stabilization of the medial column, and gastrocnemius lengthening performed by the senior author (L.A.D.) between November 2002 and January 2009. The Johnson and Strom classification system was used to categorize the stage of PTTD (1), and only those with stages II and III disease were included (Figure 1). There were no age restrictions on inclusion, and every patient had to have standard weight-bearing anteroposterior (AP) and lateral foot radiographs (Figures 2 and 3). Each of the adult patients (age ≥ 18 years) also underwent magnetic resonance imaging (MRI), which further confirmed the presence of PT tendon pathology.

All of the patients had experienced failed conservative treatment that consisted of the use of NSAIDs, rest, ice, stretching, bracing, supportive bandaging, physical therapy, and immobilization before undergoing surgical intervention. Preoperative criteria for the double calcaneal osteotomy and gastrocnemius lengthening procedure consisted of pain and impaired biomechanical function of the affected foot. Other clinical signs and symptoms included the presence of the “too many toes” sign and calcaneal valgus upon weight bearing, weakness upon attempted single heel rise, a Silfverskiold test (6) indicative of gastrocnemius equinus, flexible pes planovalgus with unlocking of the midtarsal joint, abduction of the forefoot, and decreased ankle joint dorsiflexion, as well as a markedly decreased inversion muscle strength.

Operative Procedures

Patients were placed in supine position on the operating table and administered general anesthesia, and an ipsilateral pneumatic thigh tourniquet was used to aid hemostasis. All of the patients underwent endoscopic gastrocnemius recession (7), percutaneous calcaneal displacement osteotomy (8), and Evans calcaneal osteotomy. Endoscopic gastrocnemius recession was performed via a small stab incision made medially in the posterior inferior portion of the leg in the area of the gastrocnemius aponeurosis, avoiding the greater saphenous vein and nerve. The incision was deepened in the same plane using sharp and blunt dissection, and a fascial elevator was used to slide along the posterior aspect of the gastrocnemius aponeurosis from medial to lateral, allowing separation of the deep fascia from the aponeurosis. An obturator was then inserted posterior to the gastrocnemius aponeurosis from medial to lateral and a small lateral stab incision was made. A cannula was then inserted over the obturator and cleared to enhance visualization. With the cannula facing anteriorly against the gastrocnemius aponeurosis, range of motion of the ankle joint was assessed. To ensure that the neurovascular structures, in particular the sural nerve, were not at risk of injury, the cannula was rotated posteriorly. The cannula was then returned to the anterior position and a triangle blade used to cut along the gastrocnemius aponeurosis, performing a gastrocnemius slide that allowed increased range of ankle dorsiflexion. Once the increased range of motion was identified, the equipment was removed and the skin closed using 3-0 polypropylene suture.

A percutaneous calcaneal displacement osteotomy was then performed using small stab incisions positioned at the medial, lateral, inferior, and superior aspects of the calcaneus along the relaxed skin tension lines, posterior to the sural nerve and the peroneal tendons, and posterior to the neurovascular and tendon structures in the tarsal tunnel on the medial side. The incisions were deepened to the calcaneus with subfascial dissection. All tunneling and dissection were contained in the subfascial

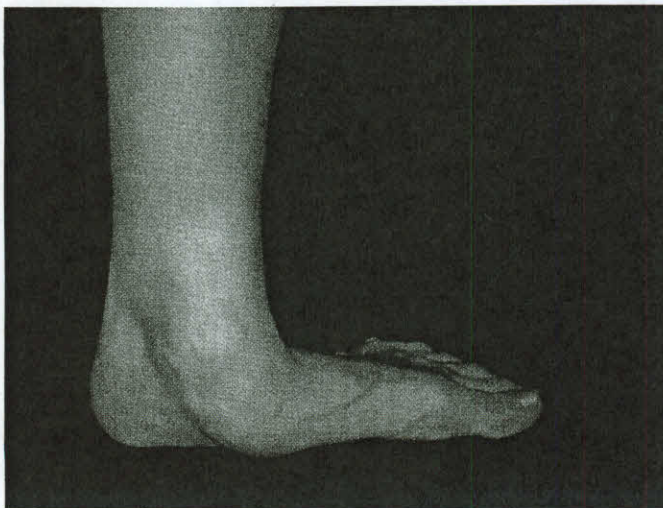


Fig. 1. Clinical appearance of a patient's left foot in this study, depicting collapse of the medial column as viewed from the medial aspect.

layer, on the bone medially, superiorly, and laterally. All 4 of the locations were connected from inferomedial to superomedial, from superomedial to superolateral, and from superolateral to inferolateral with a small Gigli saw subfacially, and the cut was verified using fluoroscopy (Figures 4 and 5). The digits and ankle were dorsiflexed to dynamically stabilize the calcaneus while the cut was executed. Once the cut was confirmed by fluoroscopy, the saw was cut on the lateral side of the calcaneus and the remainder of the device was removed medially. The osteotomy allowed the proximal portion of the calcaneus to freely move approximately 1 cm in the medial direction. Thereafter, dorsiflexion of the ankle and toes was again performed to dynamically stabilize the osteotomy, which was then fixated with two 7.3-mm cancellous interfragmental compression screws. The proximal (superior) screw had a 16-mm thread length, whereas the distal (inferior) screw had a 32-mm thread length. The proximal screw was fully tightened at this juncture; however, the inferior screw was not fully inserted until the Evans procedure was completed.

The Evans calcaneal osteotomy was undertaken after identification of the anterior process of the calcaneus was performed under fluoroscopy. An oblique incision was then made starting dorsolateral and extending plantar proximal and lateral within the resting skin tension lines on the lateral aspect of the anterior portion of the calcaneus. The dorsolateral cutaneous nerve and sural nerve were identified and avoided via retraction. The incision was deepened in the same plane to the peroneal tendons, which were superiorly and inferiorly reflected. An osteotomy was made approximately 1.5 cm proximal to the calcaneocuboid joint and an allogeneic tricortical cancellous bone graft

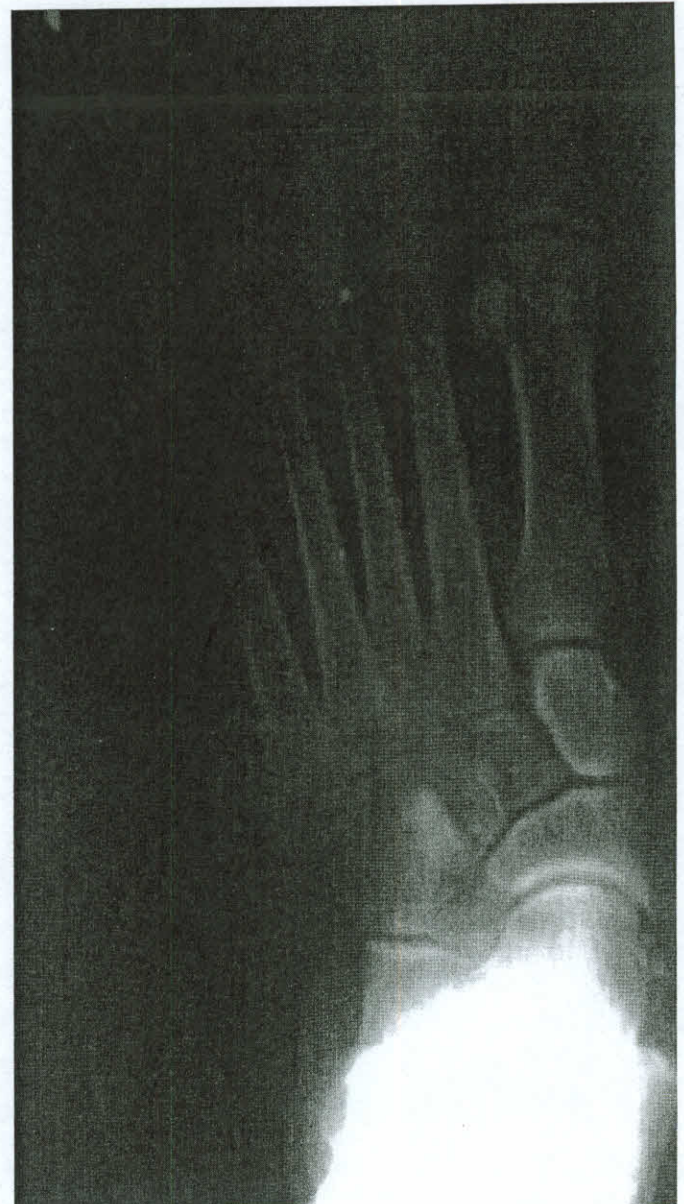

Fig. 2. Preoperative anteroposterior radiographic view of the left foot in weight bearing.

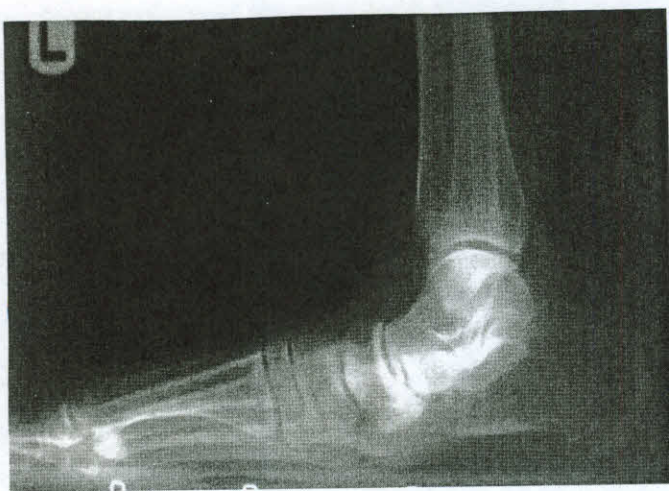

Fig. 3. Preoperative lateral radiographic view of a patient's left foot in weight bearing.

was inserted into the area with the base of the graft being lateral and the apex medial. The graft was tamped into place ensuring that it was flush to the lateral wall of the calcaneus. Fixation was completed using the inferior cancellous screw with the long-thread pattern, which had already been inserted after completion of the percutaneous calcaneal displacement osteotomy and served the dual function of providing compression at the proximal calcaneal osteotomy while the distal portion functioned as a positional screw to stabilize the Evans osteotomy and graft without compressing the bone graft.

The hypermobility along the medial column was then assessed using intraoperative fluoroscopy and range-of-motion manipulation at every joint along the medial column. Based on this assessment, an incision was made overlying the medial column and deepened through the same plane using sharp and blunt dissection avoiding all neurovascular structures. The identified unstable articulations were disarticulated, after which the tarsometatarsal, and/or naviculocuneiform, and/or talonavicular joints were packed with bone graft harvested percutaneously from the calcaneus (9) for shear strain relief at the arthrodesis interface, aligned, and then fixated with interfragmental compression screws. The wound was then closed in a standard fashion.

After the operation, a short-leg cast was applied with a 1-cm-wide strip of plaster running the length of the front of the cast removed to allow for decompression and access to the leg in the event wound care became necessary. Patients remained non-weight bearing for 6 to 8 weeks, with serial radiographs taken to gauge osseous union and integration of the graft (Figures 6 and 7).

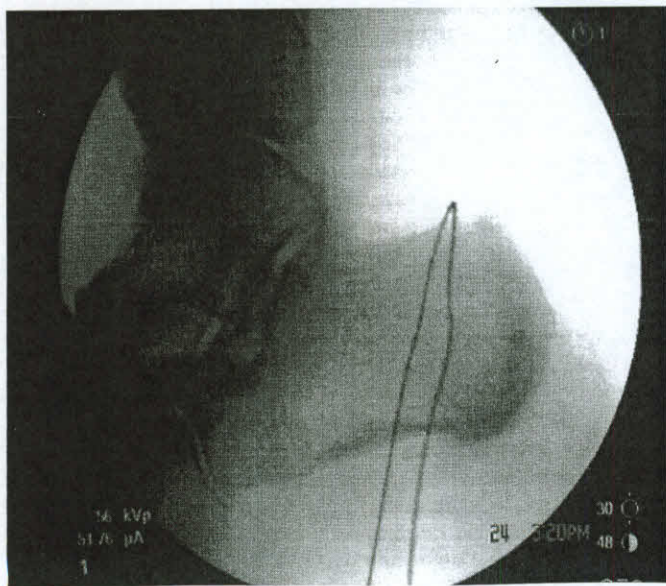


Fig. 4. Intraoperative lateral radiographic view demonstrating percutaneous calcaneal displacement osteotomy before completion of the osteotomy.

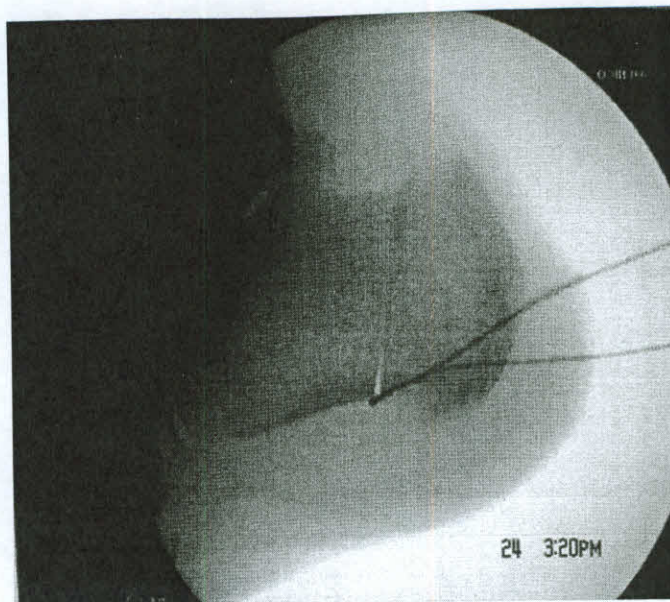


Fig. 5. Intraoperative lateral radiographic view demonstrating percutaneous calcaneal displacement osteotomy after completion of the osteotomy.

Results

A total of 34 patients met our inclusion criteria, and a statistical description of the cohort is depicted in Table 1. A first-tarsal metatarsal arthrodesis was performed on 12 (35.29%) patients who exhibited a hypermobile first ray based on the clinical evaluation of the senior author (L.A.D.) and the sequela of the patient complaint. A naviculocuneiform fusion was implemented on 6 (17.65%) patients, a talonavicular fusion in 2 (5.88%), and a combined talonavicular and naviculocuneiform fusion in 3 (8.82%) patients. The 15 (44.12%) males and 19 (55.88%) females in the cohort ranged in age from 5 to 82 (mean 38.4) years, and 14 (41.18%) left and 20 (58.82%) right feet were treated. Using the Johnson and Strom (1) classification system, all of the patients included in the study were categorized as having stage II or stage III deformity. Patients were followed postoperatively for 3 to 44 (mean 14) months. The most common postoperative complication was painful hardware of the heel, which was observed in 3 (8.82%) patients, all of who underwent a second procedure to remove the hardware. Superficial wound dehiscence was observed at the lateral calcaneus site in 1 (2.94%) patient, and this went on to heal with conservative measures, and there were 2 (5.88%) instances of delayed union that ultimately healed by 28 and 52 weeks postoperative.

All 6 of the radiographic angles that were assessed demonstrated statistically significant changes when the preoperative and postoperative measurements were compared (Table 2). Increases were noted in the calcaneal inclination and the talonavicular angles, whereas Meary's angle and the talar declination, talocalcaneal, and cuboid abduction angles decreased.

Discussion

A literature review focusing on the treatment of PTTD using a calcaneal osteotomy provided many articles that described the use of a tendon transfer to augment the function of the PT tendon (3–5). Few published reports describe the use of a calcaneal osteotomy as the single treatment of choice or a combination of calcaneal osteotomy and a medial column fusion as a treatment for PTTD. In 1995, Frankel et al (10) described a case wherein a double calcaneal osteotomy was used in conjunction with repair of the PT tendon on

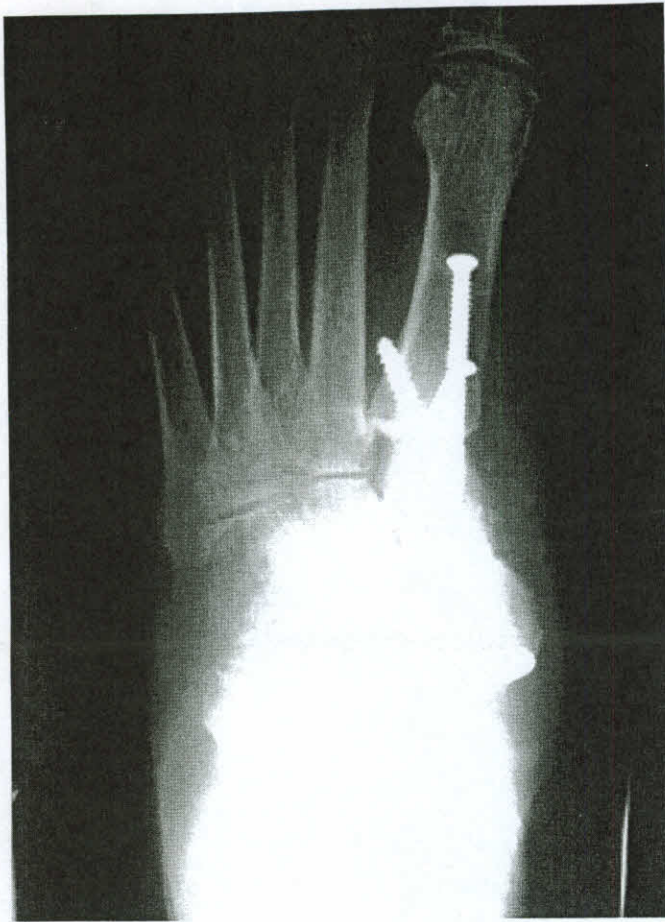

Fig. 6. Postoperative anteroposterior radiographic view of the left foot in weight bearing.

a 47-year-old female with an acute onset of symptoms. The authors of that report thought that it was important to address the apex of deformity, especially in younger patients with an acute onset of PTTD or a history of bilateral pes valgus. When treating patients similar to the one reported in this case study, using soft tissue repair alone may lead to recurrence of the deformity, whereas treatments using only an arthrodesis are often untimely when compared with reduction of mobility in correspondence to the patient's active lifestyle. The results of the study were favorable with the patient enjoying a normal gait pattern, remaining asymptomatic and pain-free, and returning to preinjury activity levels at the 11-month follow-up (10).

In 1999, Lombardi et al (11) published a retrospective study that included 12 patients who were surgically treated with a talonavicular

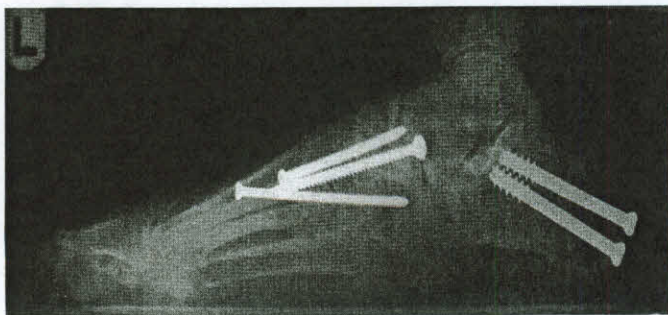


Fig. 7. Postoperative lateral radiographic view of a patient's left foot in weight bearing.

Table 1
Statistical description of the cohort (N = 34 patients)

Patient	Age (years)	Sex	Foot
1	23	Female	Left
2	71	Male	Right
3	68	Female	Left
4	49	Female	Right
5	69	Female	Left
6	16	Male	Right
7	12	Female	Right
8	54	Female	Right
9	55	Female	Right
10	82	Female	Right
11	59	Female	Right
12	52	Female	Left
13	8	Male	Right
14	11	Male	Left
15	5	Male	Left
16	47	Female	Left
17	20	Male	Left
18	30	Female	Right
19	13	Male	Right
20	12	Male	Right
21	56	Female	Right
22	62	Female	Right
23	43	Male	Right
24	50	Male	Right
25	12	Female	Left
26	12	Male	Right
27	47	Female	Left
28	31	Male	Right
29	47	Female	Right
30	14	Male	Right
31	31	Male	Left
32	26	Female	Left
33	62	Male	Left
34	57	Female	Left

joint arthrodesis and an Evans calcaneal osteotomy for PTTD. They measured the preoperative and postoperative talonavicular, talocalcaneal, and talar declination radiographic angles and found all to be of little significance, except for talar declination, and they believed that planal dominance played a role in the radiographic outcomes. The American Orthopaedic Foot and Ankle Society (AOFAS) scores, however, after omitting the "hindfoot motion" component of the score, demonstrated statistically significant improvement. Limiting, and not completely stopping "hindfoot motion," however, was their stated goal. They further stated that whereas a talonavicular fusion can lead to decreased motion in other rearfoot joints, the presence of sufficient hindfoot motion before surgical intervention enables the hindfoot to accommodate for fusion of the talonavicular joint. They further noted that there were no complaints of pain in neighboring joints of the rearfoot at the average postoperative time of 35 months, and that all of their subjects experienced decreased pain, improved gait, and a stable, plantigrade foot. They also stressed the importance of addressing the apex of the deformity in cases of PTTD (11).

More recently, Catanzariti et al (12) performed double calcaneal osteotomy and posterior muscle group lengthening in 9 flatfeet in 8 patients with an average age of 33 years and a postoperative follow-up of 12 months. In addition, 4 of their patients had PT tendon repair, 4 underwent FDL tendon transfer, 2 underwent Cotton osteotomy, and 1 had a distal first metatarsal osteotomy. They measured radiographic angles, including talar-first metatarsal, talocalcaneal, calcaneal inclination, and talar declination, and found a statistically significant change in all values postsurgery, suggesting that surgical realignment of the flexible flatfoot deformity was successful, and speculated that it may decrease the need for arthrodesis and allow for a more mobile foot during gait, thereby decreasing the incidence of arthritis in the ankle over time (12).

Table 2
Comparison of radiographic preoperative and postoperative measurements (N = 34 patients)

Radiographic Angle (°)	Preoperative, Mean (minimum, maximum)	Postoperative, Mean (minimum, maximum)	Change, Mean (minimum, maximum)	P Value*
Calcaneal inclination	15.8 (8, 24)	21.0 (12, 30)	5.2 (–2, 16)	.001
Talar declination	29.6 (21, 38)	25.4 (18, 32)	–4.2 (0, –14)	.001
Meary's	12.2 (2, 20)	8.0 (2, 14)	–4.2 (0, –13)	< .001
Talonavicular	56.1 (28, 80)	72.3 (52, 89)	16.2 (–6, 37)	.004
Cuboid abduction	13.1 (0, 28)	5.4 (0, 12)	–7.7 (1, –21)	< .001
Talocalcaneal	33.9 (15, 62)	20.7 (8, 32)	–13.2 (9, –44)	.071

* Paired Student's *t* test.

Hansen (13) identified what were termed essential, nonessential, and unnecessary joints of the foot and ankle. Unnecessary joints were described as ones that have very little mobility during gait because they are stabilized by rigid ligaments; therefore, these joints may be fused with little effect on the rest of the foot. A nonessential joint was described as one with mobility, and that does not transfer stress to nearby or adjacent joints; therefore, such a joint can be fused with little or no disability. Essential joints were described as those that have complete mobility and would limit function if fused, and included the ankle, subtalar, talonavicular, and lesser metatarsophalangeal joints. Hansen went on to suggest that essential joints be “protected at almost any cost” (13). It is interesting to note that the technique that we have described in this article, avoidance of triple arthrodesis, preserves essential joints, with the exception of the talonavicular joint, which was fused in 5 cases because of severe medial column misalignment with substantial degenerative arthritic change.

More recently, the etiology of PTTD has been examined, and a number of sources have extended the theory that the pathomechanics of a preexisting pes valgus foot type may contribute to the tendon's dysfunction (10, 14, 15). The most problematic area of the posterior tibial tendon tends to be where it curves around the medial malleolus, which acts as a pulley (16). Fujii et al (14) noted increased resistance in the gliding ability of the PT tendon around the medial malleolus in a simulated cadaveric flatfoot, and suggest that an underlying flatfoot deformity may contribute to the development of PTTD (14). With this in mind, correction using only a tendon transfer would present a risk for recurrence, as the underlying etiology would not be addressed and the PT tendon would remain at risk for further injury because of the biomechanics of the foot and impending stress on the tendon. A biomechanical analysis by Arangio and Salathe (17) in 2009 suggested that a flexor digitorum longus tendon transfer did little when combined with a medial displacement calcaneal osteotomy with regard to reducing load on the medial column of the foot; however, the osteotomy itself greatly reduced that load.

Historically, triple arthrodesis was deemed the gold standard for treatment of the advanced pes valgus associated with PTTD. Literature has revealed that pain often persists over time after surgical intervention using triple arthrodesis, and progressive degenerative changes have also been demonstrated not only in the vicinity of the ankle, but the midfoot as well (18). A double calcaneal osteotomy can be performed without compromising the motion of the rearfoot, and we feel that this is important over the long run following reconstruction.

Like most retrospective investigations, we realize that our study was affected by a number of methodological limitations that could threaten the validity of our conclusions. For instance, bias was likely introduced because the surgeons who performed the operations also abstracted the data from the records and evaluated the radiographs. We feel, however, that this could not have been avoided, as our practice is such that we do not have independent investigators available to design and execute clinical studies. We did employ an independent statistician to carry out the analyses. We also realize that

we did not identify some independent variables that other surgeons would consider important relative to the care of patients with PTTD; however, our intent was not to carry out an explanatory analysis, rather to explore the influence of the combinations of procedures on the structural alignment of the foot as measured radiographically. Moreover, we did not obtain magnetic resonance images (MRIs) to identify tendon degeneration in our younger patients (< 18 years of age); however, as stated, our goal was to measure the radiographic changes related to alignment of the foot. Furthermore, we appreciate the fact that radiographic measurements need not correlate with subjective patient satisfaction, although it is our experience and understanding that restoration of a more balanced alignment of the joints of the foot generally results in a satisfied patient.

In conclusion, our study demonstrated statistically, and clinically, significant radiographic evidence of correction of pedal alignment in cases of PTTD when surgically intervening with gastrocnemius recession, double calcaneal osteotomy, and medial column fusion based on the needs of certain joints, which are considered “nonessential.” By addressing the apex of the flatfoot deformity and relieving pathological stress of the PT tendon, this combination of the procedures redirects the loading forces in the foot, recreates stability in the medial longitudinal arch, and ultimately relaxes tension in the PT tendon. This combination of procedures restores alignment of foot structure while preserving joint motion, which would be lost following triple arthrodesis. Choosing to perform this surgery over a flexor digitorum longus tendon transfer poses several other benefits for both the surgeon and the patient, including a decrease in surgical time and one less incision, which we feel further decreases postoperative edema and overall morbidity. We also believe that the results of this investigation can be used in the development of future prospective cohort studies and randomized controlled trials that focus on surgical management of PTTD.

Acknowledgments

The authors acknowledge the work of Alan G. Glaros, PhD, Associate Dean and Professor, of Kansas City University of Medicine and Biosciences, for undertaking the statistical analysis of the data used in this investigation.

References

- Johnson KA, Strom DE. Tibialis posterior tendon dysfunction. *Clin Orthop* 239:197–206, 1989.
- Jahss MH. Tendon disorders of the foot and ankle. In *Disorders of the Foot and Ankle: Medical and Surgical Management*, ed 2, edited by MH Jahss, W.B. Saunders, Philadelphia, 1991.
- DiPaola M, Raikin SM. Tendon transfers and realignment osteotomies for treatment of stage II posterior tibial tendon dysfunction. *Foot Ankle Clin* 12(2):273–285, 2007.
- Myerson MS, Badekas A, Schon LC. Treatment of stage II posterior tibial tendon deficiency with flexor digitorum longus tendon transfer and calcaneal osteotomy. *Foot Ankle Int* 25(7):445–450, 2004.
- Sammarco GJ, Hockenbury RT. Treatment of stage II posterior tibial tendon dysfunction with flexor hallucis longus transfer and medial displacement calcaneal osteotomy. *Foot Ankle Int* 22(4):305–312, 2001.

6. Silfverskiold N. Reduction of the uncrossed two-joint muscles of the leg to one-joint muscles in spastic conditions. *Acta Chir Scand* 56:315, 1924.
7. DiDomenico LA, Adams HB, Garchar D. Endoscopic gastrocnemius recession for the treatment of gastrocnemius equines. *J Am Podiatr Med Assoc* 95(4):410–413, 2005.
8. Dull JM, DiDomenico LA. Percutaneous displacement calcaneal osteotomy. *J Foot Ankle Surg* 43(5):336–337, 2004.
9. DiDomenico LA, Haro AA III. Percutaneous harvest of calcaneal bone graft. *J Foot Ankle Surg* 45(2):131–133, 2006.
10. Frankel JP, Turf RM, Kuzmicki LM. Double calcaneal osteotomy in the treatment of posterior tibial tendon dysfunction. *J Foot Surg* 34(3):254–261, 1995.
11. Lombardi CM, Dennis LN, Connolly FG, Silhanek AD. Talonavicular joint arthrodesis and Evans calcaneal osteotomy for treatment of posterior tibial tendon dysfunction. *J Foot Surg* 38(2):116–122, 1999.
12. Catanzariti AR, Mendicino RW, King GL, Neerings B. Double calcaneal osteotomy realignment considerations in eight patients. *J Am Podiatr Med Assoc* 95(1):53–59, 2005.
13. Hansen ST. Surgical principles. In *Functional Reconstruction of the Foot and Ankle*. pp 10, 31, edited by ST Hansen, Lippincott, Williams & Wilkins, Hagerstown, MD, 2000.
14. Fujii T, Uchiyama E, Kitaoka HB, Luo ZP, Zhao KD, An KN. The influence of flatfoot deformity on the gliding resistance of tendons about the ankle. *Foot Ankle Int* 11:1107–1110, 2009.
15. Banks AS, McGlamry ED. Tibialis posterior tendon rupture. *J Am Podiatr Med Assoc* 77:170–176, 1987.
16. Petersen W, Hohmann G, Pufe T, Tsokos M, Zantop T, Paulsen F, Tillman B. Structure of the human tibialis posterior tendon. *Arch Orthop Trauma Surg* 4:237–242, 2004.
17. Arangio GA, Salathe EP. A biomechanical analysis of posterior tibial tendon dysfunction, medial displacement calcaneal osteotomy and flexor digitorum longus transfer in adult acquired flatfoot. *Clin Biomech* 4:385–390, 2009.
18. Saltzman CL, Fehle MJ, Cooper RR, Spencer EC, Ponseti IV. Triple arthrodesis: twenty-five and forty-four-year average follow-up of the same patients. *J Bone Joint Surg Am* 10:1391–1402, 1999.