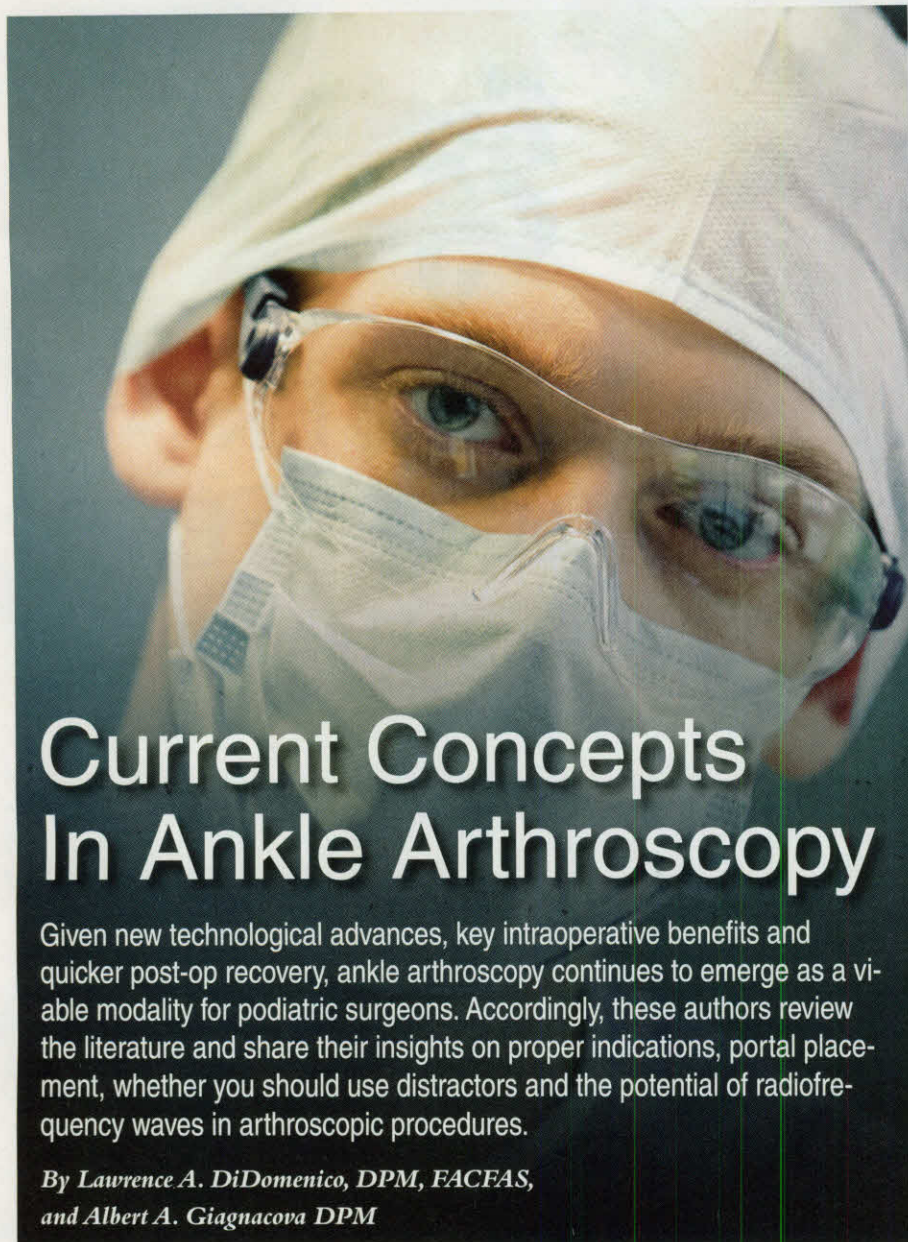

Current Concepts In Ankle Arthroscopy

Given new technological advances, key intraoperative benefits and quicker post-op recovery, ankle arthroscopy continues to emerge as a viable modality for podiatric surgeons. Accordingly, these authors review the literature and share their insights on proper indications, portal placement, whether you should use distractors and the potential of radiofrequency waves in arthroscopic procedures.

By *Lawrence A. DiDomenico, DPM, FACFAS,*
and *Albert A. Giagnacova DPM*

Ankle arthroscopy is still considered a somewhat new and exciting addition to the armamentarium for the foot and ankle surgeon. Typically, this is a physician and patient friendly procedure that allows direct visualization of intra-articular structures without the need of an open arthrotomy or malleolar osteotomy in order to gain access to the ankle joint.

The most significant advantage of ankle arthroscopy is the direct visualization of intra-articular pathology. The minimal dissection required for the placement of the ankle portal is a distinct advantage in comparison to open arthrotomy. The minimal

disruption of the soft tissue envelope is paramount in the reduction of healing time. For this reason, violation of soft tissue layers is rarely an issue when considering ankle arthroscopy as opposed to more traditional techniques such as an open arthrotomy.

Key technological advances in fiber optics, cameras, video screens, instrumentation and advanced surgical techniques have resulted in an improved ability to perform diagnostic and therapeutic arthroscopy of the ankle.

Ankle arthroscopy is a valuable tool for the foot and ankle surgeon who is diagnosing and treating various ankle conditions. More recently, additional surgical

techniques are developing with the intention of minimizing exposure and reducing the risk to the patient. Ankle arthroscopy provides the surgeon and the patient a better means for facilitating surgical outcomes. This includes an improved, quicker postoperative recovery in comparison to traditional open procedures.

A Closer Look At Indications And Contraindications

Prior to a patient undergoing an ankle arthroscopy procedure, it is a considerable advantage for the surgeon to gather additional information through diagnostic testing. It is helpful to pursue basic laboratory testing to obtain complete blood cell count and differential, uric acid levels, and inflammatory markers, such as erythrocyte sedimentation rate (ESR) and C-reactive protein (CRP). Rheumatoid panels can be beneficial for patients who have a non-traumatic etiology.

Standard plain radiographic films along with specialized stress views are necessary to evaluate the structural alignment of ankle. Magnetic resonance imaging (MRI) is an excellent adjunctive tool for the evaluation of soft tissue and articular lesions. One may also consider computed tomography (CT) and specialized bone scans.

Since Takagi and colleagues first performed arthroscopic evaluation of the ankle in 1939, much has changed.¹ While the theory of ankle arthroscopy has not changed significantly, ankle arthroscopy has evolved to become a fundamental tool in the treatment of several conditions associated with ankle disorders. As the technology has improved, there has been a notable increase in the indications for ankle arthroscopy.

Some suggested diagnostic indications include chronic edema, stiffness, instability, hemarthrosis and audible locking or snapping on the joint.

Other specific pathologies may include congenital bands, scar tissue, rheumatoid

arthritis, pigmented villonodular synovitis and synovial chondromatosis.

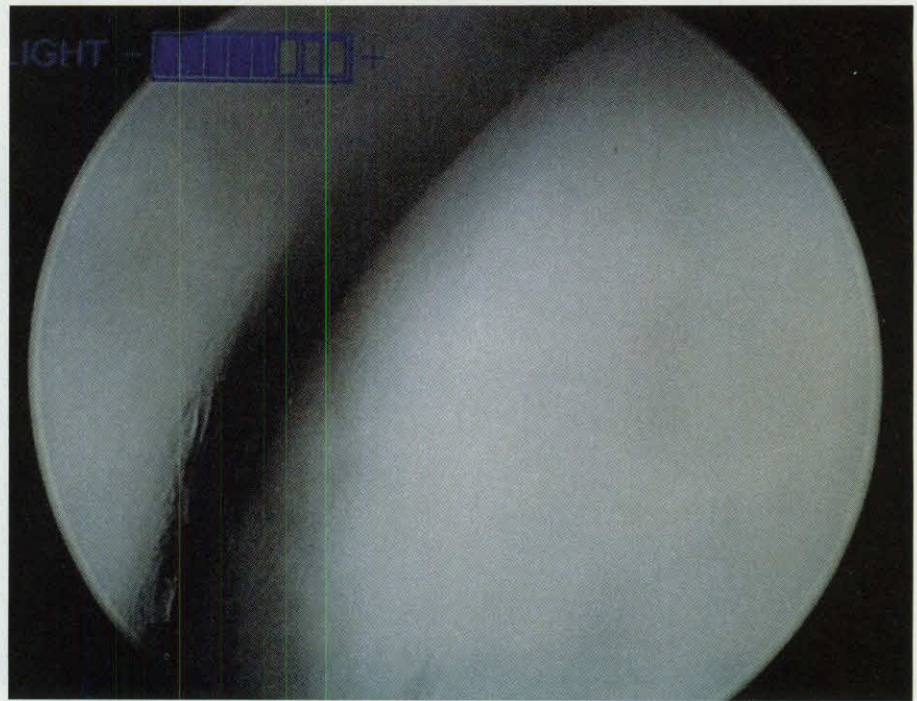
More common conditions include osteochondral lesions of talus, bony impingement, synovitis, loose bodies, arthrofibrosis, articular cartilage damage and syndesmotic impingement. Surgeons also commonly use ankle arthroscopy: to assist with reduction techniques in cases of open reduction and internal fixation (ORIF); for debridement of synovitis and fibrous bands; to repair capsular and ligamentous tears/injuries; for post-traumatic arthritis; and for tibiotalar arthrodesis.

Stetson and Ferkel noted the use of ankle arthroscopy in the management of chondromalacia and osteoarthritis.² Researchers have also discussed the use of ankle arthroscopy to treat osteochondritis dissecans lesions. Note that osteochondritis dissecans lesions are typically inflammatory in nature while most other lesions in the ankle such as osteochondral lesions of the talus are traumatic in nature.³ Inversion injuries account for two distinct areas of osteochondral lesions: anterior-lateral and posterior-medial of the talus. Patients with chronic ankle sprains as well as those with ankle fractures may benefit from ankle arthroscopy as these injuries are sometimes subtle.⁴

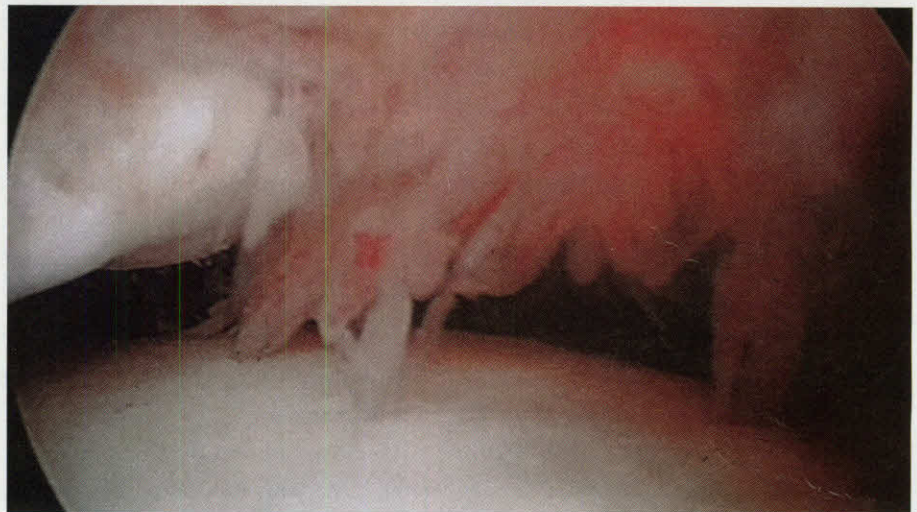The most common contraindications for arthroscopy are soft tissue infection, severe edema and poor blood supply. It is also relatively contraindicated in patients with open epiphysis. One should cautiously screen patients with a history of chronic regional pain syndrome for this procedure due to some reports of neurologic insult after this procedure.² The management of septic arthritis is polarizing and surgeons should consider their community standard.

Pertinent Insights On Portal Creation

The success with arthroscopic procedures lies in the understanding of overall anatomy and the portal placements. In order to avoid



This intraoperative arthroscopic view demonstrates the medial shoulder/gutter of an ankle joint, which is relatively free of synovitis.



Here one can see an intraoperative arthroscopic view of an ankle with a combination acute hemorrhagic and chronic synovitis.

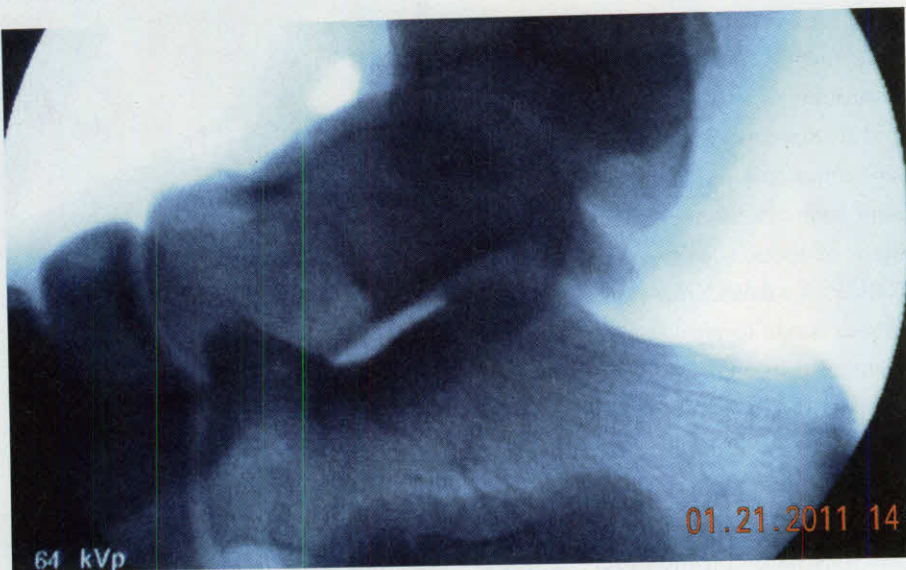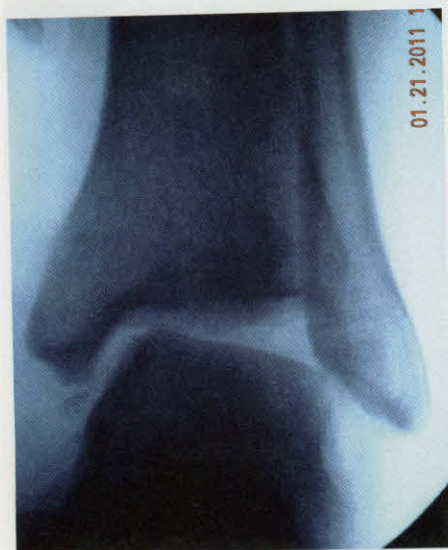vital neurological structures, the surgeon must have a keen sense of the anatomy and pathology he or she is treating.

Before portal placement, make a small stab incision at the level of the ankle joint just medial to the anterior tibialis tendon. Identifying the anatomic site before making the incision can prevent distortion of the local anatomy once one injects the fluids.

Proceed to inject and distend the ankle joint with lactated Ringer's solution in the medial portal. Not only is this helpful in

distending the joint, it provides a diagnostic value. If it is difficult to inject the little volume (10 to 15 mL) of lactated Ringer's solution into the joint, this is suggestive of a joint with much pathology such as adhesive capsulitis and fibrous bands as the joint has limited ability to expand. In scenarios in which a large volume (greater than 40 mL) of lactated Ringer's solution is allowed, typically the surgeon will notice a fluid collection that is characteristically located lateral to the ankle joint. This is suggestive of a capsular tear.

Ankle Arthroscopy



These intraoperative ankle stress radiographs demonstrate a pathological ankle with a positive talar tilt and anterior drawer sign.

Portal placement is the most critical detail of arthroscopy. Traditionally, surgeons utilize anteromedial and anterolateral portals. Create the anteromedial portal just medial to the tibialis anterior tendon and slightly distal to the joint line. We suggest employing an 18-gauge, 1.5-inch needle to locate the joint and using this as a reference point. Multiple authors recommend making this portal first.^{5,6}

The surgeon should create the anterolateral portal just lateral to the peroneal tertius tendon and within the joint. Transillumination is a technique in which one can use the arthroscope to illuminate the joint. One can easily perform this by tangentially turning the arthroscope in order to create an adjacent anterior portal. However, surgeons should exercise caution with the anterior-lateral portal coursing near the superior peroneal nerve branch, which may be at risk.^{5,7}

If a surgeon needs to address an ankle posteriorly, a posterior-lateral portal will allow for excellent exposure. Establish this portal just 1 to 1.5 cm from the lateral aspect of the Achilles tendon and proximal to the distal tip of fibula. One can utilize this portal in cases in which the pathology is located in a more posterior direction and

may also use this site as an egress. The posterior anatomic landmarks are easily visible and the portals are not difficult to create.⁵

One of the main advantages of arthroscopy to the surgeon is the freedom of accessory portal placement. These portals allow improved access to the anatomical pathology, which one cannot appreciate from the standard portals of the ankle joint. Specific or unique pathology may necessitate the need for the creation of these portals.

Typically, the most discussed accessory portal is the trans-Achilles portal, which is also known as the posterior-central portal.⁵ The rationale for this portal, as deemed by Tryfonidis and colleagues, is farther proximity from the nerves in comparison to the other main portals.⁸ The authors concluded this was the safest portal for its proximity alone. Some considerations in creating an accessory portal are improved visualization, the creation of a drain, assistance with arthroscopic procedures and improved access for surgical instruments.

The primary concern when using accessory portals is the proximity of neurovascular structures. This concern is a good reason to avoid deviating from the standard portals. Rodeo and co-workers

stated that neurological complications appear directly related to incorrect portal placement.⁹ For historical purposes, we should mention that the posterior-medial portal, which one creates medial to the Achilles tendon, should ideally be between the flexor hallucis longus and the flexor digitorum longus. The proximity of the posterior tibial nerve, artery and vein make this portal placement dangerous. When possible, one should stick with the traditional portal placements in order to reduce the risk of damage to the anatomic structures.^{2,7}

Should You Use Distractors?

A largely debated topic with arthroscopy techniques is the use of distractors. One school of thought is that there is no inherent need for ankle distraction and that the natural contour of the ankle joint allows relative ease for arthroscopic investigation. However, there is still a large group of surgeons who prefer the distraction option.

There are two distinct methodologies when selecting the use of distractors. Invasive distractors such as an AO femoral distractor rely on the surgeon to insert pins into the distal tibial and calcaneus.¹⁰

Ankle Arthroscopy

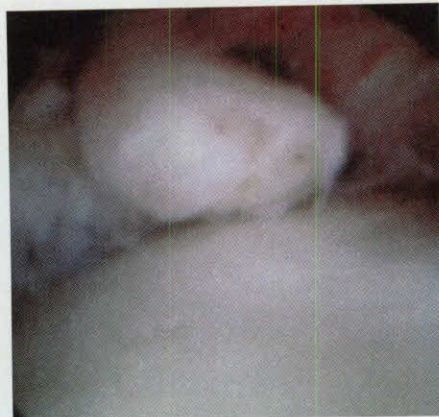Then the surgeon may perform mechanical distraction with a compression/distraction apparatus. One disadvantage of invasive distraction is the potential to cause stress risers as well as transient pin tract pain.^{5,10}

Non-invasive distractors are typically based on Guhl's design, also described as "clove-hitch."¹¹ They provide a cost-effective approach to non-invasive ankle distraction without compromising quality or versatility. The Guhl design relies on a "harness" type device that secures the hindfoot posteriorly and midfoot anteriorly, creating a strapped device. With the "harness" device, one must be careful with the length of time and constant pressure applied to the dorsum of the midfoot as this can lead to nerve irritation. With this device, one may employ a gravity technique with the non-invasive distractor to provide a pulling downward force to obtain a distracted ankle (with or without weights).

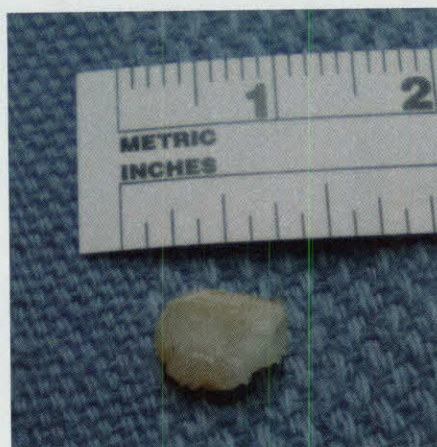One can also use a traction device and sterile bar to create a gradual distraction of the joint by providing torque.³ Stetson and co-workers recommend that the distraction of the ankle joint should not exceed 7 to 8 mm of distraction and say there should be no longer than 90 minutes of distraction for any distraction technique.^{5,6}

Mechanical distraction provides more access to the joint and causes little risk to the neurologic structures. Ferkel and colleagues showed there is a 9 percent rate of neurologic complications.⁷

Most commonly, patients develop a transient neuropraxia, a nerve injury that is largely due to stretch on the nerve itself. Transient neuropraxia may occur with more than one hour of distraction and 30 pounds of force. Electromyograms (EMGs) have shown changes in conduction velocity that are reversible.⁷ Distractors are also associated with another



Here one can see an intraoperative view of a loose body "joint mouse."



Here one can see the loose body "joint mouse" on the back table following removal from the ankle joint.

distinct pattern of injuries, including paresthesias of the superficial peroneal nerve and its branches.²

Other Considerations In Ankle Arthroscopy

Another issue is the usage of lavage, which provides a cooling effect to the instruments and avoids thermal damage to structures. Many have discussed the use of lactate Ringer's solution versus normal saline. Normal saline provides better visualization in terms of clarity of the video screen. However, normal saline is damaging to chondrocyte metabolism and one should avoid using it in cartilage stimulating procedures.

Based on the literature from knee arthroscopy, lavage techniques are consid-

ered as a principal treatment. It is our experience that this also appears to have favorable effects on the ankle joint. However, following a literature search, we found no studies that support or deny this benefit.

Other controversies include the use of tourniquets in the presence of ankle arthroscopy. Exsanguination provides better visualization of the joint for the surgeon but also diminishes the appreciation of vascular pathologies such as acute hemorrhagic synovitis and pigmented villonodular synovitis. While the use of tourniquets is up to the surgeon's preference, this consideration should be largely pathology driven.

The most common sizes of scopes are 4.0 mm, 2.7 mm and 1.9 mm although the scope selection is surgeon specific.³ In our experience, the 4.0 mm scope provides the better view and allows for a more efficient procedure.

After selecting a scope, consider the functional motions of sweeping, pistoning and rotation. Perform sweeping motions in either a side-to-side manner or an up and down movement. Pistoning involves moving the tip of arthroscope closer to the object to magnify it. However, be aware that pistoning decreases the overall field of vision of the joint. In turn, moving away from an object will give a larger visualization of the joint.

Rotation involves moving or spinning the scope in a 360-degree pattern. Most scopes have specific angulations to their tips, which are usually 30 or 70 degrees. The surgeon can appreciate pathology acutely from the direct line of vision. The concept of triangulation is a mixture of sweeping, pistoning and rotation of the scope along with instrumentation.

In recent times, some have advocated the use of arthroscopy for the preparation of ankle joint arthrodesis. This technique uses a minimally invasive ap-

Ankle Arthroscopy

proach to fusion with little disruption of the soft tissue joint envelope. Surgeons can use abrasion and arthroscopic curettage for joint preparation.

In an AAOS study of patients who underwent either arthroscopic subtalar arthrodesis or arthroscopic ankle arthrodesis, Tasto was able to achieve bone fusion at an average of 10.8 weeks.¹² The study showed seven delayed unions/non-unions out of a total of 60 fusions.

However, the joint preparation time is vastly increased and complete removal of the subchondral plate is in question. The ability to address varus/valgus deformity of the ankle is limited with this technique. Stetson and Ferkel warned that this technique could also create a deformity.²

The management of osteochondral lesions has long been a topic of discussion. These lesions are traumatic in nature secondary to inversion injuries. The smaller osteochondral defects have traditionally responded well to arthroscopic drilling, which leads to the development of fibrocartilage.

Numerous studies have demonstrated that drilling or curettage of osteochondral lesions has excellent functional outcomes and reduction of pain. In these scenarios, Barnes and Kumai noted the drilling of defects is successful, specifically with younger patients and with no cystic changes present.^{3,13} The arthroscopic drilling of lesions provides good intermediate management until further arthrosis occurs within the joint.^{13,14}

The ideal scenario for drilling involves the absence of cartilage within the osteochondral defect.¹⁵ Many specialized types of arthroscopic equipment are available to perform this technique. They include specialized guides such as a micro-vector drill guide or anterior cruciate ligament guide.³ If this sophisticated equipment is not avail-

able, surgeons may use conventional dorsiflexing and planatarflexing of the ankle and a drill.

What About Thermal Capsulorrhaphy And Radiofrequency Waves?

The concept of thermal capsulorrhaphy involves the use of a monopolar device to shrink soft tissue pathology. The thermal energy alters collagen triple helix bonds between 60°C to 75°C. At this point, fibroblasts incorporate into the collagen framework, creating Type I collagen, which forms within 72 hours and produces a new collagen in 12 to 14 weeks.¹⁶ This technique is excellent in the destruction of fibrous band and removal of intermediate pigmented villonodular synovitis.

Some have suggested this thermal capsulorrhaphy for the correction of anterior talofibular ligament damage. However, the effectiveness of this technique and long-term success is relatively low and limited. Hyer and colleagues stressed that none of these patients had any mechanical instability and this was a way to relieve any micro-tears or patulous.¹⁵

In another study, Kahn and Fanton used preoperative and postoperative stress views (talar tilt and anterior drawer) to evaluate the instability of the ankle.¹⁷ After a follow-up of one to 2.5 years, they found that talar tilts improved on average from 9.1 degrees to 6.7 degrees and anterior drawer tests showed an improvement from 8 mm of displacement to 2.4 mm. The overall American Orthopaedic Foot and Ankle Society (AOFAS) scores improved dramatically as well from 57.5 preoperatively to 86.5 postoperatively with thermal capsulorrhaphy.¹⁷ Long-term studies with imaging surveillance are needed.²

Another form of arthroscopic energy relies on radiofrequency waves. Specific probes

have been created and advocated for the treatment of chondromalacia within the further specialization of ankle arthroscopy. Surgeons may use the radiofrequency waves in specialized arthroscopic wands to treat chondral defects via thermal debridement of these lesions. In addition to the debridement mechanism of action, the radiofrequency waves thermally seal the lesions. This prevents the synovial membrane from releasing inflammatory epitopes, such as metalloproteinases, prostaglandins, tumor necrosis factor (TNF), interleukin-1 (IL-1) and free radicals, thus eliminating the inflammatory cascade.¹⁸

Lu and co-workers found temperature management of arthroscopic fluids to be critical to the success of this technique.¹⁹ The evidence shows that these radiofrequency waves can treat areas of defect without affecting any healthy chondrocytes adjacent to these defects.^{19,20}

In Conclusion

Ankle arthroscopy provides minimally invasive diagnostic benefit and therapeutic treatment of the ankle joint. It provides protection to the soft tissue envelope and provides good intermediate management of ankle pathology. In the presence of multiple intra-articular pathologies, the arthroscopic surgery allows the surgeon to provide treatment for all pathologies with one modality.

Typically, the overall patient satisfaction is high and ankle arthroscopy continues to be an effective surgical procedure for the patient and physician. These arthroscopic techniques provide the diagnostic visualization of intra-articular pathology and represent ever emerging therapeutic strategies for the foot and ankle surgeon.

In order to optimize the best results for the patient, it is imperative for the surgeon to recognize and avoid all possible complications. One should appreciate the multiple details involved with this procedure. Similar to most other surgical procedures, ankle

arthroscopy enables the surgeon to stimulate the body's natural biologic response in order to promote healing.

Overall, ankle arthroscopy is a powerful tool and one should consider it for most early to intermediate intra-articular pathologies. ■

Dr. DiDomenico is affiliated with the Forum Health/Western Reserve Care System in Youngstown, Ohio. He is the Section Chief of Podiatry at St. Elizabeth's Hospital in Youngstown, Ohio. He is the Director of the Reconstructive Rearfoot and Ankle Surgical Fellowship within the Ankle and Foot Care Centers and the Ohio College of Podiatric Medicine. Dr. DiDomenico is a Fellow of the American College of Foot and Ankle Surgeons.

Dr. Giagnacova is a Fellow at the Reconstructive Rearfoot and Ankle Surgical Fellowship within the Ankle and Foot Care Centers

and the Ohio College of Podiatric Medicine.

References

1. Takagi K. The classic arthroscope. *J Jap Orthop Assoc.* 1939; 167:6-8.
2. Stetson WB, Ferkel RD. Ankle arthroscopy II indications and results. *J Am Acad Orthop Surg.* 1996; 4(1):24-34.
3. Barnes CJ, Ferkel RD. Arthroscopic debridement and drilling of osteochondral lesions of the talus. *Foot Ankle Clin N Am.* 2003; 8(2):243-247.
4. Niek van Dijk C, Verhagen RA, Tol JL. Arthroscopy for problems after ankle fracture. *Brit Edit Soc Bone Joint Surg.* 1997; 79-B(2):280-284.
5. Stetson WB, Ferkel RD. Ankle Arthroscopy I. Technique and complications. *J Am Acad Orthop Surg.* 1996; 4(1):17-23.
6. Ferkel RD, Small HN, Gittins JE. Complications in foot and ankle arthroscopy. *Clin Ortho Rel Res.* 2001; 391:89-104.
7. Ferkel RD, Heath DD, Guhl JE. Neurological complications of ankle arthroscopy. *Arthroscopy.* 1996; 12(2):200-208.
8. Tryfonidis M, Whitfield CG, Charalambous CP, Baraza WK, Zubairy AL. Posterior ankle arthroscopy portal safety regarding proximity to the tibial and sural nerve. *Acta Ortop Bel.* 2008; 74(3):370-3.
9. Rodeo SA, Forster RA, Weiland AJ. Neurological complications due to arthroscopy. *J Bone Joint Surg Am.* 1993; 75(6):917-926.
10. Kumar VP, Satku K. The A-O femoral distractor for ankle arthroscopy. *Arthroscopy.* 1994; 10(1):118-9.
11. Guhl JE. New concept (distraction) in ankle arthroscopy. *Arthroscopy.* 1988; 4(3):160-7.
12. Tasto JP. Arthroscopic ankle and subtalar arthrodeses: 14-year prospective study and follow-up. Presented at the American Orthopaedic Foot and Ankle Society 22nd Annual Summer Meeting, July 14-16, 2006, La Jolla, Calif.
13. Kumai T, Takakura Y, Higashiyama I, Tamai S. Arthroscopic drilling for the treatment of osteochondral lesions of the talus. *J Bone Joint Surg Am.* 1999; 81(9):1229-35.
14. Sexton A. Treatment of osteochondral lesions of the talus with arthroscopic drilling and osteochondral autograft transplantation. Presented at the 2003 Annual Meeting of the Georgia Orthopaedic Society, October 9-12, 2003, Sea Island, Georgia.
15. Hyer CF, Berlet GC, Philbin T, Lee TH. Retrograde drilling of osteochondral lesions of the talus. *Foot Ankle Spec.* 2008; 1(4):207-209.
16. Cline S, Wolin P. The use of thermal energy in ankle instability. *Clin Sports Med* 2002; 21(4):713-725.
17. Khan A, Fanton G. Use of thermal energy in treatment of ankle disorders. *Sports Med Arthroscopy Rev.* 2000; 8(4):354-364.
18. Edwards III RB, Lu Y, Markel MD. The basic science of thermally assisted chondroplasty. *Clin Sports Med.* 2002; 21(4):619-647.
19. Lu Y, Edwards III RB, Heiner JP et al. Lavage fluid temperature influences depth of chondrocyte death and surface contouring during thermal chondroplasty with monopolar radiofrequency energy. *Am J Sports Med.* 2002; 30(5):667-673.
20. Lu Y, Edwards III RB, Nho S, et al. Thermal chondroplasty with bipolar and monopolar radiofrequency energy: effect of treatment time on chondrocytes death and surface contouring. *Arthroscopy.* 2002; 18(7):779-788.

Approach patient comfort from every angle.

Get ready for the next generation of a proven solution.

Gebauer's Ethyl Chloride® is a brand physicians have known and trusted for years. And now at Gebauer Company, we are gearing up to introduce an exciting new delivery system for our aerosol stream cans. This innovation will not only give you more precision, it will make it easier to make your patients more comfortable.

For more information, call 1-800-321-9348 or visit www.gebauer.com.

 **Gebauer Company**
The Most Trusted Name In Skin Refrigerants For Over 100 years!®

Cleveland, OH 44128
1-800-321-9348
www.gebauer.com

Spec. 712.1 © 2011 Gebauer Company