

Contents lists available at ScienceDirect

The Journal of Foot & Ankle Surgery

journal homepage: www.jfas.org



Original Research

Early Weight Bearing After Modified Lapidus Arthrodesis: A Multicenter Review of 80 Cases

Neal M. Blitz, DPM, FACFAS¹, Thomas Lee, DPM, FACFAS², Kwamee Williams, DPM³, Howard Barkan, DrPH⁴, Lawrence A. DiDimenico, DPM, FACFAS⁵

¹ Chief of Foot Surgery, Department of Orthopaedic Surgery, Bronx-Lebanon Hospital Center, Albert Einstein College of Medicine, Bronx, NY

² Attending Podiatric Surgeon, Kaiser North Bay Consortium Residency Program, Kaiser Foundation Hospital, Vallejo, CA

³ Fellow, Reconstructive Rearfoot & Ankle Surgical Fellowship, Northside Medical Center, Youngstown, OH

⁴ Biostatistician, Department of Veteran's Affairs, Palo Alto, CA

⁵ Adjunct Professor, Ohio College of Podiatric Medicine, Director, Reconstructive Rearfoot & Ankle Surgical Fellowship, Northside Medical Center, Youngstown, OH

ARTICLE INFO

Level of Clinical Evidence: 2

Keywords:

bunion
early weight-bearing
fusion
hallux valgus
lapidus arthrodesis
lapidus bunionectomy
metatarsocuneiform
nonunion
surgery

ABSTRACT

The modified Lapidus arthrodesis involves fusion of the first tarsometatarsal, which typically takes about 6 weeks to consolidate. Postoperative protocols typically involve non-weight bearing until bone consolidation occurs, however, with a stable fixation construct, protected weight bearing can be initiated earlier than 6 weeks into the postoperative period. Studies specifically evaluating an early weight bearing protocol after lapidus arthrodesis do not exist; such a protocol is the focus of this investigation. A multicenter retrospective review of 80 feet in 76 patients who underwent a Lapidus arthrodesis by 2 different surgeons, involving a similar fixation technique and an early weight-bearing protocol, was performed. All patients were allowed protected weight bearing after the first postoperative visit, at approximately 2 weeks into the postoperative course. Patients began protected weight bearing at a mean 14.8 (95% CI 14.0, 15.6) days postoperative. All 80 feet proceeded to successful union (100% union), and the mean time to union was 44.5 days (95% CI 43.0, 46.0). No hardware was broken, and no complications requiring surgical revision were observed before solid bony fusion was achieved. Statistically significant ($P < .001$) improvements in the first intermetatarsal, hallux abductus, and lateral metatarsal angles were observed; and no cases of pathological first ray elevatus were encountered. The duration of time to bone healing in the cohort described in this article was similar to the rates described in previous reports describing Lapidus arthrodesis managed with a considerably longer duration of initial postoperative non-weight bearing. This study demonstrates that early weight bearing of the Lapidus arthrodesis can be performed without compromising correction or the rate of osseous union. This is the first study that specifically evaluates the early weight bearing protocol after lapidus arthrodesis.

© 2010 by the American College of Foot and Ankle Surgeons. All rights reserved.

Isolated first tarsometatarsal (TMT) arthrodesis (modified Lapidus arthrodesis) is an accepted method of correcting varying degrees of hallux valgus with or without associated first ray insufficiency (1–18). The Lapidus arthrodesis was introduced as a procedure in the 1930s. It was initially criticized by most surgeons because of the high nonunion rate, which is now thought to have been a consequence of poor fixation techniques (1). The introduction of screw fixation led to more reliable outcomes and a lower incidence of nonunion (3, 4), and the Lapidus arthrodesis has come into wider use. However, the nonunion

stigma remains, and surgeons typically follow a cautious postoperative regimen, including a strict non-weight-bearing protocol lasting for approximately 6 weeks, until bone consolidation occurs.

It is reasonable to consider that early weight bearing after the Lapidus procedure may result in loss of fusion site stability or fixation failure, either of which may lead to nonunion. However, there is no scientific evidence specifically linking early weight bearing after the Lapidus procedure with screw fixation to nonunion of the first TMT. The limited retrospective studies of similar procedures that have used an early weight-bearing postoperative protocol (3, 10, 12, 15, 18) have demonstrated fusion rates similar to, if not better than, studies using non-weight-bearing protocols (2, 9, 11, 13, 19).

The purpose of this retrospective cohort study was to assess outcomes in patients who had undergone modified Lapidus arthrodesis whose postoperative management included early weight bearing. Herein we report the results of a multicenter review of 80

Financial Disclosure: None reported.

Conflict of Interest: None reported.

Address correspondence to: Neal M. Blitz, DPM, FACFAS, Chief of Foot Surgery, Department of Orthopaedic Surgery, Bronx-Lebanon Hospital Center, 1650 Grand Concourse, 7th Floor, Bronx, NY 10457.

E-mail address: nealblitz@yahoo.com (N.M. Blitz).

feet in 76 patients who underwent first TMT arthrodesis and began weight bearing 2 weeks after the index operation.

Patients and Methods

Medical databases, charts, and radiographs of the senior authors (N.M.B. and L.A.D.) were reviewed for all patients who had undergone a modified Lapidus arthrodesis performed from October 2002 to March 2007. To be included in the cohort required having undergone Lapidus arthrodesis with or without other procedures of the first ray (ie, muscle-tendon procedures, distal metatarsal osteotomy, Akin procedure). Patients who underwent Lapidus arthrodesis in conjunction with other procedures that did not focus on the first pedal ray, with the exception of harvesting autogenous ipsilateral calcaneal bone graft, were excluded. The following data were collected: age, sex, smoking history, the date postoperative weight-bearing protocol began, and time to radiographic union. In addition, preoperative and postoperative radiographic measurements from weight-bearing films were recorded for the following radiographic angles: first intermetatarsal angle (IMA), lateral metatarsal angle (LMA) (measured from ground to first ray on the weight bearing lateral view of the foot), and hallux valgus angle (HVA). The HVA was obtained using the Hardy and Clapham technique (20). Radiographic measurements were made by the authors either with plain-film radiographs using tractographs, or a digital imaging system (Stentor iSite Picture Archive and Communications System [PACS], Philips Healthcare, Amsterdam, The Netherlands) with company-provided measuring tools. A single measurement was taken for each radiographic variable. Successful radiographic fusion was determined using criteria that we modified from previously published work pertaining to the Lapidus arthrodesis (21), and entailed trabeculation across the joint space with no evidence of sclerosis, no broken or loose hardware and/or widening, and absence of pain at the fusion site, as determined by the surgeon assessor.

Surgical Procedure

All patients underwent a modified first TMT arthrodesis using variations of the crossed screw technique described by Hansen (22). The technique involved placing 2 to 3 fully threaded screws across the fusion site. There were no bilateral Lapidus procedures performed at the same time. General anesthesia and a thigh tourniquet were used in all cases. The specific variations of this technique used by the senior authors (N.M.B. and L.A.D.) are described below.

N.M.B. Technique

A curvilinear incision was created dorsomedially over the first ray and the proximal portion was angulated medial to the medial dorsal cutaneous nerve. An L-shaped or linear first metatarsophalangeal joint (MTPJ) capsulotomy was performed. Resection of the medial eminence and an adductor release was performed in all cases. The first metatarsocuneiform joint (MCJ) was accessed with a linear capsulotomy, with care taken to avoid disruption of the dorsal second metatarsal medial cuneiform ligament. Joint preparation involved resection and curettage using osteotomes and curettes. A lamina spreader was used to access the plantar aspect of the joint. The subchondral plate was perforated with a bone pick and/or a 0.045-inch Kirschner wire until bleeding bone was identified. In all cases, the first ray was translated inferiorly to accommodate for shortening of the weight-bearing segment. The first IMA was reduced to the corrected alignment, and manually stabilized until the first screw was placed. At least two 3.5-mm cortical stainless steel screws were placed across the arthrodesis. The first screw placed was a lag screw with a general orientation of the screw's long axis almost perpendicular to the fusion site to increase the screw's compressive force. That screw was inserted from distal to proximal. The second screw was placed from the

dorsolateral aspect of the medial cuneiform into the first metatarsal base, and typically without lag technique. In cases where a third 3.5-mm screw was used, it was placed from the medial aspect of the base of the first metatarsal into the intermediate cuneiform or second metatarsal base. Indications for third screw placement were determined by the surgeon, with the primary goal of providing an additional point of fixation. Third screw placement did not indicate that the 2 existing screws were insufficient, because multiple points of fixation are generally considered more stable. A stress-relieving bone graft was placed on the dorsum of the joint; this bone was obtained (via rongeur) from locally derived bone at the fusion site.

L.A.D. Technique

A straight incision measuring 3 to 4 cm was placed at the dorsomedial aspect of the first MCJ. In most cases no procedures were performed on the first metatarsal head. However, resection of bony prominences was performed when the joint was arthritic and displayed radiographic evidence of osteophytosis. The first MCJ was accessed with a linear capsulotomy. Joint preparation consisted of reciprocal planing with a sagittal saw, performed to plantarflex the first ray and to accommodate shortening associated with joint resection. A lamina spreader was used to access the plantar aspect of the joint. The subchondral plate was perforated with drill bits until bleeding bone was identified. Debridement of the medial base of the second metatarsal was also performed. The first ray was then held in a corrected position indicative of reduction of the first IMA, using Steinman pins before screw insertion. Three 4.0-mm solid cortical stainless steel screws were then placed across the arthrodesis. The first 2 screws were positioned in the same orientation as described in the N.M.B. technique, although the second screw from the medial cuneiform into the first metatarsal base was placed in a lag fashion. A third screw (nonlag) was inserted from the base of the first metatarsal to the base of the second metatarsal. A stress-relieving bone graft was also placed on the dorsum of the joint, and this bone was obtained from the calcaneus via an ancillary incision made on the lateral aspect of the calcaneus, through which a curette was used to harvest cancellous bone.

Postoperative Protocol

The postoperative protocol was identical for both centers, and involved a period of non-weight bearing in a Jones splint or short leg removable immobilizing brace (tall "cam" walker) until the first postoperative visit, approximately 2 to 3 weeks after the index operation, coinciding with soft tissue healing and suture removal. All patients were placed into a removable tall "cam" walker, allowing a progression to full weight bearing as tolerated on the operative leg with the assistance of crutches, at least by the time of the first postoperative visit. Weight bearing was allowed to occur as tolerated by each individual patient after the second postoperative week and, in general, all patients were full weight bearing by the time of their 6-week follow-up visit. We did not measure or keep any record of the actual amount of weight applied to the operated foot during the postoperative period.

Statistical methods

We calculated standard descriptive statistics with 95% confidence intervals (CIs) for all measures using Fisher's exact test, Student *t* test, and the Wilcoxon signed ranks test to compare individual measures between surgeons, and for determining intersurgeon differences. We used the Wilcoxon matched pair signed-rank test to compare associated preoperative and postoperative measurements both within each surgeon's patients and overall. Statistical analyses were performed by the fourth author (statistician) and conducted using PASW Statistics 18 (SPSS, an IBM Company, Chicago, IL) (release July 30, 2009).

Table 1
Statistical description of the overall results (N = 80 feet in 76 patients)

Variable	Point Estimate with 95% CI (Mean Average for Continuous Data, Count (%) for Categorical Data)	P value* for Overall Preoperative to Postoperative Comparison
Age (years)	53.4 (49.9, 56.8)	
Male sex	11 (13.8) (7.1, 23.3) N/A	N/A
Preop HVA (°)	20.98 (18.40, 23.55)	
Postop HVA (°)	9.13 (7.64, 10.61)	.001
Preop IMA (°)	13.18 (12.42, 13.93)	
Postop IMA (°)	6.60 (5.99, 7.21)	< .001
Preop LMA (°)	21.45 (20.72, 22.18)	
Postop LMA (°)	25.79 (24.85, 26.73)	< .001
Days to partial weight bearing	14.8 (14.01, 15.56)	
Days to radiographic bone union	44.5 (43.0, 46.0)	N/A
Successful radiographic/clinical union	80 (100) (95.49, 100.00)	

Abbreviations: CI, confidence interval; N/A, test not applicable; HVA, hallux valgus angle; IMA, intermetatarsal angle; LMA, lateral metatarsal angle.

* Students *t* test for continuous numeric data.

Table 2
Comparison of independent and outcome variables by surgeon (N = 80 feet in 76 patients)

Variable	N.M.B. (n = 20 feet in 18 patients)	L.A.D. (n = 60 feet in 58 patients)	P value*
Age, mean (95% CI)	59.1 (53.07, 65.13)	51.43 (47.31, 55.56)	.027
Male sex, count (%)	1 (5.0) (0.13, 24.87)	10 (16.7) (8.29, 28.52)	.28 **
Preop HVA (°), mean (95% CI)	27.40 (23.65, 31.15)	18.83 (15.78, 21.89)	< .001
Postop HVA (°), mean (95% CI)	7.40 (5.06, 9.74)	9.70 (7.87, 11.53)	.312
Preop IMA (°), mean (95% CI)	14.50 (12.64, 16.36)	12.73 (11.94, 13.53)	.033
Postop IMA (°), mean (95% CI)	4.65 (3.76, 5.54)	7.25 (6.55, 7.95)	< .001
Preop LMA (°), mean (95% CI)	18.80 (17.45, 20.15)	22.33 (21.57, 23.10)	< .001
Postop LMA (°), mean (95% CI)	20.60 (29.19, 22.01)	27.52 (26.75, 28.29)	< .001
Days to PWB, mean (95% CI)	13.7 (12.2, 15.3)	15.1 (14.2, 16.0)	.039
Days to union, mean (95% CI)	45.9 (42.5, 49.3)	44.1 (42.3, 45.8)	.30
Union, count (%)	20 (100)	60 (100)	1.0 [†]

Abbreviations: N.M.B., Neal M. Blitz; L.A.D., Lawrence A. DiDimenico; CI, confidence interval; HVA, hallux valgus angle; IMA, intermetatarsal angle; LMA, lateral metatarsal angle; PWB, partial weight bearing.

* Wilcoxon signed ranks (Mann Whitney U) test.

† Fisher's exact test.

Results

Tables 1 to 3 depict the statistical results of the cohort study. Eighty feet in 76 patients met the inclusion criteria and were included in the analyses. Their mean age was 53.4 (49.9, 56.8) years, and there were 11 (13.8%) males in the cohort. Patients began protected weight bearing at a mean 14.8 (95% CI 14.0, 15.6) days postoperative. All 80 feet proceeded to successful union (100% union), and the mean time to union was 44.5 days (95% CI 43.0, 46.0).

For surgeon N.M.B., 20 feet in 8 patients were included. Two-screw fixation was used in 11 (55%) cases, 3-screw fixation was used in 8 (40%) cases, and 4-screw fixation was used in 1 (5%) case. There were 13 right feet and 7 left feet, among 19 females and 1 male. The average age for this cohort was 59 (range 19–82) years. There were no active smokers in this cohort. For surgeon L.A.D., there were 58 patients (60 feet). There were 32 right feet and 28 left feet. The average age of the cohort was 51.3 (CI 47.3, 55.6) years. There were 50 female and 10 male patients. There were 9 smokers in this cohort. Patients of N.M.B. required an average of 45.9 (CI 42.8, 49.0) days to reach union, whereas the patients of L.A.D. required an average of 44.1 (CI 42.4, 45.7) days.

Graphing the proportion achieving union against the time (days) postoperative is demonstrated in Figure 1.

Discussion

Weight-bearing protocols after Lapidus arthrodesis vary from strict non-weight bearing, immediate weight bearing, partial weight bearing, and a hybrid of initial non-weight bearing with progression of weight bearing (2, 3, 5, 18, 19). In general, however, surgeons who initiate weight bearing before bony consolidation (approximately 6–8 weeks after the operation) are considered to be following an early weight-bearing protocol. A standard protocol on postoperative weight

bearing after a Lapidus arthrodesis does not exist, nor do guidelines indicating when an early weight-bearing program is warranted.

Despite the lack of rigorous guidelines, early weight bearing after first TMT arthrodesis is not an entirely new concept. In Lapidus' landmark paper (1934), the first TMT fusion was fixated with heavy catgut suture and weight bearing began almost immediately following the surgery in a special shoe fabricated with a medial metal plate. Patients were able to ambulate on "their heels on the second or third postoperative day" and "few patients required crutches for the first week or two" (1). Lapidus did not publish any objective results in any of his publications and his union rate has not been reported. However, he noted that fusion could take up to 3 months and dorsal drift of the first ray was a possibility. He wrote the following regarding patient selection: "we limit our surgical correction to selected cases in which functional and cosmetic consideration seem to warrant it" (1). Proponents of internal fixation have suggested that nonunion and first metatarsal elevation is due to weak suture fixation and immediate postoperative weight bearing (3, 14, 16, 23). Rutherford (1974) (4) introduced single-screw fixation, oriented from the medial portion of the base of the first metatarsal into the intermediate cuneiform. He also protected patients for 6 weeks in a short leg cast, although there was no mention of how many patients he treated and or the type of cast used. Sangeorzan and Hansen (1989) (3) introduced AO (Arbeitsgemeinschaft für Osteosynthesefragen [AO Foundation, Davos, Switzerland]) principles to first TMT arthrodesis and used 2 crossed screw fixation along with early postoperative mobilization, starting with "toe touch weight bearing" for the first 2 weeks in a cast, followed by weight of leg ambulation in a short leg cast.

Until recently, only 4 retrospective reviews had been published regarding early weight-bearing protocols (Table 4), and all were level 4 (case reports or series) studies. In 2009, Saxena et al (18) performed a level 2 (cohort) study with an early weight-bearing protocol initiated at 4 weeks. Moreover, most investigations involving the Lapidus arthrodesis focused on outcomes associated with non-weight-

Table 3
Statistical comparisons of preoperative and postoperative radiographic outcomes by surgeon (N = 80 feet in 76 patients)

Variable	Surgeon	Preoperative, mean (95% CI)	Postoperative, mean (95% CI)	P value*
Hallux valgus angle (°)	N.M.B. (n = 20 feet)	27.40 (23.65, 31.15)	7.40 (5.06, 9.74)	.001
	L.A.D. (n = 60 feet)	18.83 (15.78, 21.89)	9.70 (7.87, 11.53)	.001
First intermetatarsal angle (°)	N.M.B. (n = 20 feet)	14.50 (12.64, 16.36)	4.65 (3.76, 5.54)	.001
	L.A.D. (n = 60 feet)	12.73 (11.94, 13.53)	7.25 (6.55, 7.95)	.001
Lateral metatarsal angle (°)	N.M.B. (n = 20 feet)	18.80 (17.45, 20.15)	20.60 (29.19, 22.01)	.001
	L.A.D. (n = 60 feet)	22.33 (21.57, 23.10)	27.52 (26.75, 28.29)	.001

Abbreviations: N.M.B., Neal M. Blitz; L.A.D., Lawrence A. DiDimenico; CI, confidence interval.

* Wilcoxon signed ranks (Mann Whitney U) test.

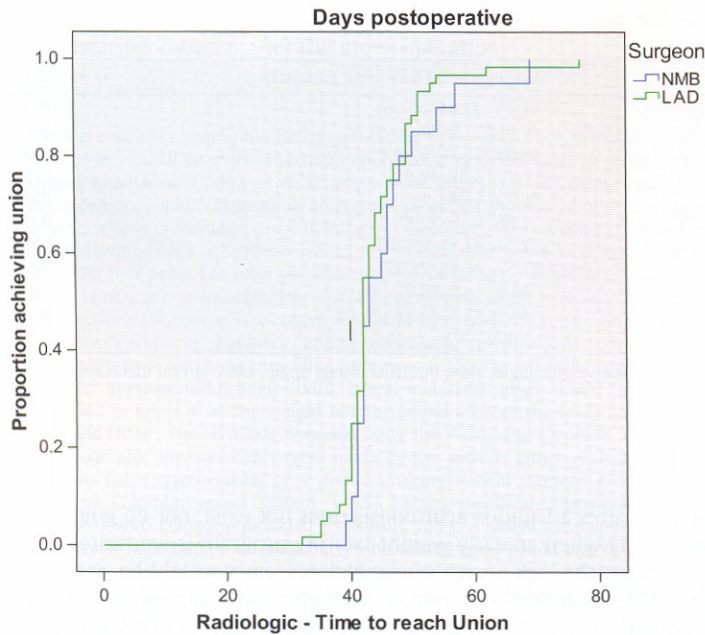


Fig. 1. Time postoperative to union*
 *The difference between these curves is not statistically significant (Breslow, generalized Wilcoxon *P* value = .31).

bearing protocols (1-3, 5-7, 9-12, 23-26). Because nonunion has been a traditional concern (early reports ~25%), it seems that most surgeons followed more cautious non-weight-bearing protocols (3, 10, 23, 26, 27). Evolution and experience with the procedure/technique along with more refined patient selection have resulted in lower nonunion rates of approximately 1.8% to 10.0%, with more recent literature representing studies with sample sizes from 42 to 227 feet (5, 11, 28-31). The largest retrospective study by Patel and colleagues (21) demonstrated a 5.3% nonunion rate with a modified Lapidus arthrodesis in a consecutive case series of 227 feet managed with a non-weight-bearing protocol. Additionally, asymptomatic radiographic nonunions appear to be intermixed within a majority of the aforementioned studies, suggesting that symptomatic nonunions requiring revision likely account for the lower percentage of reported nonunions. Furthermore, technique and fixation methods also vary, as do weight-bearing protocols, making it difficult to determine what factors are responsible for a successful result.

In general, fixation type, fixation technique and orientation, joint preparation, weight-bearing protocols, and medical comorbidities have been suggested as factors that may influence outcomes and complications, particularly nonunion (5, 25, 32). Several internal fixation devices and techniques have been used for first TMT arthrodesis. These include solid bore screws (cortical and/or cancellous), cannulated screws, and/or various types of plate fixation. Fixation type depends on surgeon preference and experience, and possibly regional influences. Regardless, a stable construct is required for a solid arthrodesis. Advocates of AO principles require at least 2 screws, one screw for compression and the other to resist rotation. A plate requires at least 2 points of fixation both proximal and distal to the first TMT fusion. Locking plates have been more popular in recent years. The optimal fixation technique and fixation type for first TMT fusion has yet to be determined. Chang and Ruch (33) compared plate fixation to screw fixation for first TMT fusion in polyurethane bone models. A medially placed one-third tubular plate (5 holes, concentrically drilled) combined with a compressive 4.0-mm screw across the fusion site provided a higher sagittal force to failure than 2 crossed 4.0-mm screws. However, a cadaveric study performed by Cohen et al (34) compared a dorsal locking H-plate to that of crossed 4.0-mm cannulated screws for simulated first TMT fusion. The latter fixation type had a higher mean maximal load to failure and higher mean stiffness. In our present study, no fixation failures occurred with crossed solid bore screws and a 100% union rate was achieved in an early weight-bearing program, suggesting that the screws and construct may play a role in resisting the tensile forces on the fusion. Of the 5 retrospective studies that initiate an early weight-bearing protocol, 3 of these studies use the crossed screw technique advocated by Hansen (3, 12, 15). Saxena et al used a locking plate and a single plantar screw (18). Despite these published reports, we feel that broader and larger cadaveric and clinical studies are needed to better understand the fixation needs of a first TMT fusion, especially as one considers weight-bearing protocols.

Our retrospective study further demonstrates that successful first TMT union may be achieved with an early weight-bearing program after Lapidus arthrodesis. The protocol we followed involved a period of non-weight bearing for approximately 2 weeks, mean estimate of 14.8 (CI 14.01, 15.56) days, followed by protected weight bearing as tolerated in a "cam" walker until bony consolidation occurred. The degree of weight bearing (force applied to the fusion) was determined by the patient's comfort level. Although patients were allowed full weight bearing, it is likely that they may have been partially weight bearing until pain subsided. We did not identify any nonunions, and the mean time to union was 44.5 (CI 43.0, 46.0) days. Patients of

Table 4
 Summary of early weight-bearing protocols, union rates and nonunion revisions, from earliest weight-bearing protocol to latest

Investigator(s) (reference citation)	Year	Patients, feet	Fixation	Postoperative weight-bearing protocol	Union rate, %	Nonunion revision, count (%)
Blitz & DiDimenico et al	2010	80, 76	2 or 3 crossed screws	NWB Jones splint or removable tall "cam" walker × 2-3 wk, then WBAT in removable tall "cam" walker × 4 wk	100%	N/A
Sangeorzan and Hanson (3)	1989	32, 40	2 crossed screws	TTWB SLC × 2 wk, then WOL in SLC until radiographic fusion	92%	3 (3.1)
Bednarz and Manoli (12)	2000	26, 31	2 crossed screws	NWB SLC × 2wk, then protected WBAT SLC × 2-6 wk	100%	N/A
Clark et al (15)	1987	20, 32	2 crossed screws	NWB SLC, then TTWB × 2 wk, then 4 wk WBAT	100%	N/A
Saxena et al (18)	2009	19, 19	Locking plate and plantar screw	NWB SLC or immobilizing boot × ~ 4 wk, then WBAT in SLC × 4-6 wk until radiographic fusion	100%	N/A
Myerson et al (10)	1992	53, 67	2 screws (first metatarsal to medial cuneiform & first metatarsal to second metatarsal base)	Protocol 1, 21 feet: NWB SLC until comfortable, then WBAT SLC for 8 wk Protocol 2, 46 feet: BS WBAT ± crutches for 6-8 wk	89%	1 (1.5)

Abbreviations: TTWB, toe touch weight bearing; WOL, weight of leg; NWB, non-weight bearing; WBAT, weight bearing as tolerated; SLC, short leg cast; BS, bunion shoe.

N.M.B. required a mean of 45.9 (CI 42.8, 49.0) days to reach union, as compared with a mean of 44.1 (CI 42.4, 45.7) days for patients of L.A.D., and this difference was not statistically significant. Graphing the proportion achieving union against the time (days) postoperative is depicted in Figure 1. We reported a 100% union rate in the 80 feet included in this review.

Although the primary purpose of this investigation was to study the effect of an early weight-bearing program on union rates after first TMT fusion, there were several differences in the technical aspects of the first TMT fusion between surgeons that are worth reviewing. These include joint preparation technique (curettage versus planar resection using a sagittal saw), autologous bone graft augmentation of the fusion site (locally derived versus trephine calcaneal), and the use of a third screw directed into the lesser tarsus. Overall, it seems that these variables did not statistically significantly affect the rate of union (100% in each group) or the number of days required to achieve union ($P = .3$).

Despite the aforementioned similarities, addition of the third screw directed into the lesser tarsus may be important when initiating an early weight-bearing protocol. The theoretical benefit of this additional screw is that it may further resist the tensile forces associated with weight bearing. A supporting cadaveric study by Ray et al (25) demonstrated that the addition of a third screw increased the load to failure and bending moments, although the amount of increase in comparison with a 2-screw technique was not statistically significant. In fact, 69 (86.25%) of feet described in this study were fixated with the third screw (3-screw Lapidus). Although we are not able to say with certainty that the use of 3 screws provides superior stabilization compared with the use of 2 screws across the first TMT, we feel that we can safely state that successful fusion was achieved with 2- or 3-screw fixation combined with early postoperative weight bearing. Clinically, we theorize that the third screw probably provides additional stabilization of the construct, which is likely to resist loads related to early postoperative weight bearing; however, the degree of additional resistance may not be clinically any better in comparison with the 2-screw fixation technique.

In all cases, autogenous bone graft was used to augment the first TMT fusion, derived from either local bone (ie, exostectomy of the first TMT) or trephine calcaneal bone graft. The use of stress-relieving bone graft at the fusion site may increase the likelihood of successful fusion (22, 35). Because all patients in this series had some form of local bone grafting, we cannot make any claims as to whether or not the bone grafting aided the union rate, and or time to union. Similarly, we cannot make any claims or comparisons that use of calcaneal bone graft (theoretic osteogenic potential) provided any benefits over that of local shift of bone graft, in regard to time to fusion, although we did achieve a 100% union rate in these 80 cases, and the use of this bone graft may have played a beneficial role.

The presence or absence of the subchondral plate has been previously considered to be a factor that affects stability of the fusion, and in turn the rate of fusion (25). Preservation of the subchondral plate has been shown to “significantly enhance the stability of the arthrodesis” and “limit dorsal migration of the screw shaft within the fusion site, preventing earlier failure at lower axial loads” in a cadaveric model (25). Unfortunately, there are no published clinical studies that specifically compare union rates to the presence (curettage method) or absence (saw joint resection) of the subchondral plate in regard to the Lapidus arthrodesis. When the subchondral plate is resected with a saw, heat is generated, which may result in osteonecrosis and may contribute to nonunion, although recent cadaveric investigation into this question seems to indicate that thermal necrosis is not likely to occur (36). In our study, because the same early weight-bearing protocol and similar fixation techniques were used, the main difference between the techniques of the 2 surgeons

was joint preparation and the presence (curettage) or absence (resection using a saw) of the subchondral plate, and this difference in technique did not appear to alter the rate of union, nor the time required to achieve union. Unfortunately, a clear association cannot be made as to whether or not joint preparation technique had an effect on fusion rates on the basis of this retrospective study.

Guidelines do not exist that direct a surgeon as to which patients should or should not undergo an early postoperative weight-bearing program. Of course, the indications for first TMT arthrodesis remain unchanged and are not affected based on the postoperative weight-bearing protocol. It seems logical that patients who are at increased risk for nonunion, such as those with concomitant medical comorbidities, should not participate in an early weight-bearing program. These include patients with osteoporotic bone, peripheral neuropathy, and/or obesity. Rarefaction of the bones with osteoporosis reduces the ability of internal fixation to gain adequate osseous purchase and potentially maintain stability with weight bearing. Patients with peripheral neuropathy may also be more likely to develop a nonunion owing to fixation failure secondary to excessive forces placed across the fusion site. Similarly, obese patients may break down the fusion site because of sheer weight, or perhaps hardware failure. Nonetheless, patient selection is critical when considering an early weight-bearing protocol. Unfortunately, we did not take weight or body mass into consideration in this investigation. Interestingly, 9 (11.25%) of the cases in the cohort involved patients who were active cigarette smokers, and none of these cases displayed a delay in or failure to heal, even though smoking is generally considered to be a risk factor for delayed bone healing.

Like most observational investigations, several limitations influenced this study, not the least of which is an inability to define the causal pathway that leads to successful fusion following Lapidus fusion. We excluded patients who had concomitant procedures done to the other parts of the foot, with the exception of autogenous bone graft harvest from the calcaneus for use at the Lapidus fusion site, limiting our cohort to first ray (Lapidus along with any other first ray procedure) procedures only. This was done in an effort to limit the presence of extraneous variables that could have contributed to patients electing to avoid placing weight on their operative foot. It is possible that expanding the inclusion criteria beyond the first ray to include other procedures that theoretically should not interfere with a patient's ability to ambulate (such as concomitant digital procedures), would have increased the potential number of patients we reviewed, but we believe that these may have affected a patient's ability to begin bearing weight. Nearly one third (35.6%) of the 225 patients undergoing Lapidus during the window of time for which we reviewed records fulfilled these criteria and were included in the sample, and we considered this to be a reasonable proportion of all Lapidus procedures.

Another limitation to this study is that our end point for data collection was the presence of a successful fusion (or nonunion) based on our criteria. However, we did not identify patients who developed delayed union or nonunion in the usual course of their treatment and follow-up. Clearly, patients with bone-healing complication would have been identified in the course of data collection. A prospective designed study to follow patients at a predetermined time after the index operation may be useful. Therefore, the absolute minimal amount of follow-up in this study is equal to the time to radiographic/clinical fusion.

An area of further investigation not evaluated in this study would be the effects of medical comorbidities, such as diabetes, peripheral neuropathy, and/or obesity, on union rates and time to union. Because this study involved early weight bearing, a patient's weight may be directly responsible for potential failure and/or delayed healing as a result of increased force. This could be evaluated by obtaining the body mass index, which was not reviewed in this study, and remains

a clear limitation. In addition, there was no quantified measurement of how much weight the patients were able to bear when they were allowed weight bearing after their postoperative visit. It is speculated that some patients were not able to do so even when given permission, because of pain issues, whereas others actively bore weight even before the first postoperative visit. Future investigations could develop a questionnaire to determine the amount of weight bearing and exact time to weight bearing to improve the validity of the results, and determine more exact time frames to weight bearing. Furthermore, we did not undertake a sensitivity analysis that may have shed some light on the resistance of our findings to unmeasured clinical variables.

Last, with regard to study limitations, radiographic and clinical chart assessments were performed by junior authors for each respective surgeon, introducing a potential for intraobserver bias in the way that the data were interpreted, and regarding the values of the preoperative and postoperative measured angles. It is possible that there may be slight differences in the measured radiographic angles between surgeons, as patients operated on by N.M.B. had radiographic angular measurements performed digitally and patients operated on by L.A.D. had radiographic angular measurements performed manually. We have no reason to believe this difference influenced our angular measurements and/or comparisons. Only one value for each radiographic measurement was obtained, whereas taking multiple values and calculating the average value may have identified small manual errors in a particular radiograph variable. Despite these theoretical limitations, we feel that the methods we used are common in the surgical realm and, as such, make our findings generalizable.

In conclusion, successful fusion rates may be achieved with early weight bearing following the modified Lapidus arthrodesis. We demonstrated a union rate of 100% in patients who were permitted to bear weight in a removable walking boot as early as 2 weeks postoperative with proper patient selection, and we provide some guidelines for an early weight-bearing program with the Lapidus arthrodesis. It is our hope that our results will spark further research, especially randomized controlled comparative studies between non-weight bearing and early weight bearing following Lapidus arthrodesis.

References

- Lapidus P. The author's bunion operation from 1931 to 1959. *Clin Orthop* 16:119–135, 1960.
- Kopp FJ, Patel MM, Levine DS, Deland JT. The modified Lapidus procedure for hallux valgus: a clinical and radiographic analysis. *Foot Ankle Int* 26(11):913–917, 2005.
- Sangeorzan B, Hansen S. Modified Lapidus procedure for hallux valgus. *Foot Ankle* 9(6):262–266, 1989.
- Rutherford R. The Lapidus procedure for primus metatarsus adductus. *J Am Podiatry Assoc* 64(8):581–584, 1974.
- McInnes B, Bouche R. Critical evaluation of the modified Lapidus procedure. *J Foot Ankle Surg* 40(2):71–90, 2001.
- Bacardi B, Boysen T. Considerations for the Lapidus operation. *J Foot Surg* 25(2):133–138, 1986.
- Coetzee C, Resig S, Kuskowski M, Saleh K. The Lapidus procedure as salvage after failed surgical treatment of hallux valgus. *J Bone Joint Surg Am* 86-A(Suppl 1):30–36, 2004.
- Saffo G, Wooster M, Desnoyers R, Catanzariti A, Stevens M. First metatarsocuneiform joint arthrodesis: a five year retrospective analysis. *J Foot Surg* 28(5):459–465, 1989.
- Hernandez A, Hernandez P, Hernandez W. Lapidus: when and why? *Clin Podiatr Med Surg* 6(1):197–208, 1989.
- Myerson M, Allon S, McGarvey W. Metatarsocuneiform arthrodesis for management of hallux valgus and metatarsus primus varus. *Foot Ankle* 13(3):107–115, 1992.
- Catanzariti A, Mendicino R, Lee M, Gallina M. The modified Lapidus arthrodesis: a retrospective analysis. *J Foot Ankle Surg* 38(5):322–332, 1999.
- Bednarz PA, Manoli A 2nd. Modified Lapidus procedure for the treatment of hypermobile hallux valgus. *Foot Ankle Int* 21(10):816–821, 2000.
- Myerson MS, Badekas A. Hypermobility of the first ray. *Foot Ankle Clin* 5(3):469–484, 2000.
- Christenson C, Jones RO, Basque M, Mollohan E. Comparison of oblique closing base wedge osteotomies of the first metatarsal: stripping versus nonstripping of the periosteum. *J Foot Surg* 30(2):107–113, 1991.
- Clark HR, Veith RG, Hansen ST Jr. Adolescent bunions treated by the modified Lapidus procedure. *Bull Hosp Jt Dis Orthop Inst* 47(2):109–122, 1987.
- Hansen ST. Hallux valgus surgery. Morton and Lapidus were right!. *Clin Podiatr Med Surg* 13(3):347–354, 1996.
- Mendicino R, Catanzariti AR, Hofbauer M, Saltrick KR. The modified Lapidus arthrodesis: technical maneuvers and pearls. *J Foot Ankle Surg* 39(4):258–264, 2000.
- Saxena A, Nguyen A, Nelsen E. Lapidus bunionectomy: early evaluation of crossed lag screws versus locking plate with plantar lag screw. *J Foot Ankle Surg* 48(2):170–179, 2009.
- Ray RG. First metatarsocuneiform arthrodesis: technical considerations and technique modification. *J Foot Ankle Surg* 41(4):260–272, 2002.
- Hardy RH, Clapham JC. Observations on hallux valgus; based on a controlled series. *J Bone Joint Surg Br* 33:376–391, 1951.
- Patel S, Ford L, Etcheverry J, Rush S, Hamilton G. Modified Lapidus arthrodesis: rate of nonunion in 227 cases. *J Foot Ankle Surg* 43(1):37–42, 2004.
- Hansen ST. First tarsometatarsal joint arthrodesis. In *Functional Reconstruction of the Foot and Ankle*, pp 335–340, edited by ST Hansen, Lippincott Williams & Wilkins, Philadelphia, 2000.
- Bednarz PA, Manoli A 2nd. Modified Lapidus procedure for the treatment of hypermobile hallux valgus. *Foot Ankle Int* 21(10):816–821, 2000.
- Hofbauer MH, Grossman JP. The Lapidus procedure. *Clin Podiatr Med Surg* 13(3):485–496, 1996.
- Ray R, Ching R, Christensen J, Hansen S. Biomechanical analysis of the first metatarsocuneiform arthrodesis. *J Foot Ankle Surg* 37(5):376–385, 1998.
- Mauldin DM, Sanders M, Whitmer WW. Correction of hallux valgus with metatarsocuneiform stabilization. *Foot Ankle* 11:59–66, 1990.
- Coetzee JC. The Lapidus procedure for correction of moderate and severe metatarsus primus varus and hallux valgus deformities. In *Advanced Reconstruction – Foot and Ankle*, 1st ed, pp. 35–39, edited by J Nunley, American Academy of Orthopedic Surgeons, Rosemont, IL, 2004.
- Myerson M. Metatarsocuneiform arthrodesis for treatment of hallux valgus and metatarsus primus varus. *Orthopedics* 13:1025–1031, 1990.
- Mauldin DM, Sanders M, Whitmer WW. Correction of hallux valgus with metatarsocuneiform stabilization. *Foot Ankle* 11:59–66, 1990.
- Coetzee JC, Wickum D. The Lapidus procedure: a prospective cohort outcome study. *Foot Ankle Int* 25(8):526–531, 2004.
- Rink-Brune O. Lapidus arthrodesis for management of hallux valgus—a retrospective review of 106 cases. *J Foot Ankle Surg* 43(5):290–295, 2004.
- Hamilton GA, Mullins S, Schuberth JM, Rush SM, Ford L. Revision Lapidus arthrodesis: rate of union in 17 cases. *J Foot Ankle Surg* 46(6):447–450, 2007.
- Chang TJ, Ruch JA. Lapidus arthrodesis. A different perspective. *J Am Podiatr Med Assoc* 84(6):281–288, 1994.
- Cohen D, Parks B, Schon L. Screw fixation compared to H-locking plate fixation for first metatarsocuneiform arthrodesis: a biomechanical study. *Foot Ankle Int* 26(11):984–989, 2005.
- Perren SM. Physical and biological aspects of fracture healing with special reference to internal fixation. *Clin Orthop Relat Res* 138:175–196, 1979.
- Hall PB, Landsman A, Banks AS, Dalmia L. Thermal properties of first metatarsal osteotomies. *J Foot Ankle Surg* 48:432–438, 2009.