

# Fixation Techniques in Foot and Ankle Surgery

Lawrence A. DiDomenico, D.P.M., F.A.C.F.A.S.  
Dave Garchar, D.P.M.

## INTRODUCTION

The following chapter will discuss the basic principles of internal fixation and their use in forefoot, rearfoot, and ankle surgery. The first section will introduce how AO was developed and discuss the four principles that improve the results of fracture treatment while utilizing internal fixation. It will also describe the various types of fixation utilized and the principles behind their application. The next section of this chapter will describe how to apply these principles. This section is based on the authors' experience utilizing basic AO principles and fixation. These techniques have proven to be successful when performed correctly.

## HISTORY OF AO

Robert Danis, early in the 1950s, pioneered the work on internal fixation and his theory of primary bone healing.<sup>1</sup> In 1958, Maurice E. Müller, inspired by the work of Danis, assembled a group of friends, consisting of both general and orthopedic surgeons, to form a study group. This group was set up under the name Arbeitsgemeinschaft für Osteosynthesefragen (AO), which later became known in English-

speaking countries as the Association for the Study of Internal Fixation (ASIF). In 1963, Müller, Allgöwer, and Wille-negger published the first report on operative treatment of fractures, which stressed the advantages of early open reduction and internal fixation.<sup>2</sup> However, much of what was first published was lost when translated from German to English. Therefore, in 1969 the Swiss AO group published the first edition of the *Manual of Internal Fixation*,<sup>3</sup> which discussed and demonstrated in detail the various operative fixation methods for fractures, osteotomies, and arthrodeses. A second and third edition have since been published and reprinted many times.

## AO BASIC PRINCIPLES

In 1958, the AO group developed four treatment principles with the purpose of improving the results of fracture treatment while utilizing internal fixation.<sup>3</sup> The first principle, *accurate anatomical reduction*, is important in restoring full function to all joint fractures as well as re-establishing proper length, rotation, and axes of both the metaphysis and diaphysis. Similar considerations apply to the second principle, *rigid internal compression fixation*. This principle

must be adhered to in order to provide adequate stability to maintain length, rotation, and axes. This form of fixation is required for absolute stability, which allows primary bone healing to occur. The third principle, *atraumatic surgical technique*, is important to preserve the vascular supply needed to heal both bone and soft tissue. This in turn minimizes surgical trauma, providing the optimal conditions for healing to occur. The final principle, early pain-free mobilization, is important in preventing fracture or cast disease as well as returning the injured limb to early function. This is reiterated in the AO tenet "Life is movement, movement is life." Over time, these four principles have proven to be very successful in improving the results of fracture treatment and providing an early return to function of the injured limb.

### MECHANICAL PROPERTY OF BONE AND FRACTURE PATTERNS

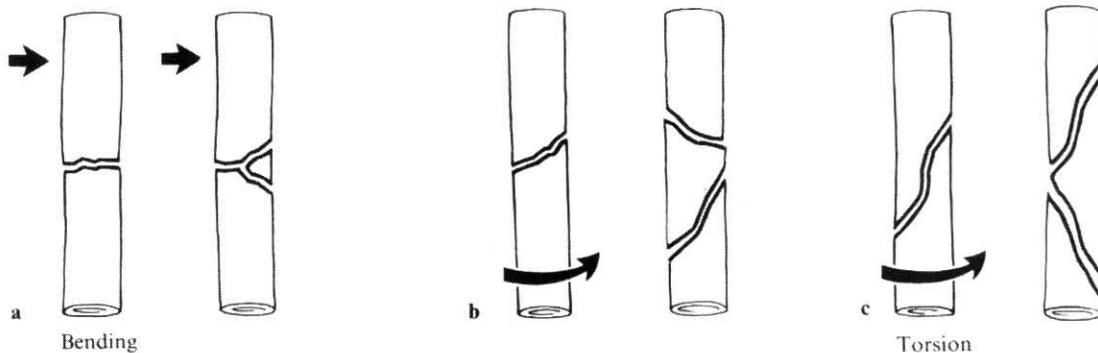
The main function of bone is to be a supporting structure and to transmit load (Fig. 52-1A). Bone will be subjected to various including pure compression, bending, torque, and twisting. It is known that bone is strongest when in compression and weakest when in tension. Therefore, fractures due to compression only are rare and occur only in areas of cancellous bone with a thin cortical shell. Thus, these fractures occur in the metaphyses, vertebral bodies, and calcaneus. The common fractures seen in tubular bone include transverse, oblique, and spiral.

Direct bending forces will produce a transverse fracture (Fig. 52-1A). These fractures may contain a small triangular fragment, which is always found on the compression side. This fragment is extruded from bone under load and therefore retains very little attachment to the underlying soft tissue, thus minimizing its blood supply. One must remember this when attempting to fixate these fractures. If fragments are very small, they may be ignored. However, if larger, they should be left alone and cancellous bone should be utilized to fill any defects.

An indirect force may produce either a spiral or oblique fracture pattern (Fig. 52-1B, C). Accompanying these fractures is usually a butterfly fragment of similar configuration. Due to their larger size, these fragments usually retain their soft tissue attachments, allowing fixation without disrupting their blood supply. A mixed pattern of fractures also occurs when a combination of forces is applied.

### ANATOMY OF A SCREW

It is important to understand the anatomy of a screw in order to understand its use fully. The four main structural components are the root/core diameter, thread diameter, screw pitch, and the lead.<sup>5</sup> The root or core diameter is the minimal diameter of the screw not including the threads (Fig. 52-2). This is important to know because the tensile strength of screws is proportional to the square of the root/core diameter, while the shear strength of screws is proportional to the cube of the root/core diameter. The thread



**FIGURE 52-1.** Types of fracture patterns. A lateral bending force results in a transverse fracture, which may have a small triangular fragment as well as longitudinal fissures on the concave or compression side. Oblique and spiral fractures may have butterfly fragments of corresponding shape. They are the result of a twisting force. Reprinted from Schatzker J, Tile M: *The Rationale of Operative Fracture Care*, p 4, 1987, with permission from Springer-Verlag.

diameter is the maximal diameter including the screw threads (Fig. 52-3). The screw pitch is the distance between two successive threads (Fig. 52-4). Cortical screws have a pitch of 1.25 mm, which allows more threads to purchase cortical bone. Cancellous screws have a pitch of 1.75 mm so that more cancellous bone can be purchased as the screw is inserted. The lead is the distance a screw advances when turned one complete revolution. Other screw parts include the head, land, tip, shank, runout, and thread. The screw head is either cruciform or hexagon. The land is the under-surface of the screw head. The tip is either pointed, round, or fluted. The shank is the distance between the land and the start of the screw runout (Fig. 52-5). The runout is the distance from the end of the shank to the first thread (Fig. 52-6). The screw thread is either asymmetric a (buttress) or symmetrical (Fig. 52-7).


**TYPES OF SCREWS**

The function of screws is either to fasten plates or similar devices onto bone or, as lag screws do, to hold fragments of bone together. Screws are distinguished by the way they are inserted into bone, what type of bone they are intended for, their function, and their size. They can be self-tapping or

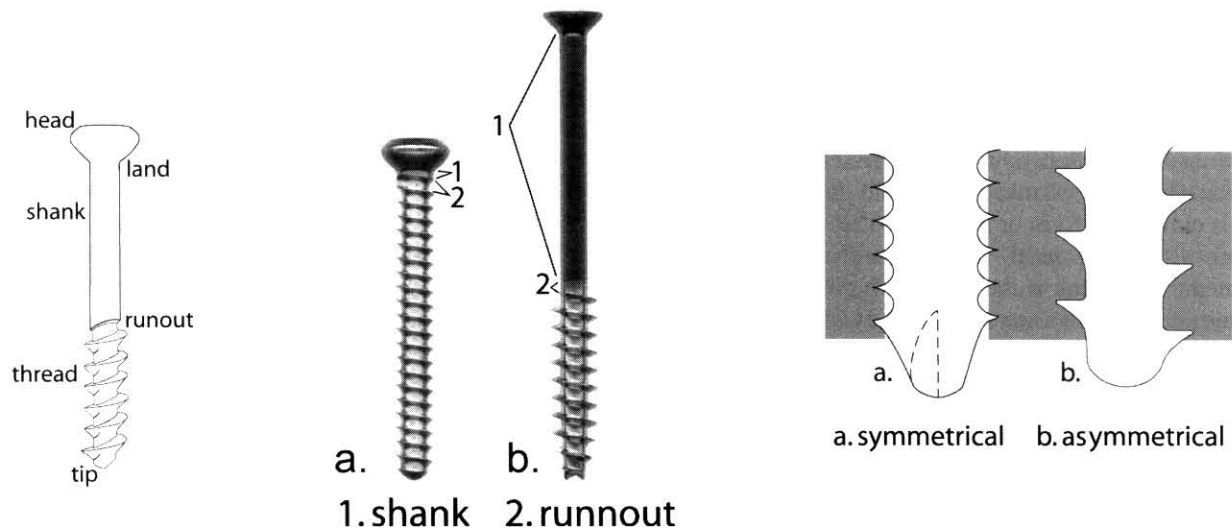
non-self-tapping, cortical and cancellous, lag screws or mini, and small- or large-fragment screws.

**Self-Tapping and Non-Self-Tapping Screws**

Self-tapping screws are designed so that after a pilot hole is drilled into bone they can be directly inserted by screwing them in. The pilot hole is larger than the core of the screw. This screw must cut its own thread as it is inserted and thus is subjected to resistance, especially in thick cortical bone. It was once thought that self-tapping screws had a weaker hold in bone. In 1975, experimental studies by Schatzker et al. revealed that a self-tapping screw can be removed and reinserted without weakening its hold in bone.<sup>6-8</sup> However, if the screw is angled while removing it from bone, a new thread pattern will form while destroying the previous cut thread. Therefore, self-tapping screws are not recommended to be used as lag screws. Non-self-tapping screws require a pre-drilled pilot hole followed by cutting of the threads through cortical bone with a tap of corresponding screw thread size. The tap is much sharper than the screw threads and also efficiently clears any bony debris which could obstruct screw insertion. These screws can be removed and reinserted without cutting a new thread channel, as the screw alone is not able to cut a channel in cortical bone.



**FIGURE 52-2, 3 and 4.** Core diameter, thread diameter, and screw pitch.



**FIGURE 52-5, 6 and 7.** Head, land, shank, runout, thread (a. symmetrical, b. asymmetrical), and tip.

### Cortical and Cancellous Screws

Cortical screws are always fully threaded. They can function as either a positional screw, providing plate fixation, or as a lag screw, exerting compression. They are either self-tapping or non-self-tapping. Cortical screws that are non-self-tapping must be tapped before insertion. Cortical screws can range in size from 1.5 to 4.5 mm. Cancellous screws can be either fully or partially threaded. Fully threaded screws are used to fasten plates, while partially threaded screws are used as lag screws. Cancellous screws are characterized by a thin core and wide and deep thread. They are designed as non-self-tapping screws, requiring that only the near cortex be tapped. However, if the far cortex is thick, as in younger individuals, the far cortex may need to be tapped to help facilitate insertion of the screw.

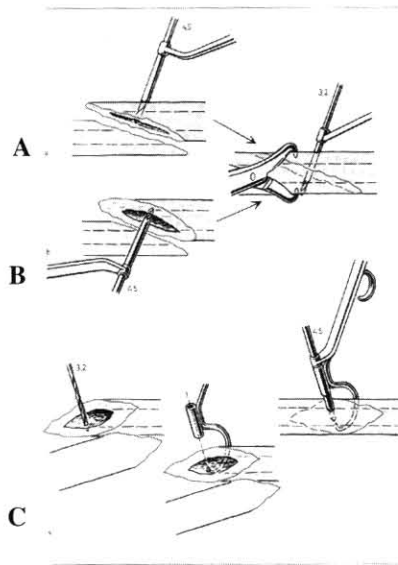
### Lag Screws

A lag screw is a screw in which only the far cortex is purchased by the screw threads. Therefore, the near cortex is not purchased by the screw. This allows compression of the two bone fragments when the lag screw is tightened. Examples of screws designed as lag screws include partially threaded screws, malleolar screws, and large and small cancellous bone screws. These screws have no threads on the part of the screw which passes in the near cortex, and therefore they do not engage the near cortex. Only the distal aspect of these screws are threaded and engage the far cor-

tex. Compression will only occur as long as the threads do not cross the fracture line. In order for a fully threaded screw to function as a lag screw, the near cortex must be overdrilled to ensure that the hole is equal to or greater than the size of the outer diameter of the screw thread. This hole is termed the gliding hole (Fig. 52-8A). Next, the far cortex is drilled to the diameter of the pilot hole and then tapped with a tap which is the same diameter as the screw threads. The hole in the far cortex is termed the thread hole (Fig. 52-8B). When the screw is inserted and tightened, static interfragmental compression is generated. The term *static* is used because the compression does not change significantly with load.

To achieve maximum interfragmental compression, the lag screw must be inserted in the middle of the fragment equidistant from the fracture edges and directed at a right angle to the fracture plane. If the screw is not placed perpendicular to the fracture line, it will cause a shearing force as it is tightened and the fragments will shift (Fig. 52-9A, B). This will also occur if the screw is inserted at an acute angle to the fracture plane (Fig. 52-9B).

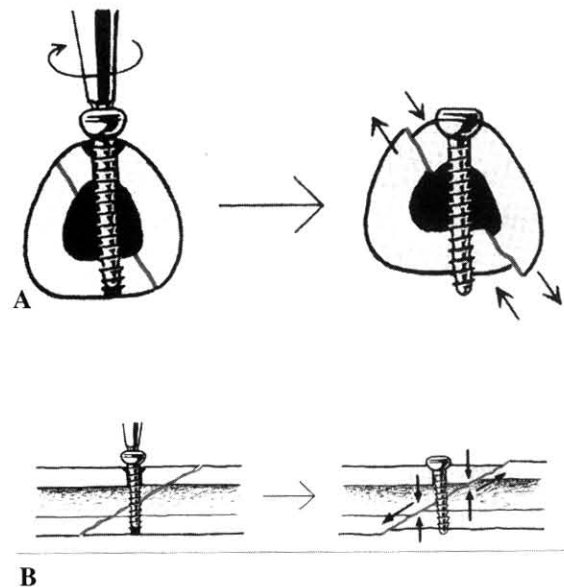
In the metaphysis, lag screw fixation may be achieved using cancellous bone screws. However, in diaphyseal bone two conditions must be met to achieve stability with lag screws alone: the length of the fracture must be at least twice the diameter of the bone at the fracture site and the fracture must be fixated with at least two screws. Today, two additional principles have been added to these to



**FIGURE 52-8.** The drilling of a gliding hole prior to the reduction either from the outside in (A) or inside out (B). (C) The drilling of a thread hole prior to the reduction and the drilling of the gliding hole after reduction with the aid of the pointed drill guide. Reprinted from Müller M, Allgöwer M, Schneider R, Willenegger H: *Manual of Internal Fixation: Techniques*, p 193, 1979, with permission from Springer-Verlag.

comprise what is known as the rule of twos: at least two threads should exit the far cortex when inserted, and the screw should be inserted with two-finger tightness; in other words, only two fingers should be used to turn the screwdriver when tightening the screw.

To assess stability of lag screw placement, we must look at the direction in which a screw is inserted in order to produce maximum compression as well as to withstand the forces tending to cause displacement of the fragments. When bone is loaded axially, shearing forces are created at the fracture and the fragments may glide upon each other, causing loss of reduction and stability (Fig. 52-10). When a screw is inserted at right angles to the axis of the bone, it may introduce a shearing force at the fracture as it is tightened, but under axial load it will prevent the fracture fragments from gliding upon one another and displacing. Therefore, ideally when fixating a fracture with only lag screws, one screw should be at right angles to the fracture and a second at right angles to the long axis of bone. This also holds true for long spiral fractures where three or four lag screws are used. Important, however, is the spacing rather than the number of screws. In this case the central lag screw is usually placed at right angles to the axis of bone,



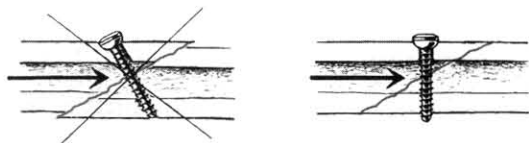**FIGURE 52-9.** (A) If a lag screw is inserted at an angle other than 90° to the fracture plane, then as it is tightened it (B) introduces a shearing moment and the fracture may displace. (A) Reprinted from Müller M, Allgöwer M, Schneider R, Willenegger H: *Manual of Internal Fixation: Techniques*, p 188, 1979, with permission from Springer-Verlag. (B) Reprinted from Müller M, Allgöwer M, Schneider R, Willenegger H: *Manual of Internal Fixation: Techniques*, p 189, 1979, with permission from Springer-Verlag.

and those at each end at right angles to the fracture plane (Fig. 52-11).

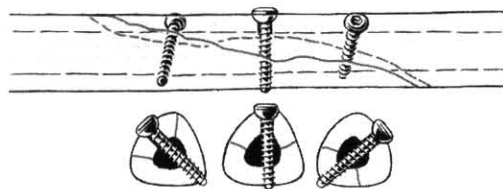
There are several indications for lag screw insertion. As a rule, whenever there are two fragments of bone whose size and shape allow lag screw fixation, that is what should be used. Intra-articular epiphyseal and metaphyseal fractures are ideally suited for lag screw fixation (Fig. 52-12). Lag screw fixation also works well on avulsion fractures (Fig. 52-13). When used alone, lag screw fixation is utilized in short tubular bones and for epiphyseal and metaphyseal fractures.

### Mini-, Small-, and Large-Fragment Screws

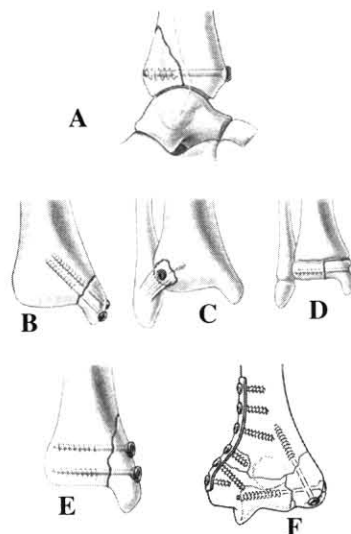
These screws are named based on the size of the overdrill or thread diameter of the screw. Minifragment screws include the 1.5- and 2.0-mm sizes. These screws are used for the smaller bones in the foot, such as the phalanges and



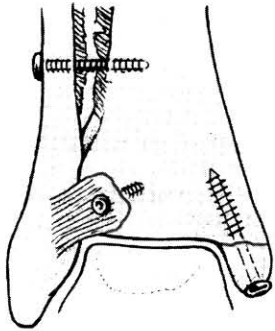
**FIGURE 52-10.** A lag screw inserted at right angles to the fracture plane provides maximum interfragmental compression but minimal axial stability. Under axial load, one fragment tends to glide on the other with loss of reduction and fixation. If a screw is inserted at right angles to the long axis of the bone, it provides maximum axial stability but tends to cause some dislocation of the fragments as it is tightened. Therefore, it is best to have one screw at right angles to the axis and the others at right angles to the fracture plane (see Fig. 52-11). Reprinted from Müller M, Allgöwer M, Schneider R, Willenegger H: *Manual of Internal Fixation: Techniques*, p 191, 1979, with permission from Springer-Verlag.



**FIGURE 52-11.** In a spiral fracture which is fixed with more than two screws, the central screw is usually at right angles to the axis of the bone and is thus able to prevent axial displacement. The other two screws will be at right angles to the spiral fracture plane and will ensure maximal compression. Reprinted from Müller M, Allgöwer M, Schneider R, Willenegger H: *Manual of Internal Fixation: Techniques*, p 191, 1979, with permission from Springer-Verlag.



**FIGURE 52-12.** Lag screws find their major application in the reconstruction of intra-articular epiphyseal and metaphyseal fractures. (A) A 6.5-mm cancellous bone screw used for the fixation of a Volkmann's triangle (posterior lip) with the screw passing from front to back just above the ankle joint. (B) Two 4.0-mm partially threaded small fragment cancellous bone screws used for fixation of the medial malleolus. (C) A 4.0-mm partially threaded small fragment cancellous bone screw plus its 7.0-mm washer used for the fixation of the avulsed anterior syndesmosis with its tubercular insetion (tubercle of Tillaux-Chaput). (D) A 4.5-mm malleolar screw used for the fixation of an epiphyseal fracture separation of the distal tibia (Salter-Harris III). Line across fibula represents growth plate in a child. (E) Two 4.0-mm partially threaded small-fragment cancellous bone screws used for the fixation of a type A fracture of the medial malleolus. (F) Two 4.0-mm partially threaded small fragment cancellous bone screws used for lag screw fixation of the epiphysis and of the condyle to the metaphysis of the distal humerus. Reprinted from Müller M, Allgöwer M, Schneider R, Willenegger H: *Manual of Internal Fixation: Techniques*, p 195, 1979, with permission from Springer-Verlag.



**FIGURE 52-13.** Avulsion fractures are ideally suited for lag screw fixation. Because of persisting instability a fully threaded positioning screw has been inserted between the tibia and fibula with threads engaging both in the tibia and fibula to avoid compression. The two remaining screws are lag screws. Reprinted from Müller M, Allgöwer M, Schneider R, Willenegger H: *Manual of Internal Fixation: Techniques*, p 199, 1979, with permission from Springer-Verlag.

metatarsals. Small-fragment screws include the 2.7-, 3.5-, and 4.0-mm sizes. These screws are used on the medium to larger bones of the foot and ankle. Large-fragment screws include the 4.5- and 6.5-mm sizes. These are used on the large bones of the foot and ankle.

## TYPES OF PLATES

Plates are fixation devices which are fastened to bone. They are divided by the type of biomechanical function they provide. The shape of the plate does not indicate its function; it is only a reflection of the local anatomy. The various types of plates include protection or neutralization plates, compression plates, buttress plates, and blade plates. It is important to know that each plate can provide multiple functions, depending on the technique applied to the different types of plate. For example, a one-third tubular plate can act as a neutralization plate (no compression), or it can be eccentrically loaded and create compression. Therefore, although the plates are physically the same, many of the plates can provide a multitude of different tasks.

## Protection or Neutralization Plates

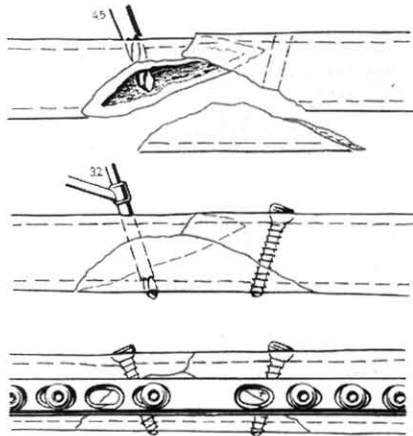
This type of plate functions to protect lag screw fixation when used in combination for diaphyseal fractures. It will protect the lag screw from all torsional, bending, and shearing forces, thus protecting the interfragmental compression. This protection will allow patients early mobilization of the extremity as well as limited loading. Although a plate may exert axial compression, it will never exert the same amount of interfragmental compression as a lag screw. The type of plate and number of screws used will depend on the type of fracture and quality of bone. A lag screw may be placed outside the plate (Fig. 52-14) or inserted through the plate (Fig. 52-15), depending on the type and location of the fracture. A neutralization plate is termed an antiglide plate when placed on the posterior aspect of the fibula. This is done to prevent the distal fragment from migrating proximally.

## Compression Plates

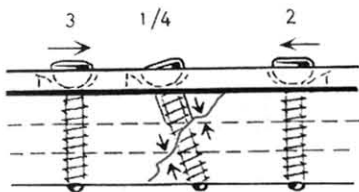
Two types of compression plates can be utilized. The first is a *static compression plate*, in which tension is applied to the implant and compression is generated at the fracture interface. These plates are used for transverse and short oblique fractures which are not amenable to lag screw fixation. This can be accomplished using a self-compressing plate. A self-compressing plate creates axial compression by combining screw hole geometry with screw insertion. The screws are inserted through oval holes eccentrically as far from the fracture as possible, thus creating axial compression (Fig. 52-16A, B). Once the first two screws are inserted eccentrically, the remaining screws are inserted through the center of the holes (Fig. 52-16C). The second type of compression plate is a *dynamic compression plate*. This plate not only generates compression at the fracture interface, but when the implant is subjected to a physiological load further compression is generated at the fracture plane. This type of compression follows the principle of *tension band fixation*, which states that under eccentric loading a bone will have one side loaded in tension and the other in compression,<sup>9</sup> with a gap first opening up on the side of tension (Fig. 52-17A, B). A plate is therefore applied to the side of tension (convex side) to prevent this gapping, which in turn creates compression on the opposite side (concave side) (Fig. 52-17C). If the plate is applied to the concave side, when loaded the only resistance to failure is the stiffness of the plate (Fig. 52-17D).

## Buttress Plates

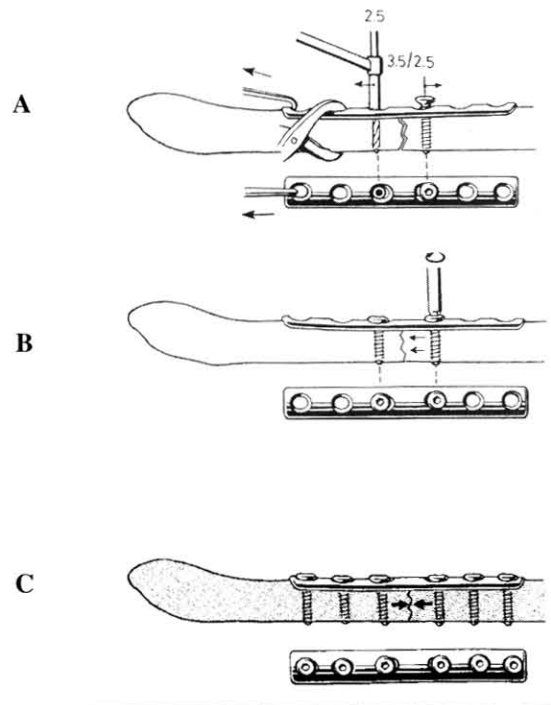
The main function of a buttress plate is to support bone and prevent deformity from shearing or bending forces.



**FIGURE 52-14.** Note that in this wedge fracture the primary stability is achieved with the lag screws and not the plate. A plate serves only to protect the lag screws. Reprinted from Müller M, Allgöwer M, Schneider R, Willenegger H: *Manual of Internal Fixation: Techniques*, p 201, 1979, with permission from Springer-Verlag.

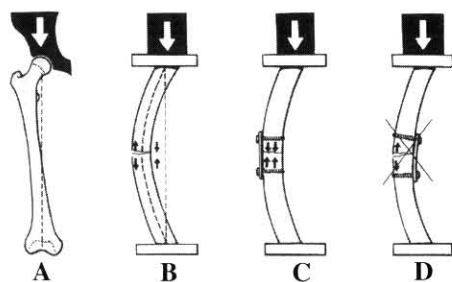


**FIGURE 52-15.** A lag screw can be inserted through the plate once axial compression has been generated. This greatly increases the stability of the fixation. Reprinted from Müller M, Allgöwer M, Schneider R, Willenegger H: *Manual of Internal Fixation: Techniques*, p 201, 1979, with permission from Springer-Verlag.



**FIGURE 52-16.** The compression of a transverse fracture of the fibula with a one-third tubular plate. (A) A 2.5-mm drill hole is made in one fragment, 1 cm from the fracture. The depth is measured through the plate, the hole is tapped with a 3.5-mm cortex tap, and a 3.5-mm cortex screw is inserted but not completely tightened. The fracture is now reduced and held reduced with the bone clamp. With a book, traction is applied to the plate and, using the 3.5/2.5-mm drill sleeve, a 2.5-mm hole is drilled eccentrically through the plate as far from the fracture as the hole allows. (B) The depth is measured, the hole is tapped, and the second 3.5-mm cortex screw is inserted. As the screw head engages the plate, it is pushed towards the fracture together with the bone fragment, which generates axial interfragmental compression. (C) The alternate tightening of the first and the second screw will result in axial compression and stable fixation. The remaining screws are inserted in the neutral position through the center of the oval holes. Reprinted from Müller M, Allgöwer M, Schneider R, Willenegger H: *Manual of Internal Fixation: Techniques*, p 233, 1979, with permission from Springer-Verlag.





**FIGURE 52-17.** (A) Eccentric loading of a bone results in one side being loaded in tension and the other in compression. (B) Under an eccentric load, the gap will open first on the tension side. (C) A plate applied to the tension side of bone will prevent the deformity. As load increase, the plate will be put under tension and the cortex opposite the plate will come under compression. (D) If the plate is applied to the concave side which is under compression, under load the only resistance to deformity will be stiffness of the plate. Reprinted from Müller M, Allgöwer M, Schneider R, Willenegger H: *Manual of Internal Fixation: Techniques*, p 233, 1979, with permission from Springer-Verlag.

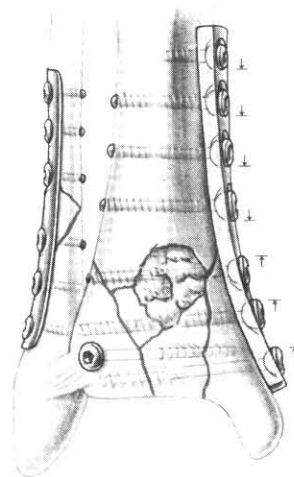
Therefore, it must be placed over the area or cortex which is subjected to load. It must also conform to the size and shape of the underlying bone to prevent deformity. In applying a buttress plate, it must be contoured very accurately to fit the area or cortex under load. Next, fixation should begin in the middle of the plate with advancement of the screws one after another towards both ends of the plate (Fig. 52-18). These plates are commonly utilized in distal tibia or pilon fractures in which severe comminution exists (Figs. 52-19, 52-20).

### Blade Plates

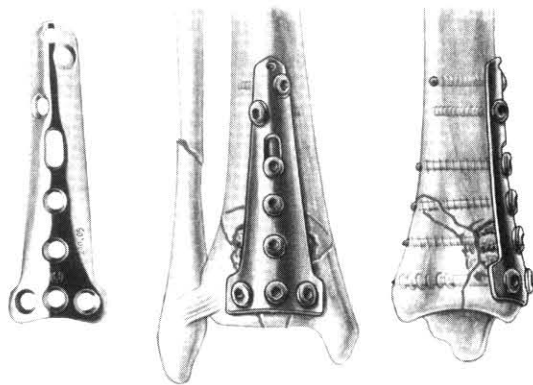
Originally, AO developed a 130° plate for the proximal femur and a 95° condylar plate for the distal femur. Modifications to these plates resulted in the 90° blade plate, which can be used for tibiocalcaneal arthrodesis and tibial osteotomies. This plate can provide stability and compression. With respect to the tibiocalcaneal arthrodesis, the blade is usually placed into the lower middle to one-third of the calcaneus, parallel to the sole of the foot.<sup>10</sup> The length is then determined and the plate is fastened to the posterior tibia. The distal holes of the plate provide compression as they are inserted.

### Locking Compression Plates

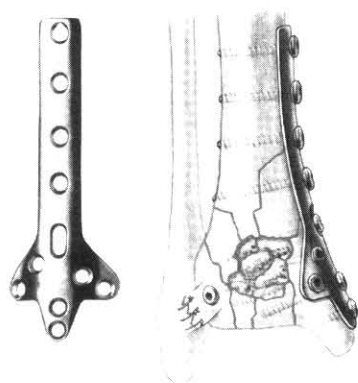
This is a plate-and-screw system that merges locking screw technology with conventional plating techniques. Locking screws create a fixed angle construct relative to the plate while providing typical AO plating techniques. This is advantageous in scenarios when osteopenic bone or shattered bone is present and screw purchase is poor. Locking screws do not rely on plate/bone compression to maintain stability, but are utilized similarly to several small angles blade plates. Locking compression plate technology features unicortical locking screws allowing for better vascularity and can be used as an internal fixator permitting stable bridging over fragmented bone.<sup>11</sup>



**FIGURE 52-18.** The principle of the buttress plate: the buttressing of a pilon fracture. Whenever a screw is inserted through one end of an oval screw hole closest to the fracture it is in the “buttress mode.” In the main fragment, the screws prevent any shift of the plate. The screws in the fragment which is being buttressed prevent any shift of the bone under the plate. This prevents any deformity under axial load. Begin the fixation of the plate to the bone in its middle and advance the insertion of screws in an orderly fashion one after another towards both ends of the plate. Reprinted from Müller M, Allgöwer M, Schneider R, Willenegger H: *Manual of Internal Fixation: Techniques*, p 209, 1979, with permission from Springer-Verlag.



**FIGURE 52-19.** The spoon plate is rarely used for the treatment of acute fractures as demonstrated in this illustration. It is used mainly to treat metaphyseal nonunions of the distal humerus and tibia. Reprinted from Müller M, Allgöwer M, Schneider R, Willenegger H: *Manual of Internal Fixation: Techniques*, p 215, 1979, with permission from Springer-Verlag.



**FIGURE 52-20.** The cloverleaf plate is designed to buttress the distal tibia on its medial side. Note: It takes small-fragment screws in all holes. Reprinted from Müller M, Allgöwer M, Schneider R, Willenegger H: *Manual of Internal Fixation: Techniques*, p 215, 1979, with permission from Springer-Verlag.

## Reconstruction Plates

Reconstruction plates are typically used on fractures near the joint where contouring is needed. The plates are notched, making them easy to contour, bend, twist, or make serpentine. Sizes include 2.7- 3.5-, and 4.5-mm curved and straight. A disadvantage of these plate is that repeated bending will weaken them.

## Dynamic Compression Plate (DCP)

This is indicated primarily for fractures of the diaphysis and can be used for compression, neutralization, buttress, or bridging. The plate comes in a variety of sizes: 2.0-, 2.7- 3.5-, and 4.5-mm. The center of the plate is solid for placement over the fracture and the plate hole allows 20° of angulation.<sup>12,13</sup>

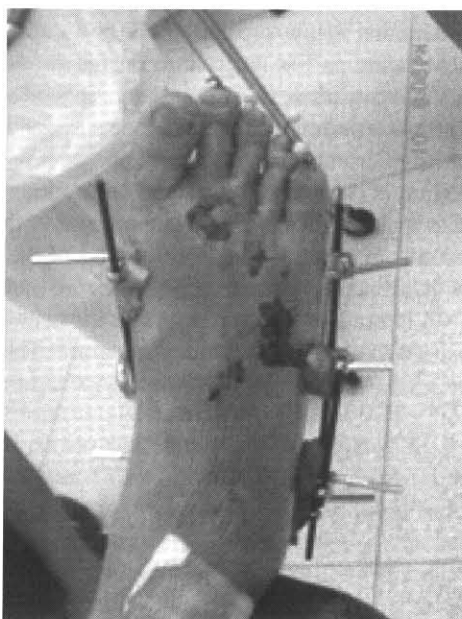## Limited Contact Dynamic Compression Plate (LC-DCP)

This indicated primarily for fractures of the diaphysis and can be used for compression, neutralization, buttress or bridging. The plate comes in 2.0-, 2.4-, 3.5-, and 4.5-mm sizes. The holes are ramped on both sides for multidirectional compression of multiple fracture fragments. The underside of plate is scalloped for limited contact to bone to improve circulation. The scalloped underside also helps with smooth plate contouring, and the undercut in the plate allows for 40° of screw angulation.<sup>14,15</sup>

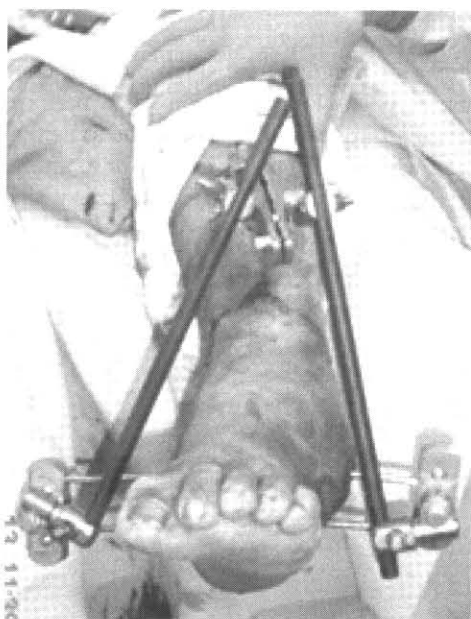
## EXTERNAL FIXATORS

Historically, external fixation has been used in foot and ankle surgery for the treatment of open fractures and occasionally ankle arthrodesis. In the past two decades, the use of external fixation has grown significantly and most likely will continue to be expanded upon in the role of foot and ankle surgery.


There are many different types of external fixators. They can be divided into two general categories: monolateral and circular frames. The more conventional type, monolateral, relies on large-diameter stiff-threaded pins to provide stability. This type of frame is most useful in situations where length and stability are needed. Recent hybrid frames (a combination of monolateral and circular) have become popular. The circular (e.g., the Ilizarov) relies on smooth non-threaded wires under tension to provide stability. This minimizes soft tissue injury and bony reaction. Biomechanically the two systems are different, as is the biomechanical



**FIGURE 52-21.** External fixator used with posttraumatic foot injury for stabilization and restoration of length.



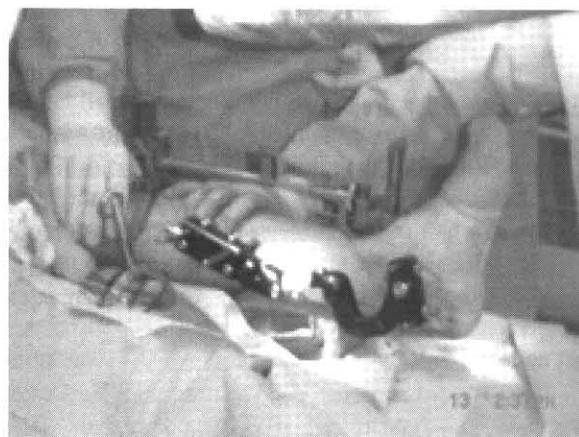
**FIGURE 52-23.** External fixator used with posttraumatic ankle injury for stabilization and restoration of length.



**FIGURE 52-22.** External fixator used for callus distraction.



**FIGURE 52-24.** External fixator use postoperatively after Charcot reconstructive surgery.



**FIGURE 52-25.** External fixator applied to the medial aspect of the leg and foot for distraction.

environment of bony fracture treatments. Ilizarov developed the technique of osteogenesis to regenerate large defects in bone. The circular external fixators provide for a more accurate and gradual correction. Using the Ilizarov technique, weightbearing is permitted immediately following surgery, improving upon rehabilitation, and minimizing postoperative osteoporosis.

External fixators can be used in Charcot reconstruction, pilon fractures, realignment procedures, limb lengthening, distraction for implants, stabilizing fractures (trauma), non-unions, arthrodesis, bone transport, distraction, compression, angulation, translation, and rotation.

## TECHNIQUE TIPS

### Joint Preparation

It is important to discuss the preparation of joints before discussing how to fixate them. Careful anatomical dissection is of utmost importance. Preservation of blood supply while maintaining soft tissue integrity is key to providing an optimum environment for healing. As a rule, when preparing a joint for fusion, all soft tissue structures must be removed or resected from the joint surfaces in order to allow for optimal healing. Failure to do so may lead to delayed union, malunion, nonunion, or pseudoarthrosis. Also, there must be good, healthy, bleeding bone at the site of fusion. This will require curettage or resection of the cartilage and subchondral plate. If necessary, subchondral drilling may be performed to help stimulate bleeding.

### Burr Hole Technique

This is a simple technique which creates a small hole in cortical bone similar to a countersink, but more advantageous.<sup>16</sup> The burr hole technique is created by drilling a small hole utilizing the round ball burr. The hole should be deeper than one-half of the diameter of the screw head to be used. This hole will act to prevent stress risers, provide equal and symmetrical compression, seed the screw head, and provide a path through which the screw head travels. It is a fast and simple technique that works well.

### Shear-Strain-Relieved Bone Graft

A shear-strain-relieved bone graft is a very useful technique in many arthrodesis and fracture treatments of the foot and ankle. Shear and strain (micromotion) can occur with well-fixated arthrodesis/fracture sites of the foot and ankle. Internal fixation does not totally eliminate micromotion,

and shear and stress may occur with partial weightbearing or with pressure necrosis of internal fixation.<sup>12</sup> This graft technique maintains a low profile, obtains vascularization from adjacent bone, and is not reliant on the surrounding soft tissues.<sup>13</sup> This graft is placed on the peripheral surface areas of an arthrodesis/fracture site to evade shear and stress associated with micromotion at these sites.

After fixation is complete at a fracture/arthrodesis site, a burr is used to make a hole at the peripheral ends of the site. A stab incision is made along the lateral aspect of the calcaneus or medial distal tibia. The soft tissues are mobilized and a 3.5 drill is used to puncture through the near cortex. A curette is used to obtain cancellous bone graft. This graft is then packed into the holes at the arthrodesis/fracture site.

## PITUITARY RONGEUR

The pituitary rongeur is not a new instrument, but one that has found its place in foot and ankle surgery (Fig. 52-26). It is an ideal instrument suited for the hard-to-reach locations when aggressive debridement of cartilage, bone, or soft tissue is needed. Its small size and slim design give the surgeon the ability to reach deep into joint spaces and aggressively resect any unwanted cartilage, bone, or soft tissue without excessive retraction. For example, the pituitary rongeur is great for removing the small piece of bone held tightly by the peroneus longus tendon when performing a tarsal metatarsal arthrodesis or retrieving the remaining cartilage left deep within the subtalar joint prior to arthrodesis. The pituitary rongeur comes in a variety of sizes with different jaw-to-handle orientations.

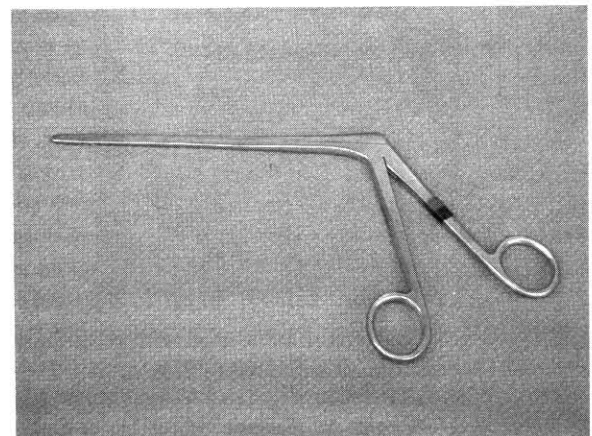


FIGURE 52-26. Pituitary rongeur.

Most hospitals and surgical centers have this instrument as part of their nasofracture or septorhino trays, and it should be explored for use. The pituitary rongeur has made many difficult tasks more easily managed, and we believe it is an invaluable addition to the surgical instrument armamentarium.

## METALLURGY

The uses of internal fixation has facilitated advances in foot and ankle surgery, minimized complications, and improved results. The Second World War was a time of significant interest in identifying implant material used to treat bone fractures. After the war, several individuals reviewed clinical performances of screws and plates that were used to treat soldiers. This effort set the stage for future extensive use of implant applications in bone and joint surgery.

Basic metallurgy consists of compositions, microcleanliness, and microstructure. Properties of implants include physical properties, tensile properties, fatigue, corrosion, biocompatibility, and surface electropolishing.

It is important to have knowledge of the different types of metal utilized for bone and joint surgery. Only a select few metals are useful because of the human body's corrosive environment, poor tolerance, and toxicity to many elements. These materials provide optimum function and durability while remaining inert and avoiding material failure. It is very essential to comprehend the concepts, indications, contraindications of internal fixation to avoid technical complications. Metals used as implants in foot and ankle surgery have included titanium, cobalt, chromium, and many compositions of stainless steel. Metals used appropriately appear to possess excellent biocompatibility and bi durability. Therefore, it is mandatory to understand and respect the use of metals in foot and ankle surgery. For example, stainless steel is a harder material than titanium and titanium is a lighter-weight material than stainless steel. When removing titanium screws, it is very important to have good clearance of soft tissue and bone from the screw head to have the screwdriver deeply seated into the screw head. Failure to do this oftentimes leads to stripping of the screw head because of the softer titanium material, resulting in a more challenging scenario for screw removal. It is essential for the surgeon to understand the incompatibility of stainless steel and titanium. For example, screws made of titanium cannot be used with a stainless steel plate.

## PROCEDURES AND TECHNIQUES

This section will detail how to apply the aforementioned

AO principles and techniques for various forefoot, rearfoot, and ankle procedures. It is based on the authors' techniques and experience with each of these procedures. It will provide a clear and concise approach on how to address each procedure and which fixation to utilize. While there are other ways to address these procedures, the senior author has found the following to be very successful.

## Arthrodesis First Interphalangeal Joint

### Indications

Osteoarthritis, joint contracture, cavus foot, neuromuscular disease<sup>14</sup> (usually performed as part of a Jones tenosuspension).

### Procedure

The patient is positioned supine for surgery, prepped, and draped, and a tourniquet is applied. A transverse or a longitudinal incision or an open Z-plasty is made over the interphalangeal joint. A typical dissection is carried down to the capsular and subperiosteal layers of the interphalangeal joint to expose the condyles. The appropriate resection of the joint via curettage, rongeur, or power saw can be utilized to resect the joint surface. (The author's preference is a power saw for this joint, as this allows for angular correction.) Care should be taken to be certain the joint resection is deep to the subchondral plate to allow for good bone healing.

After joint preparation is completed, the joint can be fused by any one of the following techniques: one cancellous screw, one cortical screw, a screw and a K-wire or two crossed K-wires.

The 4.0 cancellous cannulated screw technique is temporarily fixed with a guide wire, checked with fluoroscopy, and measured, and the screw is inserted. The 4.0 cancellous cannulated screw should not purchase the far cortex.

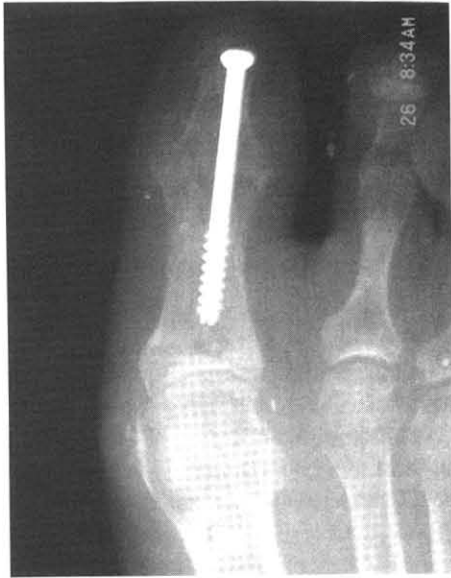The 3.5 or 4.0 cortical screw near cortex is overdrilled to create compression. The glide hole is 3.5 and 4.0, respectively. The thread hole should use a 2.5 and 2.9 size drill, respectively. The length should be measured and the far cortex should be entered but not penetrated to allow for good compression. Care must be taken to be sure that the metatarsal joint has not been penetrated.

Be sure to check the fixation placement with the use of fluoroscopy.

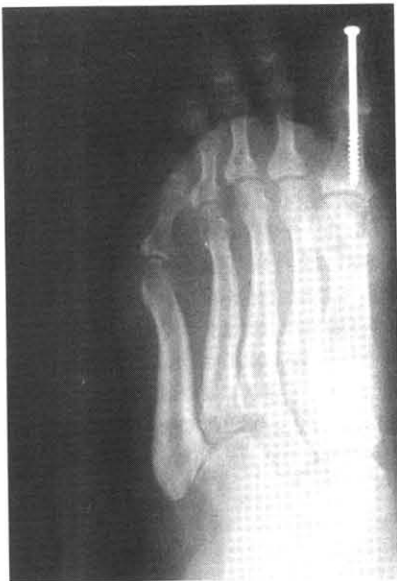### Postoperative care

The patient is instructed to be nonweightbearing with elevation for three days. After three days the patient may

ambulate with a surgical shoe for two to four weeks and then return to a walking shoe once the edema has subsided. (If performed as a Jones tenosuspension, below-the-knee cast immobilization is warranted.)



**FIGURE 52-27.** Arthrodesis of first interphalangeal joint postoperative.



**FIGURE 52-28.** Postoperative first interphalangeal joint arthrodesis.

## Akin Osteotomy

### Indications

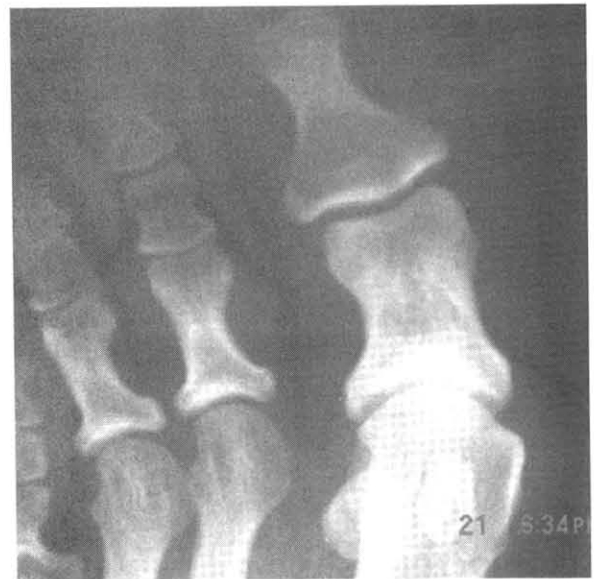Hallux valgus, hallux valgus interphalangeus. Originally described as a primary procedure for hallux valgus,<sup>15</sup> today it is utilized as a secondary adjunct procedure. It is rarely used as a primary procedure alone.

### Procedure

The patient is positioned supine for surgery, prepped, and draped, and a tourniquet is applied. A straight midline incision is made medially to the extensor hallucis longus tendon over the base of the proximal phalanx. The incision is carried deep to the periosteum, freeing the periosteum medially and laterally exposing the base of the proximal phalanx. (The traditional Akin osteotomy is performed with a transverse osteotomy at the specific level of deformity.) The technique for internal screw fixation is an oblique osteotomy performed leaving the hinge intact, reduced and checked under fluoroscopy, then temporarily fixated. A 2.0 drill bit is used to drill the near cortex, a 1.5 drill guide is inserted into the drill hole, and a 1.5 drill is used into the far cortex. Measure and insert the screw. A second screw may be necessary.

### Postoperative care

The patient is kept nonweightbearing for three days and may ambulate postoperatively with a surgical shoe. At two to four weeks the patient may return to a walking shoe.



**FIGURE 52-29.** Akin osteotomy preoperative.

## First Metatarsophalangeal Joint Fusion

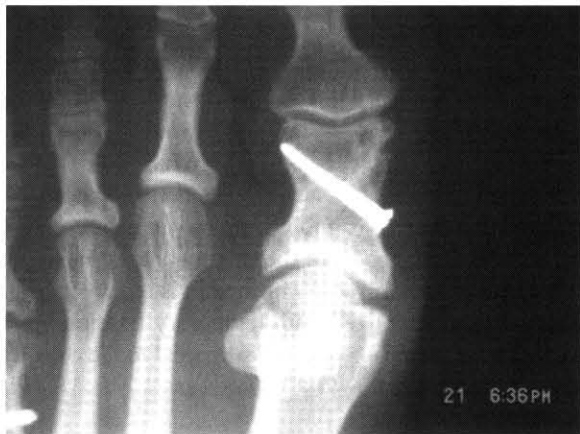### Indications

Osteoarthritis, rheumatoid arthritis, gouty arthritis, severe hallux abductovalgus, joint contracture, hallux limitus, hallux rigidus.<sup>14</sup>

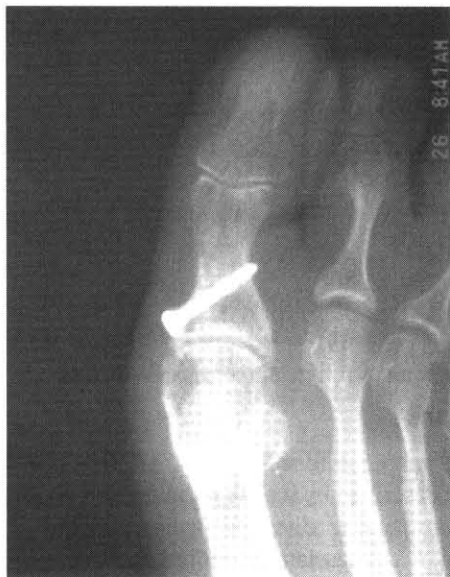### Procedure

The patient is positioned supine for surgery, prepped, and

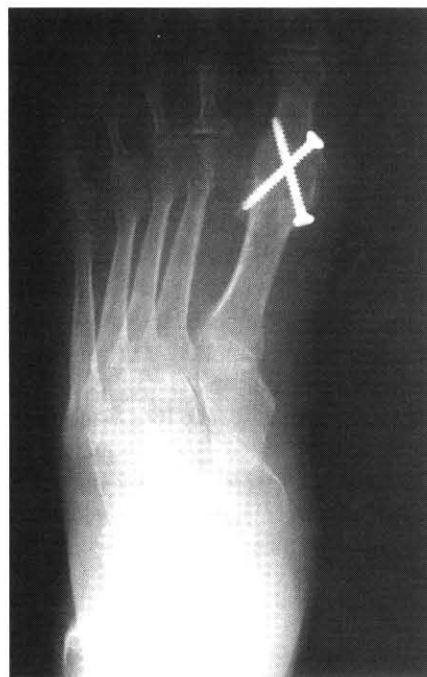draped, and a tourniquet is applied. A longitudinal medial incision is made. Typical dissection is carried down to the capsular and subperiosteal layers of the first metatarsophalangeal joint. Hohmann retractors are used to completely expose the joint. Joint resection via curettage, rongeur, or a power saw can be performed. The author's preference is curettage technique with subchondral drilling. The joint is reduced and stabilized with two temporary K-wires with the great toe in a 10–15° dorsiflexion, attempting to parallel the lesser toes. A small burr hole is made in the inferior medial condyle of the first metatarsal. A 3.5 drill and drill sleeve are used to drill the near cortex. The 2.5 drill sleeve is inserted into the glide hole and a 2.5 drill is used to drill the far cortex. One must be sure to exit the far cortex on the lateral wall of the great toe. Measure and insert a self-tapping fully threaded 3.5 cortical screw. Attention is then directed to the medial aspect of the proximal phalanx, where another burr hole is made. A 3.5 drill and drill sleeve are used to drill the near cortex and the 2.5 drill sleeve is inserted into the glide hole, followed by a 2.5 drill. Be sure the far cortex is penetrated with the 2.5 drill. Measure and insert a self-tapping 3.5 fully threaded cortical screw. This will provide rigid compression to the arthrodesis site. At this time a shear-strain-relief graft can be employed.



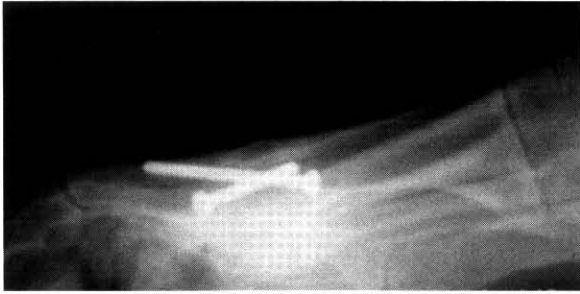
**FIGURE 52-30.** Aiken osteotomy postoperative.



**FIGURE 52-31.** Akin osteotomy postoperative.



**FIGURE 52-32.** Postoperative first metatarsophalangeal joint arthrodesis.



**FIGURE 52-33.** Postoperative first metatarsophalangeal joint arthrodesis.

### Postoperative care

The patient is instructed to be nonweightbearing with elevation for three days. After three days the patient may ambulate with a surgical shoe for two to four weeks. At two to four weeks the patient may return to a walking shoe.

## First Metatarsophalangeal Joint Distraction Arthrodesis

### Indications

Osteoarthritis, rheumatoid arthritis, gouty arthritis, severe hallux abductovalgus, joint contracture, nonunion, revision surgery of the first metatarsophalangeal joint.

### Procedure

The patient is positioned supine for surgery, prepped, and draped, and a tourniquet is applied. A longitudinal medial incision is made. Dissection is carried to the capsular and subperisoteal layers of the first metatarsophalangeal joint. Hohmann retractors are used to expose the joint completely. A minidistractor is applied, and joint resection via curettage, rongeur, or power saw can be performed. A tricortical autogenous cortical-cancellous bone graft is interposed and temporarily fixated. A one-quarter tubular and 2.7 cortical self-tapping screws or a one-third tubular plate and 3.5 self-tapping cortical screws are applied based on the size of the patient. The plate should be applied as a neutralization plate.

### Postoperative care

The patient is instructed to be nonweightbearing in a Jones compressive dressing for two weeks and then changed

to a below-the-knee cast for approximately six additional weeks based on clinical and radiographic exam.

## Reverdin-Green-Laird Bunionectomy

### Indications

Hallux valgus deformity (8–14°). This procedure was originally described by Reverdin in 1881 for correction of hallux valgus.<sup>17</sup> A modification was made by Green to protect the sesamoids and by Laird to correct the intermetatarsal angle.

### Procedure

The patient is positioned supine for surgery, prepped, and draped, and a tourniquet is applied. A traditional longitudinal bunionectomy incision is made over the first metatarsophalangeal joint. Dissection is carried down to the periosteum, where it is mobilized medially and laterally, exposing the distal aspect of the first metatarsal head. After the Reverdin osteotomy is performed, it is reduced, properly positioned, and stabilized with temporary fixation. A burr whole is made dorsal-medial and proximal to the osteotomy. A 4.0 drill is used in the proximal segment. The 4.0 drill bit is removed and the 2.5 drill guide is inserted and drilling is continued with the 2.5 drill until the far cortex is felt. The far cortex should not be penetrated. A depth gage is used for measurement and a 4.0 cancellous screw is inserted. The same fixation can be achieved with the use of a 1.28 guide wire and a 4.0 cannulated cancellous screw.

### Postoperative care

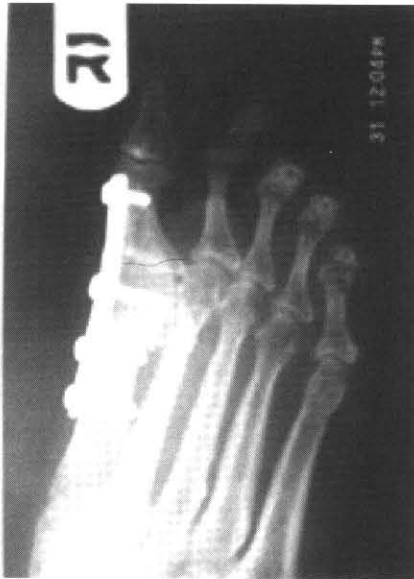The patient is instructed to be nonweightbearing with elevation for three days. After three days the patient may ambulate with a surgical shoe. At two to four weeks the patient may return to a walking shoe.

## Austin Bunionectomy/Kalish Modification

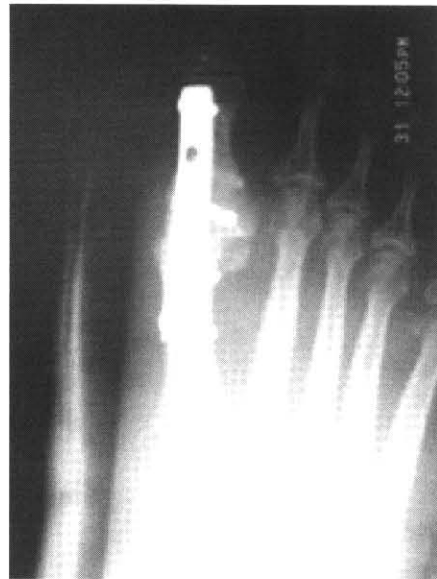### Indications

Hallux valgus deformity (8–14°). This procedure was originally described by Austin as a horizontally directed 60° V-osteotomy of the distal metaphyseal head of the first metatarsal.<sup>18</sup> It was later modified by Kalish to include a dorsal long arm with a 55° V-osteotomy to allow for more stable fixation utilizing two screws.<sup>19</sup>

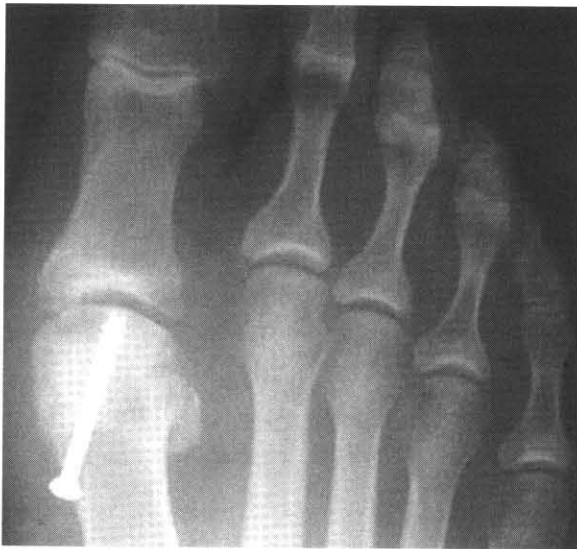



**FIGURE 52-34.** First metatarsophalangeal joint distraction arthrodesis with interpositional bone graft.



**FIGURE 52-35.** First metatarsophalangeal joint distraction arthrodesis with interpositional bone graft.



**FIGURE 52-36.** Reverdin bunionectomy postoperative.

**Procedure**

The patient is positioned supine for surgery, prepped, and draped, and a tourniquet is applied. A traditional longitudinal bunionectomy incision is made over the first metatarsophalangeal joint. Dissection is carried down to the periosteum, where it is mobilized medially and laterally, exposing the distal aspect of the first metatarsal head. After

the Kalish osteotomy (dorsal long arm) is performed, it is reduced, properly positioned, and stabilized with temporary fixation. Two 2.7 screws are used to fixate the osteotomy. This is performed by drilling the dorsal cortex with a 2.7 drill. The 2.7 drill is removed, the 2.0 drill guide is inserted and the 2.0 drilling is continued through the far cortex. Measure the length and insert the 2.7 self-tapping screws.

**Postoperative care**

The patient is instructed to be nonweightbearing with elevation for three days. After three days the patient may ambulate with a surgical shoe for two to four weeks. At two to four weeks the patient may return to a walking shoe.

**Reverse Austin Bunionette**

**Indications**

Taylor’s bunion with an increased lateral deviation angle.

**Procedure**

The patient is positioned supine for surgery, prepped, and draped, and a tourniquet is applied. A traditional longitudinal bunionette incision is made over the distal one-third of the fifth metatarsal. Dissection is carried down to the periosteum, where it is mobilized medially and laterally, exposing

the distal aspect of the fifth metatarsal head. A reverse Kalish osteotomy (dorsal long arm) is performed. It is reduced, properly positioned, and stabilized with temporary fixation. Two 2.0 screws are used to fixate the osteotomy. This is performed by drilling the dorsal cortex with a 2.0 drill. The 2.0 drill is removed, the 1.5 drill guide is inserted, and the 1.5 drilling is continued through the far cortex. Measure the length and insert the 2.0 self-tapping screws.

### Postoperative care

The patient is instructed to be nonweightbearing with elevation for three days. After three days the patient may ambulate with a surgical shoe for two to four weeks. At two to four weeks the patient may return to a walking shoe.

### Oblique Closing Base Wedge Osteotomy

#### Indications

Hallux valgus deformity (large intermetatarsal angle > 15°).

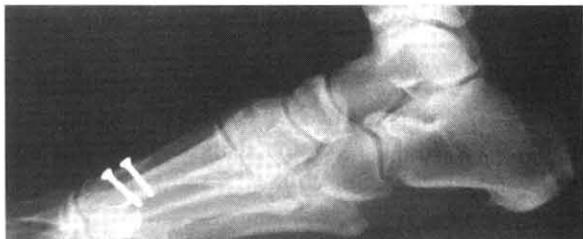

FIGURE 52-37. Austin bunionectomy postoperative.

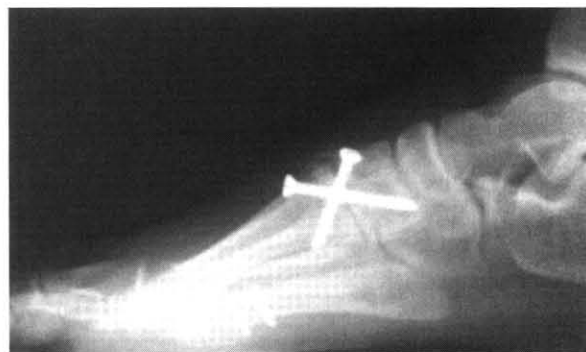

FIGURE 52-38. Reverse Austin bunionette postoperative.

### Procedure

The patient is positioned supine for surgery, prepped, and draped, and a tourniquet is applied. A traditional longitudinal bunionectomy incision is made over the first metatarsal. After appropriate dissection is carried down to the periosteum it is mobilized medially and laterally, exposing the shaft of the first metatarsal. After the osteotomy is performed, it is reduced, properly positioned, and stabilized with temporary fixation. Two 3.5 screws are used to fixate the osteotomy. This is performed by drilling the medial cortex (the initial screw is perpendicular to the osteotomy and the second is perpendicular to the long axis of the first metatarsal) with a 3.5 drill. The 3.5 drill is removed, the 2.5 drill guide is inserted, and the 2.5 drilling is continued through the far cortex. Measure the length and insert the 3.5 self-tapping screws.

### Postoperative care

A Jones compression bandage is applied for two weeks, followed by a nonweightbearing below-the-knee cast for an additional four weeks.

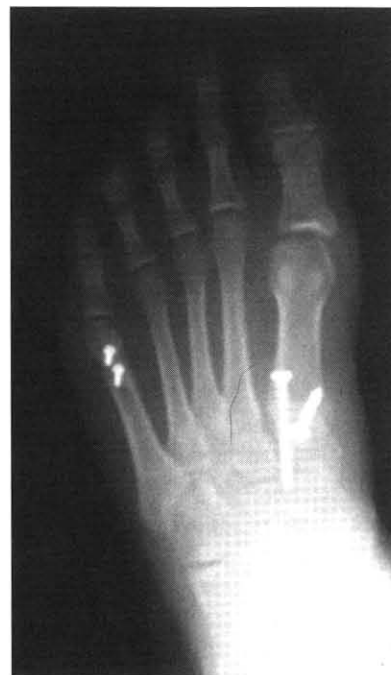
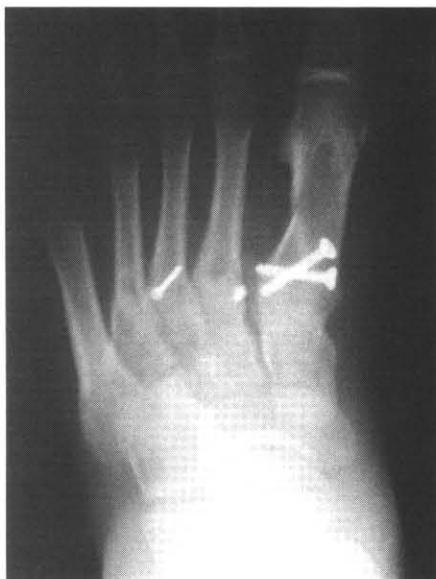
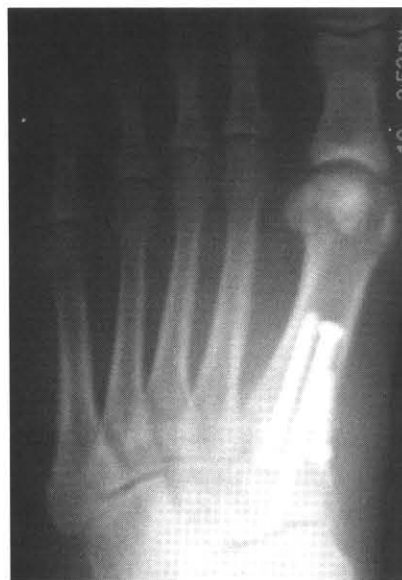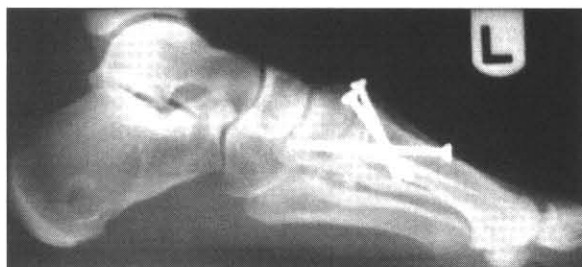FIGURE 52-39. Reverse Austin bunionette postoperative.



**FIGURE 52-40.** Postoperative oblique closing base wedge osteotomy.



**FIGURE 52-42.** Postoperative Lapidus.



**FIGURE 52-41.** Postoperative Lapidus.

### Lapidus Bunionectomy

#### Indications

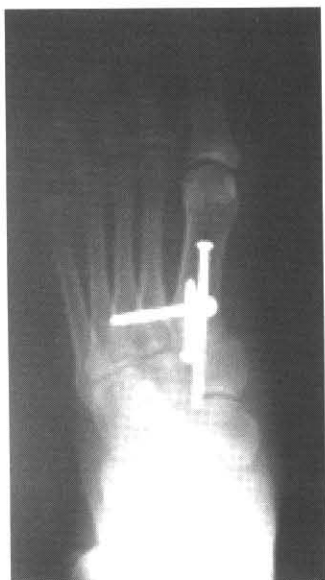Hallux valgus (hypermobile), hallux limitus (elevatus), hypermobile first ray with a sub-two lesion, collapsing medial column. This procedure was originally described by Lapidus in 1934 for the correction of metatarsus primus varus in hallux valgus.

#### Procedure

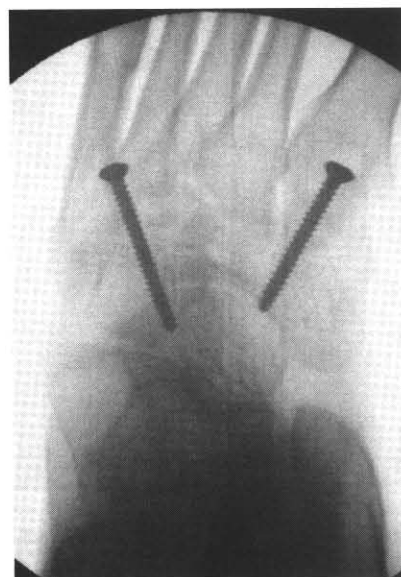The patient is positioned supine for surgery, prepped, and draped, and a tourniquet is applied. An incision is made over the medial cuneiform which courses distally to the midshaft of the first metatarsal. The incision is carried deep

to the periosteum, mobilizing the long and short extensor tendons. A periosteal incision is made, allowing the periosteum to be mobilized medially and laterally and retracted with two Hohmann retractors. The metatarsal-cuneiform joint is incised and freed of all soft tissue. Emphasis is on the removal of all ligament and soft tissue (use of a rongeur) ensuring only exposed bone remains. The metatarsal-cuneiform joint is resected with a power saw, osteotome, curettes, and a pituitary rongeur. After performance of adequate cartilage resection is ensured, the joint is properly positioned and temporarily fixated. The temporary fixation is examined under fluoroscopy. If adequate temporary fixation is achieved, one 4.0 fully threaded cortical screw and two 3.5 cortical screws are utilized. If the anatomy is small, one 3.5 fully threaded cortical screw and two 2.7 fully threaded cortical screws are used.

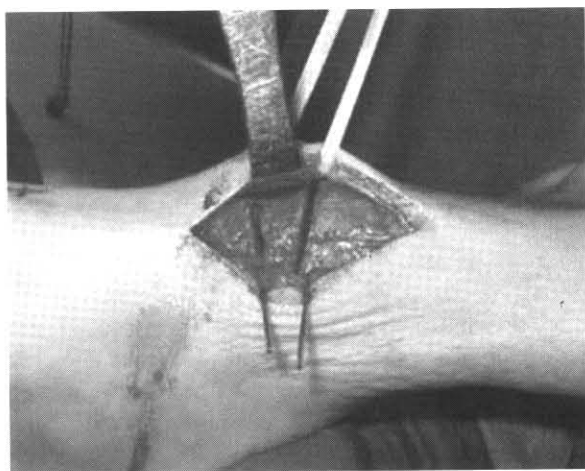A burr hole is made distal in the first metatarsal. A 4.0 drill is drilled from distal to proximal to the metatarsal cuneiform joint. Next a 2.9 drill guide is placed into the distal hole and continual drilling of the cuneiform is performed, exiting at the proximal inferior cortex of the cuneiform. Measure and insert the 4.0 self-tapping screw. This screw should be a long screw in attempt to attain leverage. A burr hole is made on the medial-dorsal and lateral-dorsal aspect of the cuneiform. A 3.5 drill is used, followed by the insertion of a 2.5 guide, 2.5 drill into the far plantar cortex of the metatarsal. Measure and insert two 3.5 self-tapping screws. Another option is to insert the third screw from the medial aspect of the base of the first metatarsal into the base of the second metatarsal.



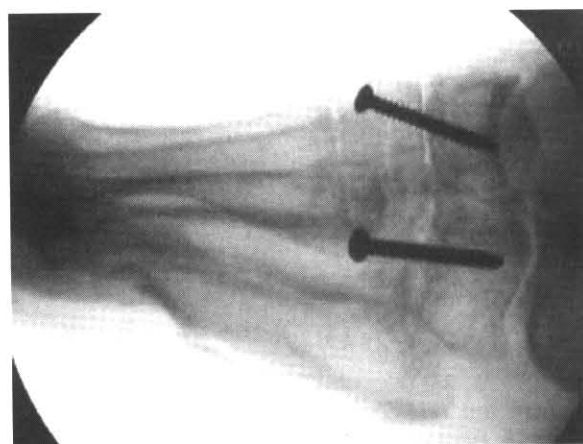**FIGURE 52-43.** Postoperative lapidus.



**FIGURE 52-44.** Midtarsal osteotomy postoperative cavus foot reconstruction.



**FIGURE 52-45.** Intraoperative view midtarsal osteotomy.



**FIGURE 52-46.** Midtarsal osteotomy postoperative cavus foot reconstruction.

A shear-strain-relief graft is then applied to the dorsal-medial and dorsal lateral cortex of the metatarsal cuneiform joint.

### Postoperative care

A Jones compressive bandage is applied for two weeks, followed by a removable walking cast for an additional six weeks. A removable walking cast is then used for an additional four weeks.

## Midtarsal Osteotomy

### Indications

Cavus foot deformity or a pathologically high arch in the absence of hindfoot varus or severe muscle imbalance. This foot deformity is associated with Charcot-Marie-Tooth disease, polio, and idiopathic deformities. The talocalcaneal angle must be normal and the apex of the deformity must be located at the midtarsus.

### Procedure

The patient is positioned supine for surgery, prepped, and draped above the knee to allow visualization of the alignment of the entire lower extremity, and a tourniquet is applied. Two incisions, each approximately 5 cm long, are made medially and laterally. The medial incision is made over the navicular, medial cuneiform, and first metatarsal. The lateral incision is made over the cuboid. These incisions are deepened to the subfascial layers, ensuring that all neurovascular-tendinous tissues are elevated. A dorsal 1-cm wedge with its base dorsal and apex plantar is resected from medial to lateral. Correction in the transverse plane also can be accommodated with this osteotomy. The bone is resected and the forefoot is reduced. A reciprocating technique can be employed to alter the osteotomy. The osteotomy is temporarily reduced and fixation with appropriate AO technique is achieved via 4.0 cannulated cancellous screws or 3.5 solid fully threaded cortical screws. These screws can be fixed from distal to proximal or from proximal to distal. A shear-strain-relief graft is then applied to the respective osteotomy.

### Postoperative care

A Jones compressive bandage is applied for two weeks, followed by a non weightbearing below-the-knee cast for an additional four weeks. A removable walking cast is used for an additional four weeks based on clinical and radiographic evaluation.

## Calcaneal Osteotomy

### Indications

A calcaneal osteotomy is a very powerful procedure that is usually performed in conjunction with other procedures. Indications consist of calcaneal varus, calcaneal valgus, recurrent lateral ankle sprains, posterior tibial tendon dysfunction, flatfoot, peritalar subluxation, calcaneal malalignment, and hindfoot cavus.

### Procedure

The patient is positioned supine for surgery, prepped, and draped above the knee to allow visualization of the alignment of the entire lower extremity, and a tourniquet is applied. An oblique incision is made over the lateral aspect of the calcaneus posterior to the sural nerve and the peroneal tendons. The incision is deepened in the same plane to the periosteum. A large key elevator is used to free the periosteum, exposing the lateral aspect of the calcaneus. Depending what the surgeon is attempting to accomplish, a slide osteotomy (medial, lateral, or proximal) or a wedge osteotomy can be performed. If a slide osteotomy is attempted, the appropriate cut is made from lateral to medial and a laminar spreader is inserted and opened to release the soft tissue attachments, allowing the capital fragment to mobilize and reduce. If a wedge osteotomy is performed, the wedge resection is performed, not penetrating the medial cortex but leaving a medial cortex hinge intact, and the osteotomy is reduced. Two or three (based on the patient size) 2.8 guide wires are inserted from the posterior-inferior calcaneus perpendicular to the osteotomy into the calcaneus, being sure not to penetrate the posterior facet of the subtalar joint, the guide pin is measured and the respective partially threaded 7.3 cannulated cancellous screws are inserted. Final intra-operative views are checked (lateral and axial views) and typical wound closure is performed.

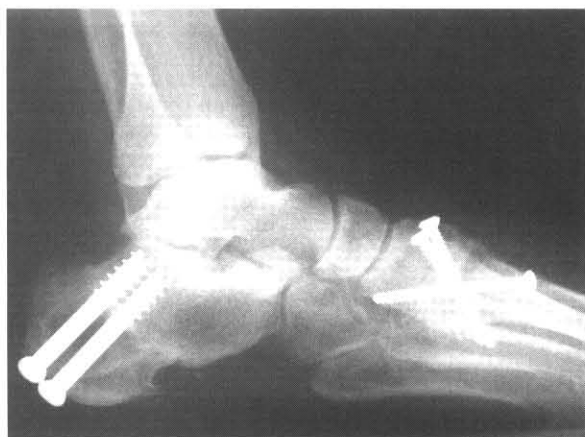### Postoperative care

A Jones compressive bandage is applied for two to four weeks, followed by a nonweightbearing below-the-knee cast for an additional two weeks or until clinical and radiographic demonstration of healing occurs. A removable walking cast is used for an additional four weeks.

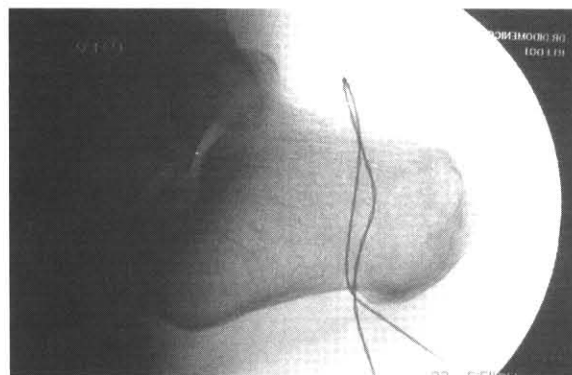
## Percutaneous Calcaneal Displacement Osteotomy

### Indications

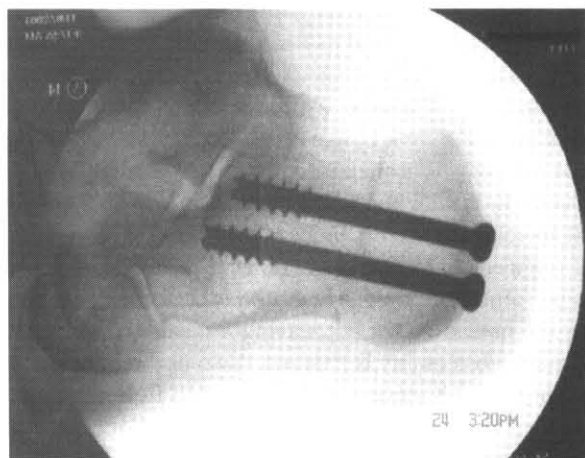
Calcaneal varus, calcaneal valgus deformities associated with conditions previously mentioned under calcaneal osteotomy.<sup>21</sup>



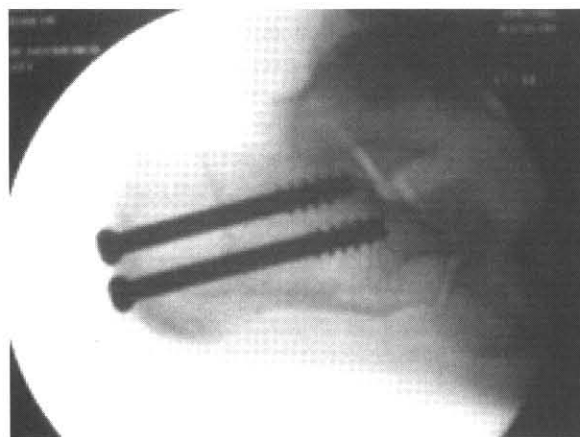
**FIGURE 52-47.** Calcaneal osteotomy postoperative.



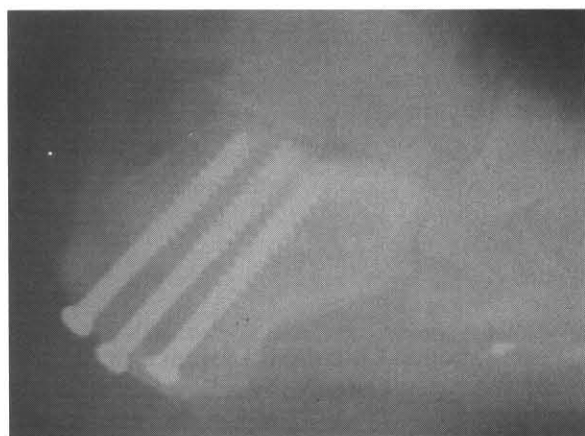
**FIGURE 52-50.** Intraoperative view prior to performing the osteotomy.



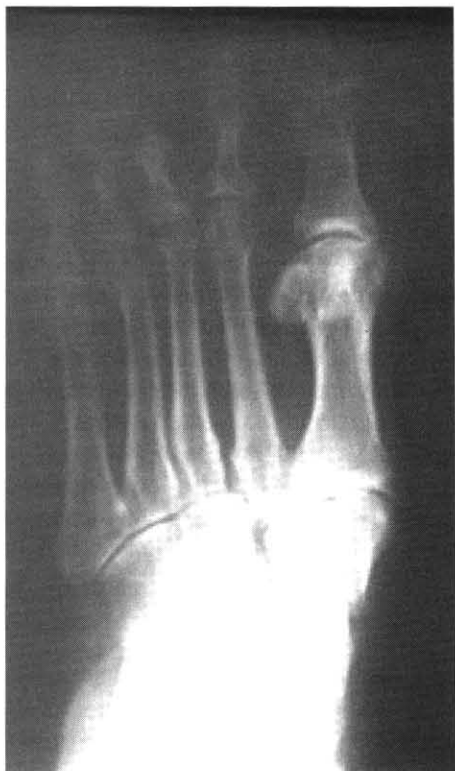**FIGURE 52-48.** Calcaneal osteotomy intraoperative.



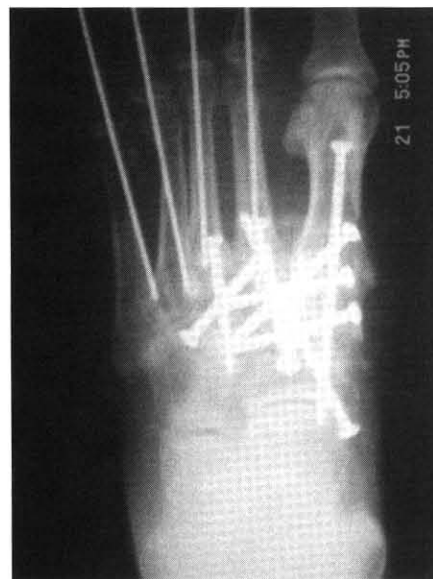**FIGURE 52-51.** Intraoperative percutaneous calcaneal osteotomy with fixation.



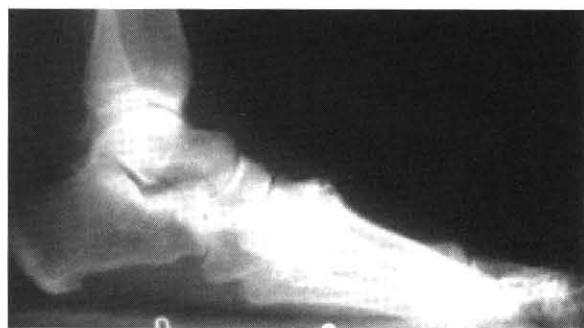**FIGURE 59-49.** Calcaneal osteotomy postoperative with three screws. Three screws were used to accommodate for this patient's large anatomy.



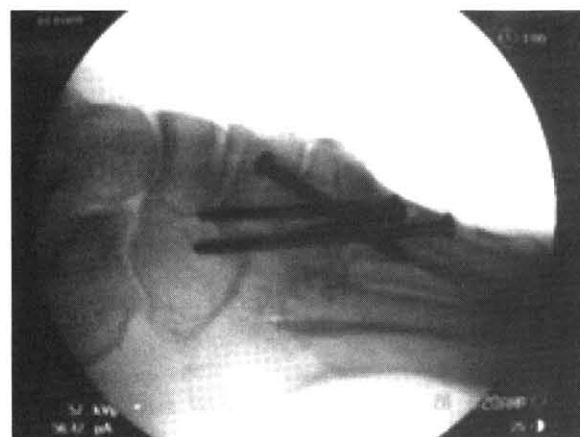**FIGURE 52-52.** Posttraumatic arthritis tarsal-metatarsal (Lisfranc's)—preoperative arthrodesis.



**FIGURE 52-54.** Tarsal-metatarsal arthrodesis (Lisfranc's fusion postoperative).



**FIGURE 52-53.** Posttraumatic arthritis tarsal metatarsal (Lisfranc's)—preoperative arthrodesis.



**FIGURE 52-55.** Intraoperative tarsal metatarsal arthrodesis

## Procedure

The patient is positioned supine for surgery, prepped, and draped above the knee to allow for visualization of the entire lower extremity, and a tourniquet is applied.

A total of four stab incisions are made: Two at the inferior medial and superior medial aspect of the calcaneus, and two at the inferior lateral and superior lateral aspect of the calcaneus. These incisions were connected via subperiosteal dissection and a small gigli saw is inserted. The position of the gigli saw is checked under fluoroscopy and then the osteotomy is performed. It is then fixated with two 7.3 partially threaded cancellous screws.

## Postoperative care

A Jones compressive bandage is applied for two weeks, followed by a nonweightbearing below-the-knee cast for an additional two to four weeks or until clinical and radiographic demonstration of healing occurs. A removable walking cast is used for an additional four weeks.

## Lisfranc's Arthrodesis

### Indications

Osteoarthritis, posttraumatic arthritis, collapsing medial column (tarsal- metatarsal). Typically it is performed in conjunction with lengthening of the posterior muscle group.

### Procedure

The patient is positioned supine for surgery. The patient is prepped and draped above the knee to allow visualization of the alignment of the entire lower extremity and a tourniquet is applied. An incision is made over the proximal first intermetatarsal space and extended proximal to the talar navicular joint. Dissection is carried deep to the periosteum, freeing all soft tissues off the first, second, and third tarsal metatarsal joints, allowing for good exposure. Joint resection is usually performed with a power saw or osteotome and mallet, reduced and temporarily fixated. It is often necessary to have to extend your joint resection laterally in order to mobilize medially and plantarly. Temporary fixation is used and intra-operative fluoroscopy is utilized to examine the joint. Multiple burr holes are made on the medial aspect of the cuneiform and metatarsal, followed by a 3.5 drill guide, a 3.5 drill, a 2.5 guide and a 2.5 drill. Measure and insert a 3.5 self-tapping screw. At the first, second, and third metatarsals multiple burr holes are made and typical AO techniques is used to fixate these joints. A shear-strain-relief graft is then applied to the respective joint.

## Postoperative Care

A Jones compressive bandage is applied for two weeks, followed by a nonweightbearing below-the-knee cast for an additional two to four weeks. A removable walking cast is then used for an additional four weeks, based on clinical and radiographic evaluation.

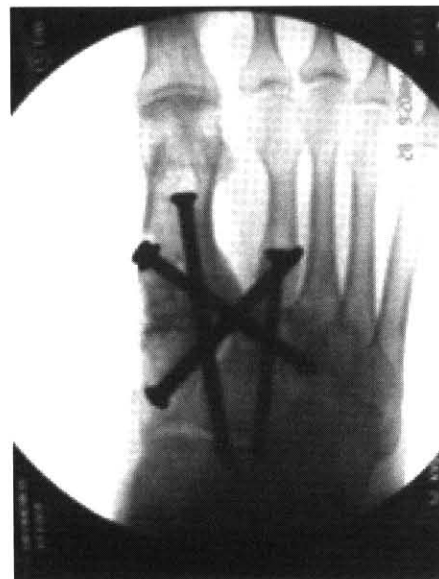## Navicular-Cuneiform Arthrodesis

### Indications

Osteoarthritis, collapsing medial column ("navicular-cuneiform sag"), pes planus. This procedure was originally described by Hoke as a fusion of the navicular to the first and second cuneiforms.<sup>22</sup> Today it usually only involves fusion of the navicular to the medial cuneiform. It is performed in conjunction with lengthening of a tight heel cord and other medial column reconstruction procedures.<sup>13</sup> The navicular-cuneiform joint is a nonessential joint, and fusion has very minimal effect on normal function.

### Procedure

The patient is positioned supine for surgery, prepped, and draped above the knee to allow visualization of the alignment of the entire lower extremity and a tourniquet is applied. An incision is made over the medial cuneiform



**FIGURE 52-56.** Intraoperative view Lisfranc's arthrodesis.



and extended proximal to the talo navicular joint. Dissection is carried deep to the periosteum, freeing all soft tissue off the naviculo-cuneiform joint, allowing for good exposure to the joint. Joint resection is usually performed with a power saw, curette or an osteotome and mallet, reduced, and temporarily fixated. It is often necessary to extend the joint resection laterally into the lesser tarsal bones in order to reduce the navicu-cuneiform joint medially and plantarly. Temporary fixation is used and intra-operative fluoroscopy is utilized to examine the joint. A burr hole is made on the medial aspect of the cuneiform, followed by a 3.5 drill, a 2.5 guide, and a 2.5 drill. A 3.5 self-tapping screw is measured and inserted. At the medial tuberosity of the navicular a 3.5 drill is used in the direction from the tuberosity to the cuneiform. A 2.5 guide and 2.5 drill are used into the cuneiform. A self tapping 3.5 screw is measured and inserted. For a patient with large anatomy a third point of fixation can be employed by inserting another 3.5 screw in the cuneiform into the navicular by placing this screw in a different plane than the previous two screws. A shear-strain relief graft is then applied to the respective joint.

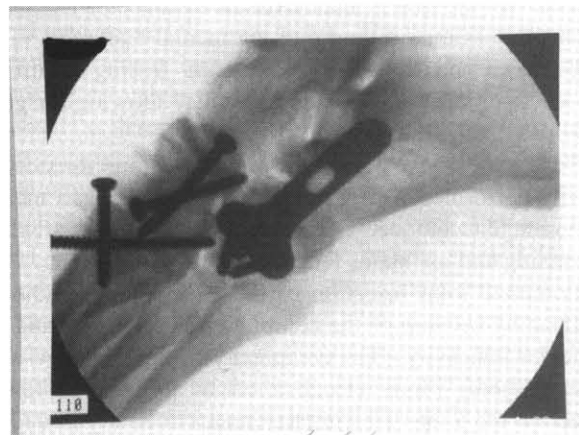
**Postoperative**

A Jones compressive bandage is applied for two weeks, followed by a nonweightbearing below-the-knee cast for an additional two to four weeks. A removable walking cast is then used for an additional four weeks based on clinical and radiographic evaluation.

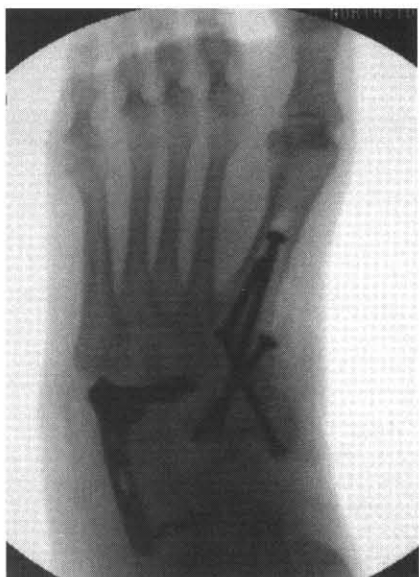**Talar-Navicular Arthrodesis**

**Indications**

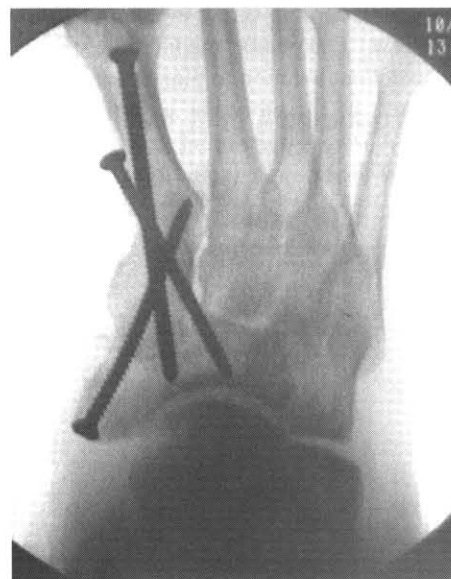Osteoarthritis, rheumatoid arthritis, collapsing medial column (“talar-navicular sag”), pes planus. This procedure is usually performed in conjunction with lengthening of a tight heel cord and other medial column reconstruction



**FIGURE 52-58.** Navicular cuneiform arthrodesis postoperative.



**FIGURE 52-57.** Navicular cuneiform arthrodesis intra-operative.



**FIGURE 52-59.** Navicular cuneiform arthrodesis intra-operative.

procedures and sometimes is a part of a triple arthrodesis.<sup>13</sup> The talar-navicular joint arthrodesis is a very powerful procedure and its effects on the joints in the hind foot and ankle must be clearly understood. A very thorough preoperative evaluation of the hind foot complex needs to be carried out.

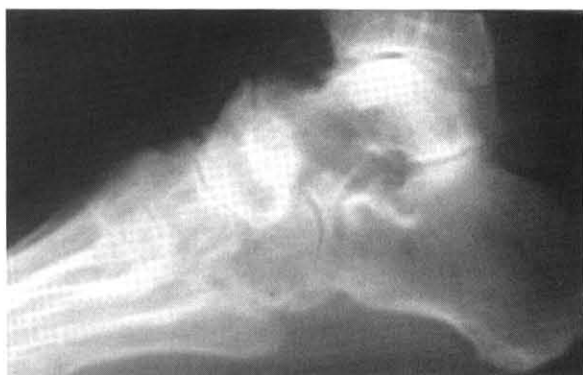### Procedure

The patient is positioned supine for surgery, prepped, and draped above the knee to allow visualization of the alignment of the entire lower extremity, and a tourniquet is applied. An incision is made over the medial cuneiform and extended proximal to the tip of the medial malleolus. Dissection is carried deep to the periosteum, freeing all soft tissue structures off the talus and navicular, allowing for good exposure to the joint.

Depending on the goal of the procedure, joint resection is usually performed with a power saw, osteotome and mallet, or curettage technique. Each individual technique provides shortening and maintains length and/or transposition.

Complete joint resection of the talar navicular joint is challenging because of the complex talar convexity and the navicular concavity. The complexity of the talar navicular or coxa pedis limits visualization of the plantar lateral aspect of the joint. This in turn creates difficulty in obtaining adequate subchondral bone resection, which results in this joint's higher rate of nonunion.

After the talar-navicular joint is manipulated and rotated into a good clinical position, temporary fixation is used and the joint is examined with fluoroscopy. Fixation is achieved with a combination of two or three 3.5 and 4.0 cortical screws or a single cortical screw in combination with a 6.5 cancellous screw. The plantar medial tuberosity of the navicular is an excellent location to place the initial screw, with the dorsal aspect of the navicular a good location for the other screws. A shear-strain-relief graft is inserted into the medial aspect of the talar navicular joint.

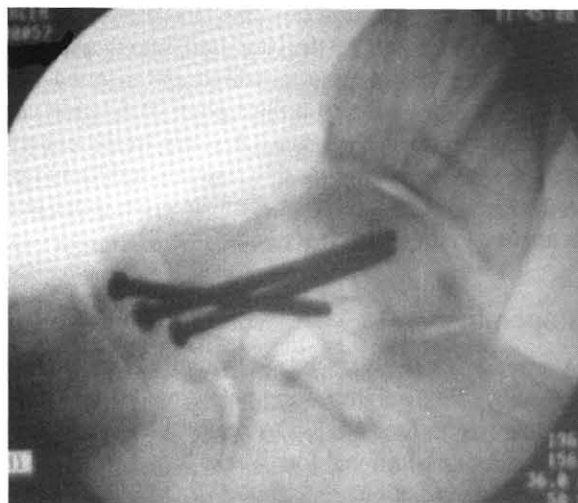


**FIGURE 52-60.** Pre-operative talar-navicular arthrodesis.

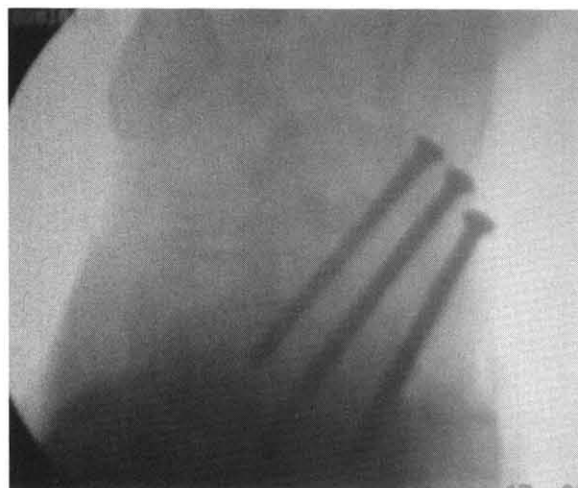
Good fixation is mandatory specifically with this joint. The difficulty of joint resection, the degree of motion, stress at this joint and the complexity of fixation make this joint relatively difficult to fuse.

### Postoperative care

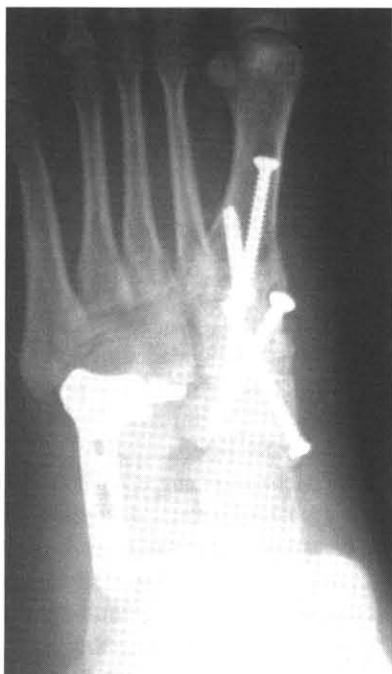A Jones compressive bandage is applied for two weeks, followed by a non weightbearing below the knee cast for an additional two to four weeks. A removable walking cast is used for an additional four weeks based on clinical and radiographic evaluation.



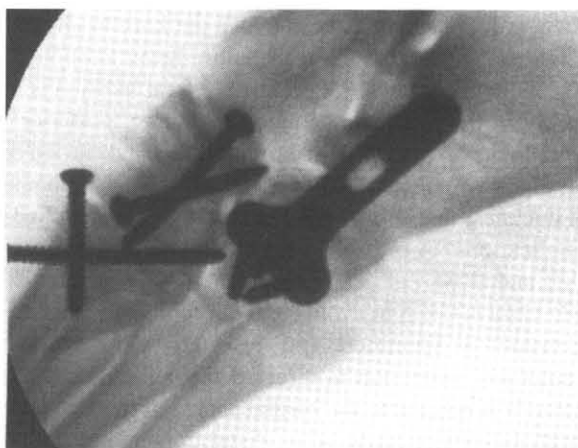
**FIGURE 52-61.** Intra-operative talar-navicular arthrodesis.



**FIGURE 52-62.** Intra-operative talar-navicular arthrodesis.



**FIGURE 52-63.** Calcaneal cuboid arthrodesis postoperative.



**FIGURE 52-64.** Calcaneal cuboid arthrodesis intraoperative.

### Calcaneal Cuboid Distraction Arthrodesis

#### Indications

Flatfoot reconstruction associated with lateral rotation of the foot and a short lateral column.

#### Procedure

The patient is placed in the lateral position with the affected side facing up, allowing for harvest of the bone from the iliac crest and easy access to the lateral side of the foot. The patient is prepped and draped above the knee to allow visualization of the alignment of the entire lower extremity, and a tourniquet is applied. This procedure is usually performed in conjunction with lengthening of a tight heel cord and other medial column reconstruction procedures. A longitudinal incision is made over the calcaneal cuboid joint approximately 6 cm in length dorsal to the peroneal tendons and the sural nerve. The incision is deepened and the extensor brevis muscle belly is reflected dorsal, exposing the calcaneal-cuboid joint. The joint surfaces are resected (as described earlier) and a distractor is used to distract the joint gently. As this occurs, reduction of the valgus anatomy and restoration of an anatomical arch should be visualized. A tricortical cancellous graft approximately 1.0–1.2 cm (varying with on each patient size) is inserted tamped with a bone tamp. The distractor is removed, intraoperative X-rays are taken, and clinical evaluation is performed. A T-shaped or H-shaped plate are applied. Final intraoperative anterior-posterior, lateral, and calcaneal-axial X-rays are taken and typical wound closure is performed.

#### Postoperative care

A Jones compression bandage is applied for two weeks, followed by a nonweightbearing below-the-knee cast for an additional six to eight weeks. A removable walking cast is used for an additional four weeks based on clinical and radiographic evaluation.

### Subtalar Joint Arthrodesis

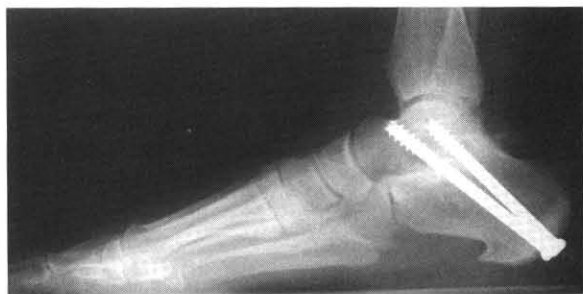#### Indications

Subtalar joint arthrodesis is most commonly indicated for intra-articular degenerative joint disease between the talus and calcaneus.<sup>10</sup> This degenerative joint disease is usually secondary to calcaneal fracture, osteochondral fracture of the talus, calcaneus, subtalar joint dislocation, fracture of the lateral process of the talus, malalignment, neuromuscular diseases, posterior tibial tendon dysfunction, and arthritides that can yield a significant amount of arthrosis.<sup>10</sup> This procedure is usually performed in conjunction with lengthening of a tight heel cord.

#### Procedure

The patient is positioned supine for surgery, prepped, and draped above the knee to allow visualization of the

alignment of the entire lower extremity, and a tourniquet is applied. The traditional Ollier incision placement is made from the peroneal tendons just inferior to the distal tip of the fibula over the subtalar joint, with a lazy curve extending to the calcaneal-cuboid joint. Dissection is carried deep to the subtalar joint, with care being taken not to violate the sural nerve and the peroneal tendons. The dissection is carried through the fascia and the extensor brevis muscle belly is lifted superiorly to allow for good visualization of the subtalar joint. Depending on the goal of the procedure, joint resection is usually performed with a power saw, osteotome and mallet, or curettage technique. Each individual technique provides shortening, allows for angular correction, or maintains height, respectively. The joint is realigned in a neutral anatomical position and temporarily fixated. Fluoroscopy is used to evaluate the lateral, AP, calcaneal axial, and ankle views. Once good anatomical alignment is identified, fixation is performed with two 7.3 cannulated cancellous screws. The first screw is inserted from the inferior heel to the body of the talus, and the second screw is inserted from the inferior heel to the talar neck. The screws are inserted in this direction to obtain better compression as the bone in the talus is much more dense. An alternative way of inserting the screws is from the neck of the talus aiming inferior into the body of the calcaneus. Either 6.5 screws or a larger screw in combination with a smaller screw also can be employed. The surgeon must be certain the heel is not in varus and in neutral to slight valgus. Intra-operative calcaneal axial, ankle, and lateral foot X-rays are taken. The axial view verifies that the calcaneus is not in a varus position, the ankle view ensures the screws are not penetrating the medial, lateral, or talar dome, and the lateral view ensures the restoration of normal anatomical alignment. Saltzman or long leg-calcaneal views are taken to evaluate the leg to foot alignment. Typical wound closure is performed and a drain is inserted.



**FIGURE 52-65.** Subtalar arthrodesis postoperative.

## Postoperative care

A Jones compressive bandage is applied for two weeks, followed by a nonweightbearing below-the-knee cast for an additional two weeks. A removable walking cast is used for an additional four weeks based on clinical and radiographic evaluation.

## Subtalar Joint Distraction Arthrodesis

### Indications

Most arthritides of the subtalar joint secondary to calcaneal fractures are corrected with an *in situ* arthrodesis. The subtalar joint arthrodesis is utilized for the postcalcaneal fracture that demonstrates osteoarthritis of the subtalar joint, a decrease in talar declination angle, anterior ankle impingement, maligned calcaneal varus, decreased height of the talar-calcaneal complex, widening of the heel due to lateral wall expansion, impingement of the peroneal tendons on the tip of the fibula, and medial or lateral translation in the heel.<sup>10</sup>

### Procedure

The patient is placed in an anterior lateral position. This allows for posterior lateral exposure of the subtalar joint and for access for harvesting of tricortical iliac crest graft. The patient is prepped and draped above the knee to allow visualization of the alignment of the entire lower extremity, and a tourniquet is applied. A posterior lateral incision is made lateral to the Achilles tendon beginning posterior and approximately 6 cm proximal to the fibula and carried down to the posterior lateral calcaneus. The incision should be full thickness and subperiosteal in order to avoid wound flap complications. A full-thickness flap is created and exposure to the lateral wall of the calcaneus and subtalar joint is created. Care is taken to avoid sural nerve injury. Lateral wall expansion is identified and resected with the use of osteotomes. Attention is directed medially and a femoral distractor is applied to the medial aspect of the foot and leg. A stab incision is made in the distal tibia and in the posterior-superior calcaneus, allowing for the application of the femoral distractor and distraction of the subtalar joint. This medial placement prevents lateral tilting of the subtalar joint while distracting. Attention is directed back to the lateral superior aspect of the subtalar joint and debridement of the irregular cartilage and subchondral bone of the talus and calcaneus is performed. A laminar spreader is inserted laterally and medial distraction is performed, facilitating distraction and excellent exposure of the posterior lateral subtalar joint. Position is confirmed with intra-operative X-ray. The tricortical graft is inserted and placed slightly medially

to prevent tilting into varus. The laminar spreader and the medial distractor are released and intra-operative X-ray is viewed to verify proper position. If the calcaneus maintains in a varus position, a calcaneal wedge osteotomy may be performed to properly realign it. Two 7.3 fully threaded screws are inserted in the same fashion as described earlier. Fully threaded screws are utilized to maintain position; compression is unnecessary. Intra-operative calcaneal axial, ankle, and lateral foot X-rays are taken. The axial view verifies that the calcaneus is no longer in a varus position, the ankle view ensures that screws are not penetrating the medial, lateral, or talar dome and the lateral, view ensures the restoration of normal anatomical alignment. Typical wound closure is performed and a drain is inserted.

**Postoperative care**

A Jones compressive bandage is applied for two weeks, followed by a nonweightbearing below-the-knee cast for an additional six to eight weeks or until clinical and radiographic demonstration of healing. A removable walking cast is used for an additional four weeks.

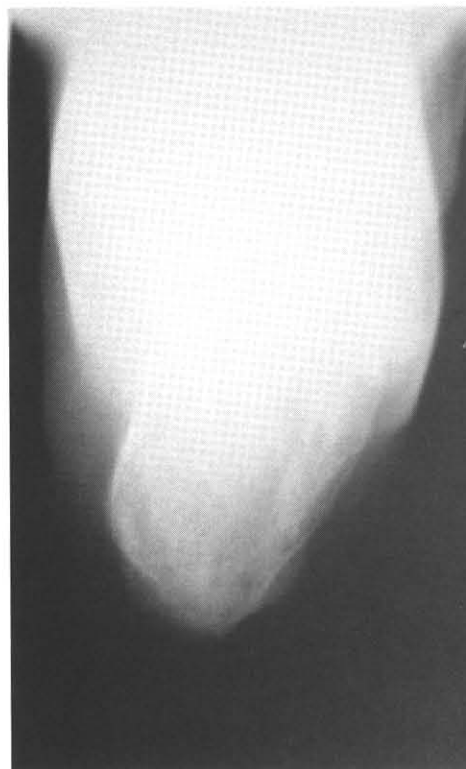**Triple Arthrodesis**

**Indications**

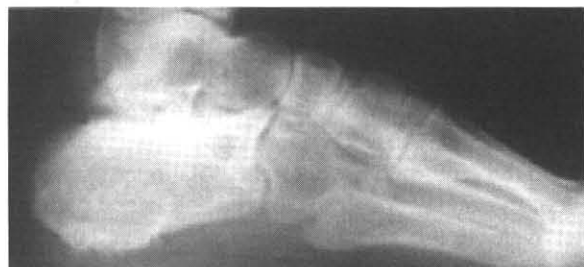Painful recalcitrant deformed feet, unstable rearfoot joints, malignment with secondary arthritis, advanced posterior tibial tendon dysfunction, complex neuromuscular disease, posttraumatic arthrosis, untreated clubfoot, complication of infection.<sup>10</sup>

**Procedure**

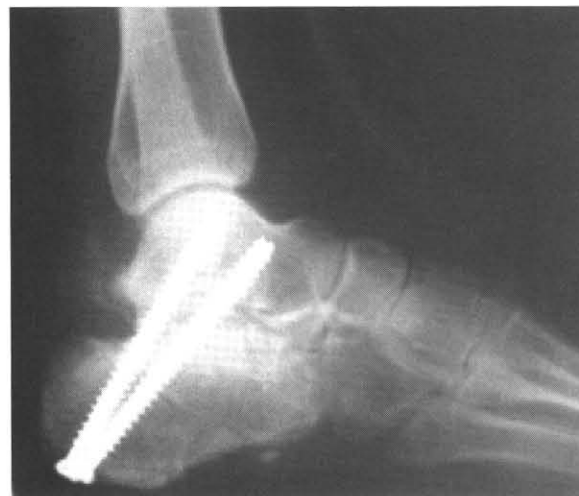The patient is positioned supine with a lateral tilt for the surgery, prepped, and draped above the knee to allow visualization of the alignment of the entire lower extremity, and a



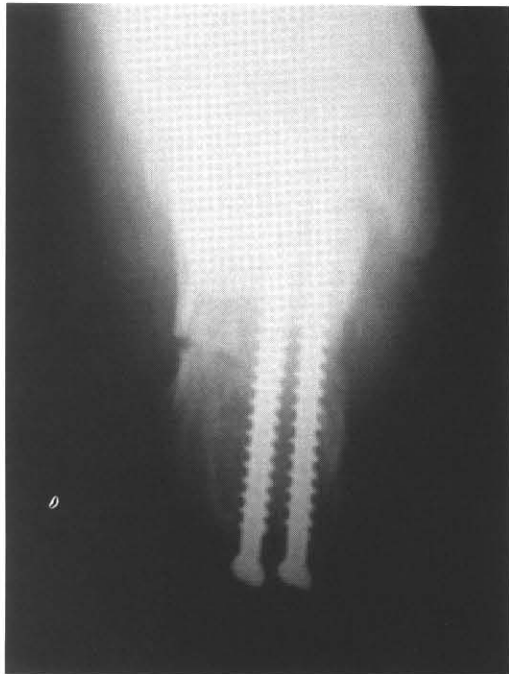**FIGURE 52-67.** Posttraumatic subtalar joint arthritis (postcalcaneal fracture) preoperative. Note the calcaneal varus and lateral wall exostosis.



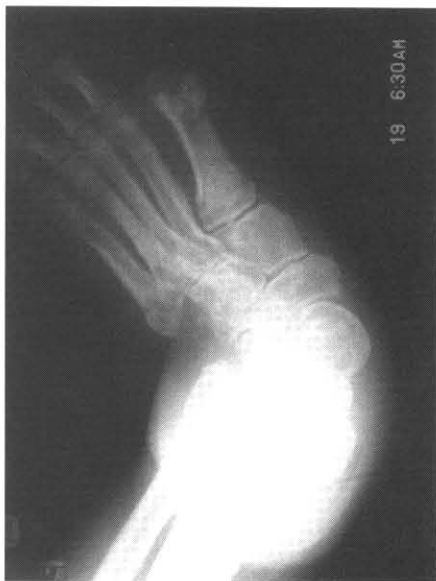**FIGURE 52-66.** Posttraumatic subtalar arthritis (postcalcaneal fracture) preoperative distal.



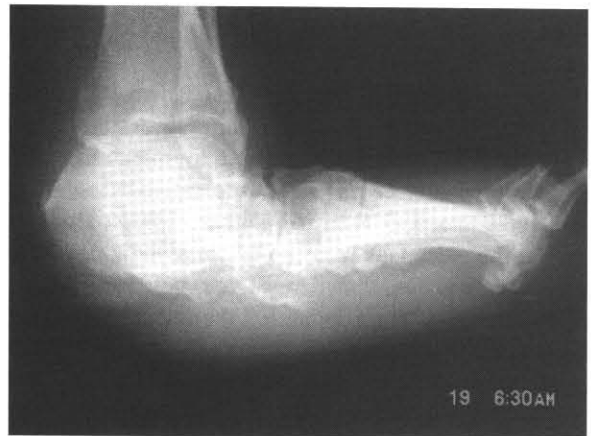**FIGURE 52-68.** Postoperative bone block distraction subtalar arthrodesis for posttraumatic calcaneal fracture.



**FIGURE 52-69.** Bone block distraction subtalar arthrodesis postoperative (note the correction).

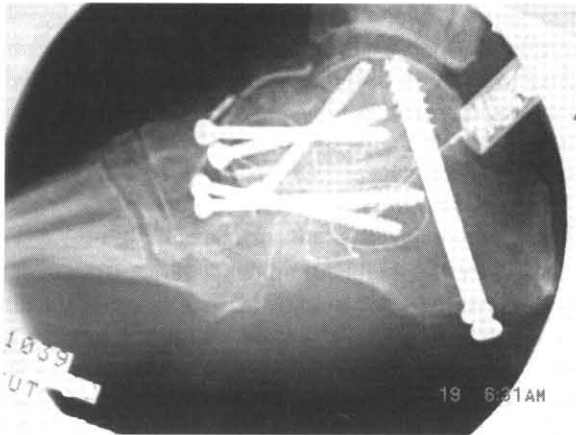


**FIGURE 52-70.** Triple arthrodesis preoperative in a diabetic patient.

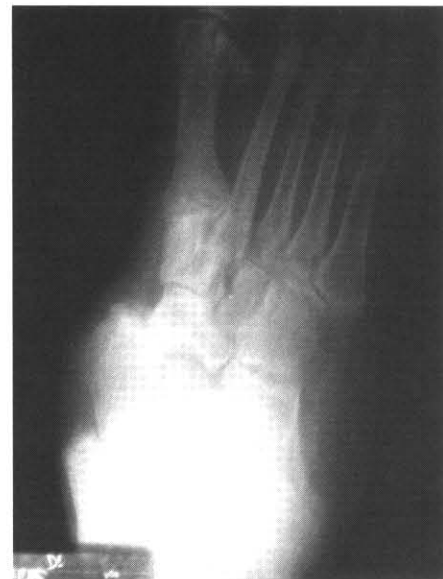

**FIGURE 52-71.** Triple arthrodesis preoperative.

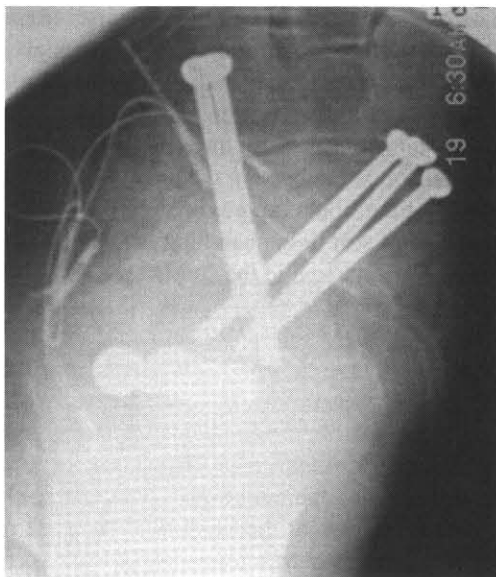
a tourniquet is applied. This procedure is usually performed in conjunction with lengthening of a tight heel cord. This procedure is performed with two incisions: the first begins at the medial malleolus and runs to the base of the first metatarsal, and the second is an Ollier skin incision. Careful dissection is continued deep, preserving the neurovascular structures, retraction of tendons and exposing the talar-navicular, talar-calcaneal, and calcaneal-cuboid joints. Joint resection usually begins at the midtarsal joint, followed by the subtalar joint. Joint resection can be performed in one of three ways: curettage, (my preference), joint resection (power saw), and fish scaling (osteotome and mallet). A power saw is used for planal resection and large angular correction, and fish scaling and curettage help maintain anatomical configuration and possess little shortening. Following subchondral bone dissection, the talus is translated back on the posterior facet of the calcaneus. Alignment of the hindfoot to the leg is examined. After achieving good anatomic position, the subtalar joint is temporarily fixated with two 2.8 guide wires from the posterior calcaneus into the body and neck of the talus. Next, attention is directed to the midtarsal joint, where the talar navicular joint is rotated, adducted, and temporarily fixated relative to the rearfoot and leg, restoring normal anatomical configuration. The calcaneal-cuboid joint is reduced and temporarily fixated. All three joints are evaluated under fluoroscopy. The subtalar joint is fixated with two 7.3 partially threaded cancellous screws. An ankle fluoroscopy view is performed to be sure the screws do not enter the tibial-talar joint or the gutters of the ankle. A calcaneal-axial and lateral picture is viewed to ensure that calcaneus is not in varus and the talar-calcaneal joint is well aligned. The first screw (a 4.5, 4.0, or 3.5 cortical screw) for the talar-navicular joint runs from the medial tubercle of the navicular into the head,



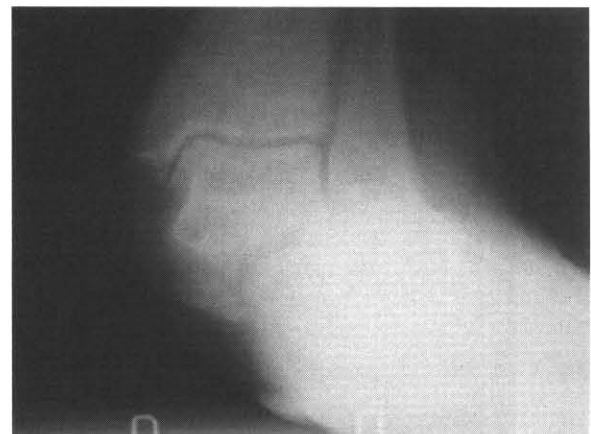
**FIGURE 52-72.** Triple arthrodesis intra-operative view.



**FIGURE 52-74.** Triple arthrodesis preoperative view.



**FIGURE 52-73.** Triple arthrodesis intra-operative view.



**FIGURE 52-75.** Triple arthrodesis preoperative view.

neck, and body of the talus. One or two burr holes are made in the dorsal and lateral navicular. A glide hole is performed in the respective notches, followed by standard AO technique. The calcaneal-cuboid joint is fixed with either one or two large cancellous screws entering the calcaneus from posterior running along the lateral column into the cuboid or two 3.5 or 4.0 cortical screws. Burr holes are made in the calcaneus and cuboid, followed by the typical AO technique.

### Postoperative care

A Jones compressive bandage is applied for two weeks, followed by a nonweightbearing below-the-knee cast for an additional three to six weeks. A removable walking cast is used for an additional four weeks based on clinical and radiographic evaluation.

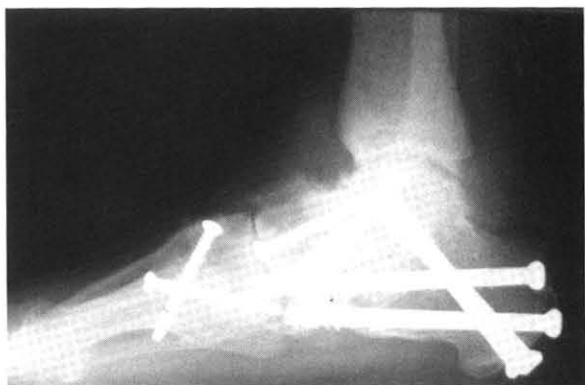

FIGURE 52-76. Triple arthrodesis postoperative view.

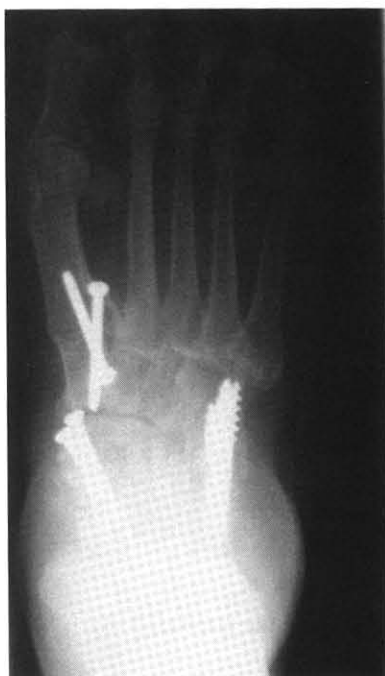

FIGURE 52-77. Postoperative triple arthrodesis view.

### Ankle Arthrodesis

#### Indications

Ankle joint arthrodesis is most commonly indicated for intra-articular degenerative joint disease between the tibia

and talus. This degenerative joint disease is usually secondary to ankle fracture, pilon fracture, osteochondral fracture of the talus or tibia, ankle joint dislocation, malalignment, posttraumatic sepsis, neuromuscular diseases, recurrent sprains with ankle instability, posterior tibial tendon dysfunction, and arthritides that can yield a significant amount of arthrosis.<sup>10</sup>

#### Procedure

The patient is positioned supine for surgery, prepped, and draped above the knee to allow visualization of the alignment of the entire lower extremity, and a tourniquet is applied. An anterior incision is made medial to the anterior tibial tendon beginning at the distal tibia and extending to the talar neck. Dissection is carried deep, retracting the neurovascular bundle and allowing for excellent exposure to the ankle joint. Tremendous care of soft tissue handling is mandatory. All articular surfaces and osteophytes are resected from the anterior tibial-talar joint and the medial and lateral aspect of the talus. This is accomplished with the use of osteotomes, curettes, and rongeurs. Maintaining normal anatomical configuration should be a high priority while debriding. If an angular deformity is present, then wedge resections with a power saw may be warranted. Attention is then directed to the posterior lateral fibula, where an incision is made from the distal aspect of the fibula to the tip of the fibula (approximately 8–10 cm). Again, tremendous care of soft tissue handling is mandatory. Caution should be taken to avoid the sural nerve. The incision is deepened to the bone, the peroneal tendons are retracted posteriorly, and all soft tissue attachments, including the inferior tibial-fibular ligaments, are freed from the distal fibula. A fibular osteotomy is made and all soft tissue except the calcaneal fibular ligament is freed, allowing the distal portion of the fibula to be flapped down to provide excellent exposure to the lateral and posterior ankle joint. The remaining sections of the tibial-talar joint are resected utilizing osteotomes, curettes, rongeurs. The joint is reduced into anatomical alignment (neutral to slight valgus) and temporary fixation is achieved using 2.8 guide wires. Intraoperative fluoroscopy is used to confirm alignment and temporary fixation. The talus should be displaced as far posterior as possible, allowing for better biomechanical advantage and less stress to the midfoot. Maintaining the deep deltoid ligament is very important for regarding stability and blood supply to the talus. The first screw is a 7.3 cannulated screw placed from the posterior medial malleolus in an inferior anterior direction through the body, of the talus and into the head and neck. This screw is thrown first to provide great leverage and to pull the talus posterior relative to the tibia. Two 7.3 screws are then inserted from the distal anterior tibia into the talar body, being sure not to



enter the subtalar joint. The medial aspect of the distal fibula and the lateral aspect of the talus and tibia are debrided, preparing the bones for fusion. Three 4.5 cortical screws are inserted from the distal lateral fibula (two into the tibia and one into the talus) as an onlay graft providing excellent additional stability and a more clinically normal-appearing ankle. All bony defects are packed with a shear-strain-relief graft, a drain is utilized, and closure is performed. Intraoperative fluoroscopy is used to confirm anatomical alignment, posterior placement of the talus relative to the tibia, and that fixation does not enter into the subtalar joint.

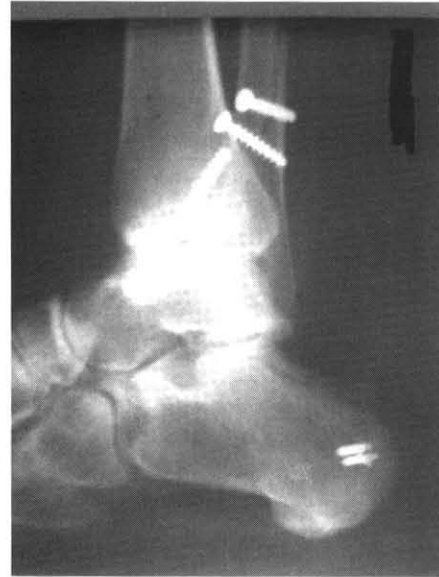**Postoperative care**

A Jones compressive bandage is applied for two weeks, followed by a nonweightbearing below-the-knee cast for an additional two to four weeks. A removable walking cast is used for an additional four weeks based on clinical and radiographic evaluation.

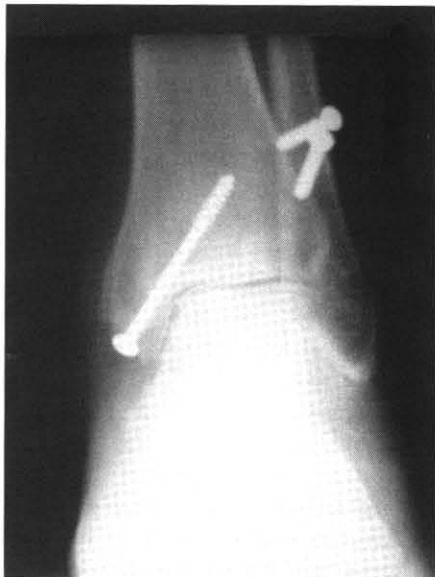**Charcot Reconstruction: Lisfranc’s Joint**

**Indications**

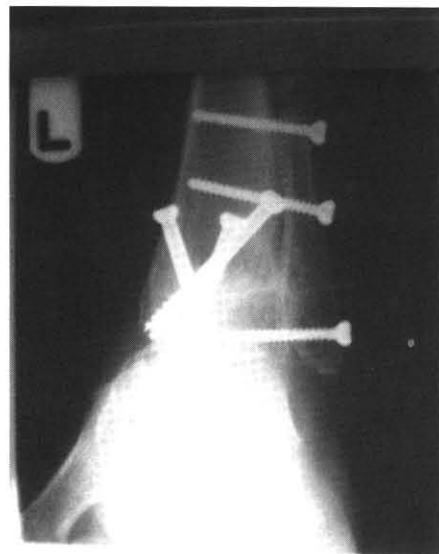
Indications for surgical treatment include chronic ulcers associated with bony deformities or contractures, unstable



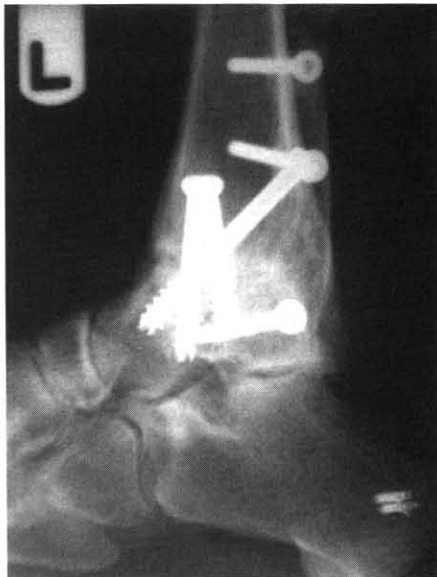**FIGURE 52-79.** Posttraumatic ankle arthritis—preoperative ankle arthrodesis.



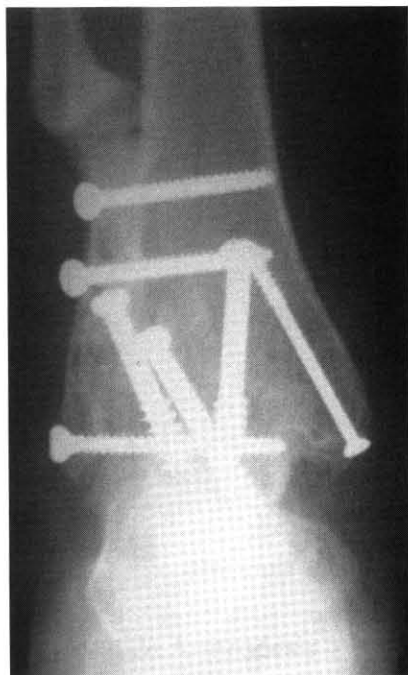
**FIGURE 52-78.** Posttraumatic ankle arthritis—preoperative ankle arthrodesis.



**FIGURE 52-80.** Ankle arthrodesis postoperative.



**FIGURE 52-81.** Ankle arthrodesis postoperative.



**FIGURE 52-82.** Postoperative ankle arthrodesis.

Lisfranc's joint of the foot that are not shoeable or braceable, recurrent infected ulcers with bony prominences, and acute displaced fractures in neuropathic patients with adequate circulation.<sup>23,24</sup> Gross instability at the tarsometatarsal articulation leads to characteristic symptomatic medial and plantar bony prominences, which may lead to ulceration and infection, often resulting in amputation of a limb.<sup>25</sup> Osteotomy alone does not address the biomechanical instability and thus does not provide long-term benefit.<sup>26</sup> Meanwhile, amputation puts the patient at further risk for an additional amputation of the contralateral limb.<sup>27</sup>

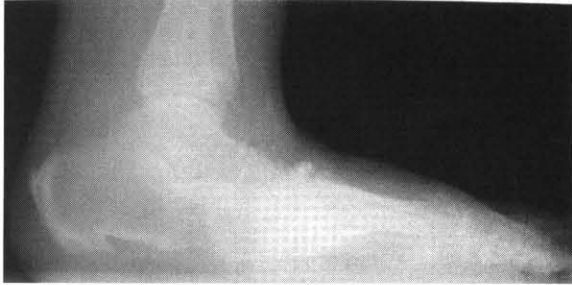
### Procedure

The patient is positioned supine for surgery, prepped, and draped above the knee to allow visualization of the alignment of the entire lower extremity, and a tourniquet is applied. Attention is then directed to the posterior muscle group, where either a tendo-Achilles lengthening or a gastrocnemius recession is performed based on the clinical pathology.

Attention is then directed to the plantar medial aspect of the foot. An approximately 9-cm curvilinear incision is made beginning at the talonavicular joint and extending to the distal one-third of the first metatarsal shaft. The incision is deepened via sharp and blunt dissection down to the first metatarsal, medial cuneiform, and navicular. A full-thickness tissue flap is then reflected off of all tarsometatarsal joints. Attention is directed to the base of Lisfranc's articulation. An osteotome is used to remove an approximately 1-cm block of necrotic bone across Lisfranc's joint, down to good, healthy bleeding bone. If necessary, a second incision is made on the lateral aspect of the foot between the fourth and fifth metatarsals longitudinally and extending proximal to the cuboid. This incision is deepened down to the base of the metatarsals and cuboid. All necrotic bone from lateral to medial is removed, completing the resection of Charcot bone across Lisfranc's joint. The Lisfranc's joint is adducted, rotated and held into a plantarflexed position using two 0.062 K-wires for temporary fixation. At this time good anatomical alignment should be assessed in the sagittal and transverse plane. Next, a 3.5-mm reconstruction plate is eccentrically loaded and applied to the plantar aspect of the first metatarsal, medial cuneiform, and navicular. One 3.5-cm cortical screw is placed outside of the plate from the first metatarsal into the middle cuneiform. A second cortical screw is inserted outside of the plate from the medial cuneiform into the second metatarsal base. No fixation is used on the third, fourth, or fifth metatarsals. Allogenic cancellous bone chips are mixed with any viable autogenous cancellous bone and used to fill any void or space at the arthrodesis site.

### Postoperative

A Jones compressive bandage is applied for two weeks, followed by a nonweightbearing below-the-knee cast for an additional six to eight weeks. A removable walking cast is used for an additional four to twelve weeks based on clinical and radiographic evaluation.

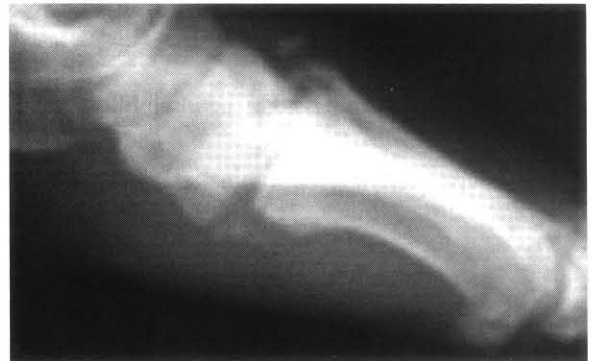

**FIGURE 52-83.** Midfoot preoperative Charcot reconstruction.

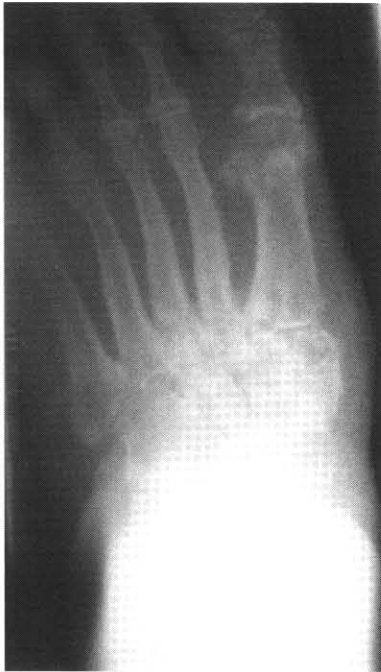### Charcot Reconstruction: Midfoot

#### Indications

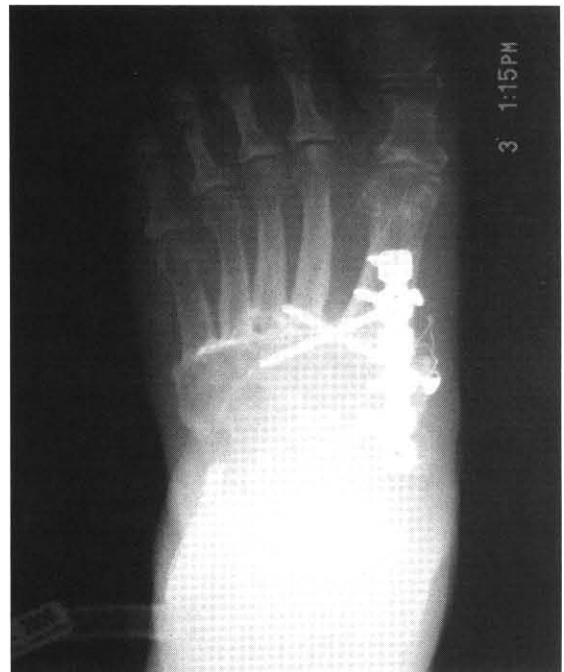Indications for surgical treatment include chronic ulcers associated with bony deformities or contractures, unstable



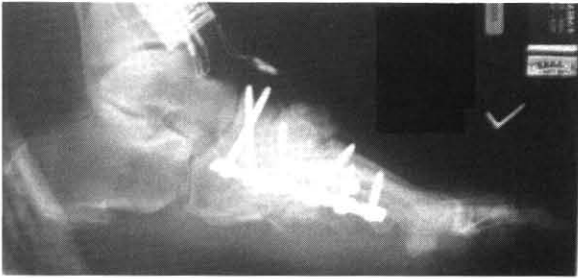
**FIGURE 52-85.** Charcot reconstruction midfoot preoperative.



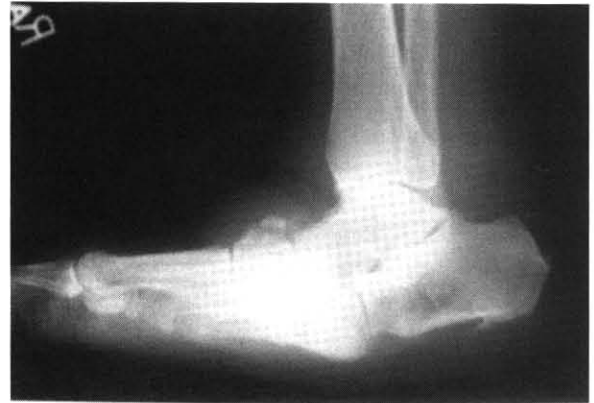**FIGURE 52-84.** Charcot reconstruction midfoot preoperative.



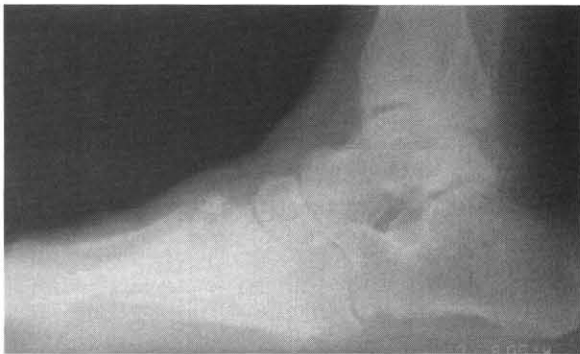**FIGURE 52-86.** Charcot reconstruction midfoot postoperative.



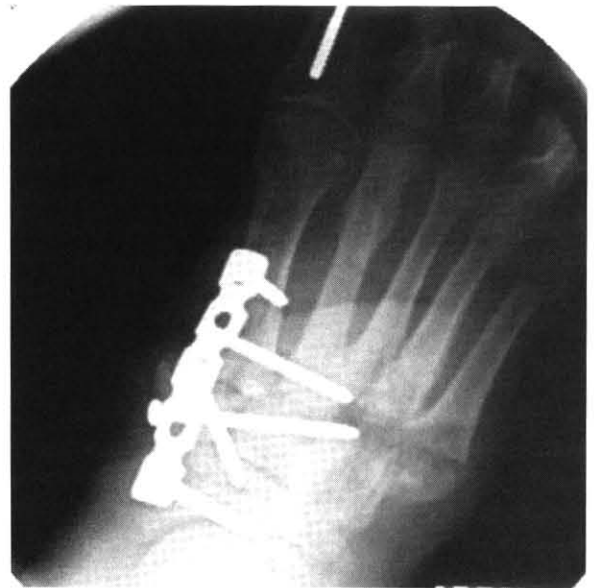**FIGURE 52-87.** Charcot reconstruction midfoot postoperative.



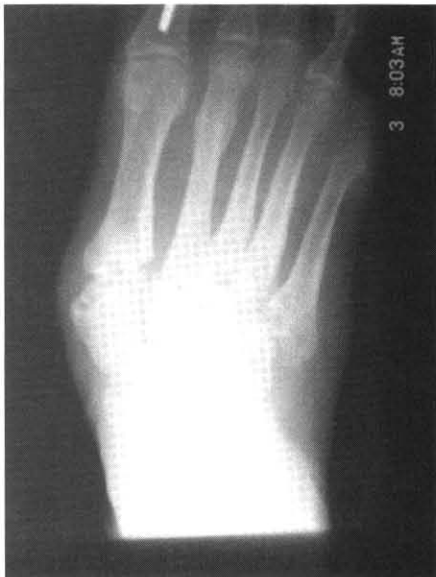**FIGURE 52-90.** Charcot reconstruction preoperative midfoot.



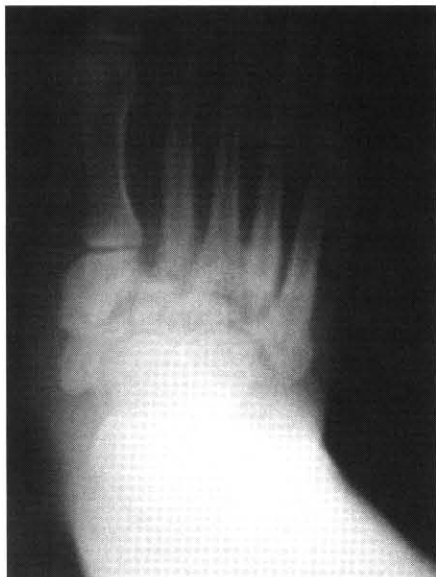**FIGURE 52-88.** Charcot reconstruction preoperative midfoot.



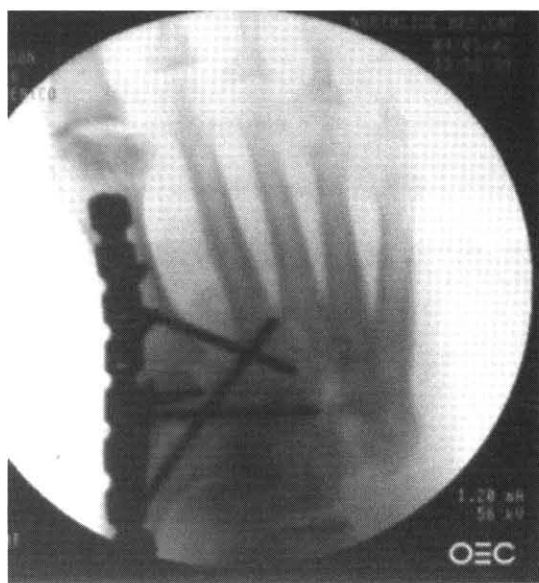**FIGURE 52-91.** Charcot reconstruction postoperative midfoot.



**FIGURE 52-89.** Charcot reconstruction preoperative midfoot.



**FIGURE 52-92.** Charcot reconstruction preoperative midfoot.



**FIGURE 52-93.** Charcot reconstruction postoperative midfoot.

joints of the midfoot that are not shoeable or braceable, recurrent infected ulcers with bony prominences, and acute displaced fractures in neuropathic patients with adequate circulation.<sup>23,24</sup> Gross instability at the midfoot leads to characteristic symptomatic medial and plantar bony prominences, which may lead to ulceration and infection, often resulting in amputation of a limb.<sup>25</sup> Osteotomy alone does not address the biomechanical instability and thus does not provide long-term benefit.<sup>26</sup> Meanwhile, amputation puts the patient at further risk for an additional amputation of the contralateral limb.<sup>27</sup>

### Procedure

The patient is positioned supine for surgery, prepped, and draped above the knee to allow visualization of the alignment of the entire lower extremity, and a tourniquet is applied. Attention is then directed to the posterior muscle group, where either a tendo-Achilles lengthening or a gastrocnemius recession is performed based on the clinical pathology. Attention is then directed to the plantar medial aspect of the foot. An incision is made beginning at the talonavicular joint and extending to the distal one-third of the first metatarsal shaft. The incision is deepened via sharp and blunt dissection down to the first metatarsal, medial cuneiform, and navicular. Attention is directed to the midfoot articulations. An osteotome and rongeur are used to remove all necrotic bone down to good, healthy bleeding bone, essentially shortening the foot. If necessary, a second incision is made on the lateral aspect of the foot. This incision is deepened down to the lateral aspect of the midfoot. All necrotic bone from lateral to medial is removed, completing the resection of Charcot bone across the midfoot. The midfoot is adducted, rotated, and held into a plantarflexed position using temporary fixation. At this time good anatomical alignment should be assessed in the sagittal and transverse plane. Next the temporary fixation is removed and a 3.2 drill is used to drill from the open area of the midfoot to posterior and exiting the posterior talus. The same drill then drills antegrade from the same posterior exit portal of the talus (following Meary's angle) into the first metatarsal shaft. Next a 6.5 bolt is inserted from the posterior portal of the talus into the first metatarsal shaft. A second bolt is then inserted from the posterior calcaneus down the lateral column and into the fourth metatarsal base. A subtalar arthrodesis may also be performed. Allogenic cancellous bone chips are mixed with any viable autogenous cancellous bone and used to fill any void or space at the arthrodesis site.

### Postoperative care

A Jones compressive bandage is applied for two weeks, followed by a nonweightbearing below-the-knee cast for an additional six to eight weeks. A removable walking cast is used for an additional four to twelve weeks based on clinical and radiographic evaluation.

### Charcot Reconstruction—Intramedullary Nail—Hindfoot and Ankle

#### Indications

Very few options exist for patients with complex hind-foot pathology. Functional braces for deformities secondary

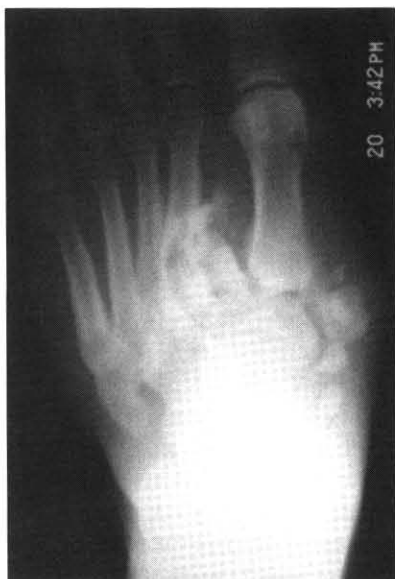

FIGURE 52-94. Charcot midfoot preoperative.

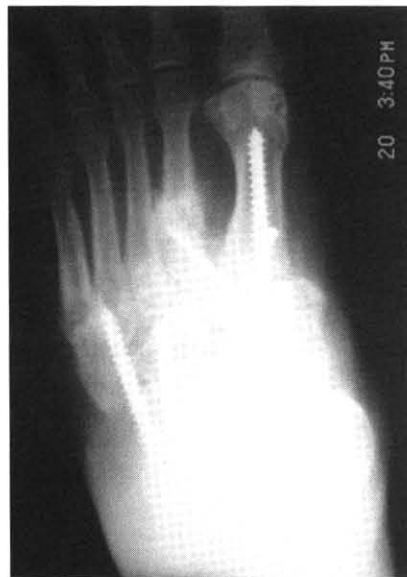

FIGURE 52-96. Charcot midfoot postoperative.

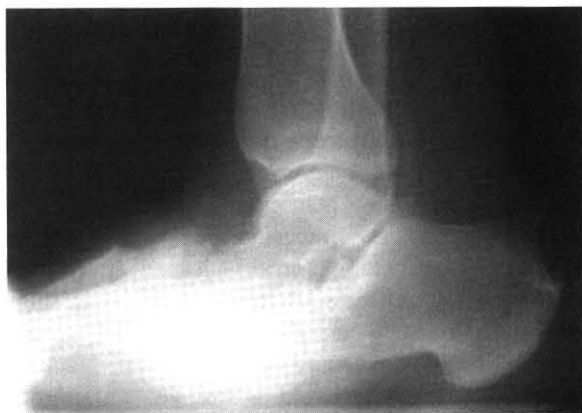

FIGURE 52-95. Charcot midfoot preoperative.

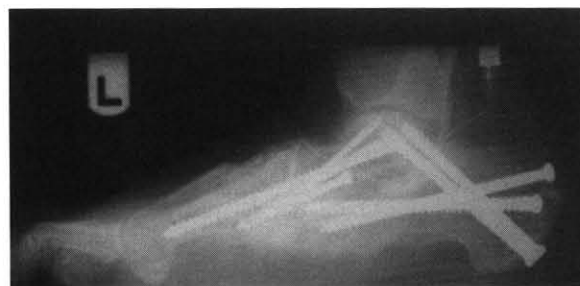
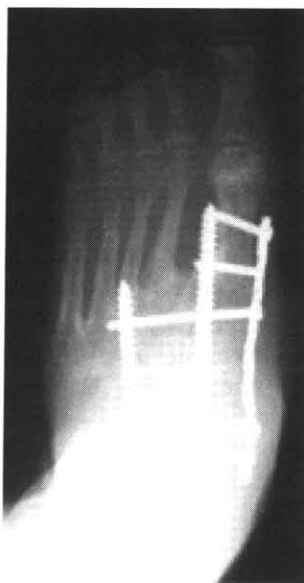
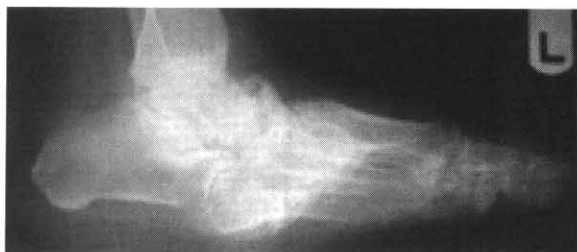
FIGURE 52-97. Charcot midfoot postoperative.



**FIGURE 52-98.** Charcot midfoot postoperative.



**FIGURE 52-99.** Charcot midfoot preoperative.



**FIGURE 52-100.** Charcot midfoot postoperative.

to neuropathic osteoarthropathy and failed hindfoot fusions are often utilized. However, proper bracing of the extremity and limb preservation is often difficult due to soft tissue breakdown and bone infection, especially in the diabetic patient. Surgical reconstruction, realigning the ankle and foot with the long axis of the tibia, may allow the patient to function safely with a brace or accommodative shoe assistance.

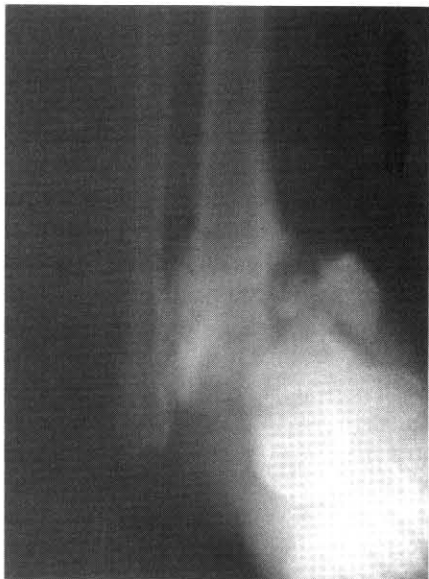Proper patient selection and education are paramount to successful salvage procedure. The patient's compliance, health status, and overall quality-of-life issues must be considered when suggesting surgical reconstruction. Hindfoot salvage procedures are performed for the relief of pain, realignment of the foot and ankle with the lower leg in order to provide a more functional limb, and elimination of soft tissue compromise.

Reconstruction of the hindfoot using an intermedullary nail system has been proven to be a viable option for salvaging a nonbraceable extremity in patients with neuropathic osteoarthropathy of the ankle and providing a functional limb in failed primary hindfoot fusions.<sup>28</sup>

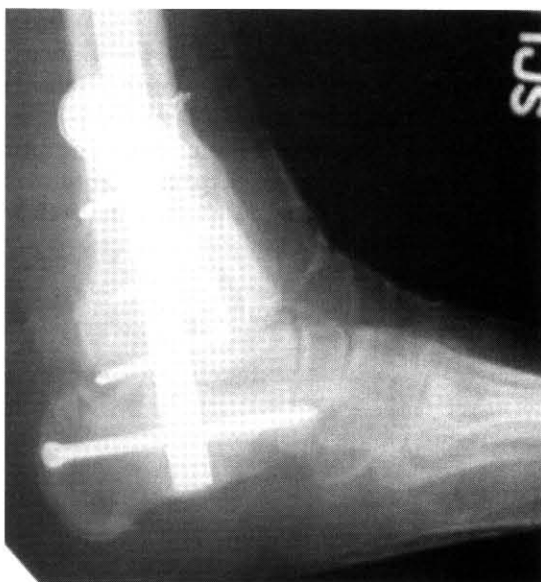## Procedure

The patient is positioned supine for surgery, prepped, and draped above the knee to allow visualization of the alignment of the entire lower extremity, and a tourniquet is applied. In cases where previous fixation had been attempted, the hardware is removed. A lateral incision is made overlying the malleoli. The lateral malleolus is resected 8–10 cm above the level of the ankle joint line in an oblique fashion and reflected inferiorly. The articular surface of the tibia is removed perpendicular to the long axis. Based on the degree of destruction and collapse of the talar body it is then determined whether a partial or complete talectomy should be performed. If the fusion site is jeopardized by a necrotic talus, the bone is removed.

Complete talectomy is performed due to the severe destruction present to the talus, and a partial talectomy (body) is performed for a less severe destructive talus in order to properly align the tibia, talus, and calcaneus. A complete talectomy is performed with fusion of the tibia to the calcaneus. After appropriate dissection, the joints are placed in the plantargrade position, usually 0–5° of valgus and 5–10° of external rotation, and the ankle joint is positioned at 90° to the long axis of the leg. Temporary fixation is obtained with the use of large Steinmann pins.



**FIGURE 52-101.** Intramedullary nail hindfoot and ankle preoperative.



**FIGURE 52-102.** Intramedullary, nail hindfoot and ankle postoperative partial talectomy.

Attention is then directed to the plantar surface of the heel. Blunt dissection is carried out to the plane surface of the calcaneus. Under fluoroscopic guidance, a guide wire is then driven through the calcaneus and into the medullary shaft of the tibia. It must be centrally located within the hindfoot and tibia to avoid malalignment and stress risers. Medullary reaming is performed to allow for ease of nail insertion and a more secure fit. The corresponding proper size nail is driven through the canal and placed flush with the plantar surface of the calcaneus. Using the supplied jig, transfixation screws are placed into the calcaneus (depending what nail is used, the screws can be placed in a posterior to anterior approach or a lateral to medial approach), talus (when a partial talectomy is performed), and tibia using a medial approach to lessen the potential for soft tissue injury. Allogenic cancellous bone chips are mixed with any viable autogenous cancellous bone and used to fill any void or space at the arthrodesis site. Placement of the nail and screws is confirmed via fluoroscopy prior to wound closure.

### Postoperative care

A Jones compression dressing is applied for two weeks. Patients are kept nonweightbearing in a below-the-knee cast for approximately six to eight weeks or until radiographic and clinical healing is acknowledged. The patients are placed in a walking cast or CAM walker for an additional two to three months.

## FRACTURES

### Fifth Metatarsal Fracture (Spiral Oblique)

#### Indications

Fractures involving the metaphyseal or diaphyseal region of the metatarsal.<sup>29</sup>

#### Procedure

The patient is positioned supine for surgery, prepped, and draped, and a tourniquet is applied. An incision is made over the shaft of the fifth metatarsal and deepened in the same plane, exposing the fracture. The fracture ends are debrided with a curette and anatomicallly aligned with a bone forcep. Interfragmental fixation utilizing two or more (depending on the length of the fracture) 2.0 cortical



screws is applied perpendicular to the fracture line. If additional stability is required, a one-quarter tubular plate is applied to the dorsal-lateral aspect of the fifth metatarsal shaft.

**Postoperative care**

A Jones compression bandage is applied for two weeks, followed by a nonweightbearing below-the-knee cast for an additional four weeks. A removable walking boot is used until radiographic and clinical healing is demonstrated.

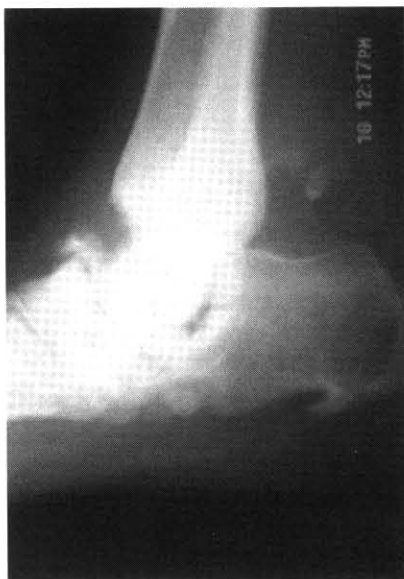**Jones Fracture**

**Indications**

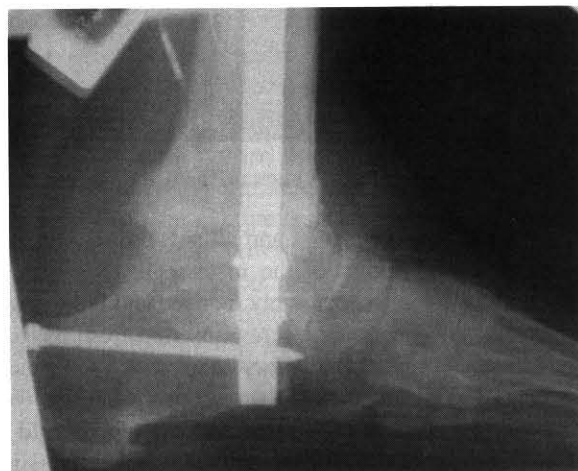Fractures involving the proximal diaphyseal-metaphyseal junction of the fifth metatarsal

**Procedure**

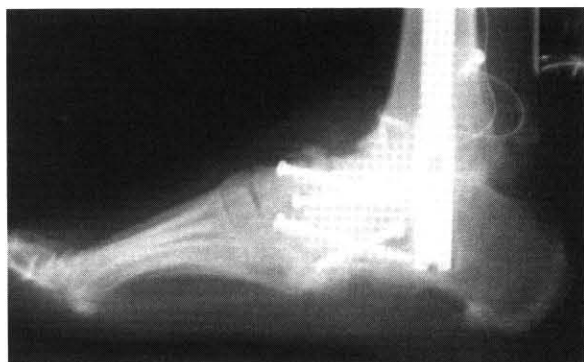The patient is positioned supine for surgery, prepped, and draped, and a tourniquet is applied. An incision is made at



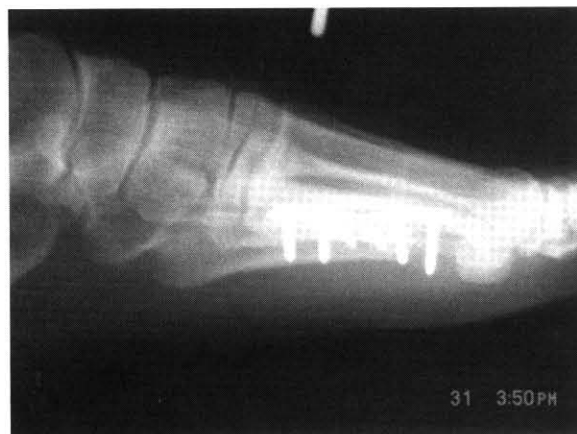**FIGURE 52-103.** Intramedullary nail hindfoot and ankle pre-operative.



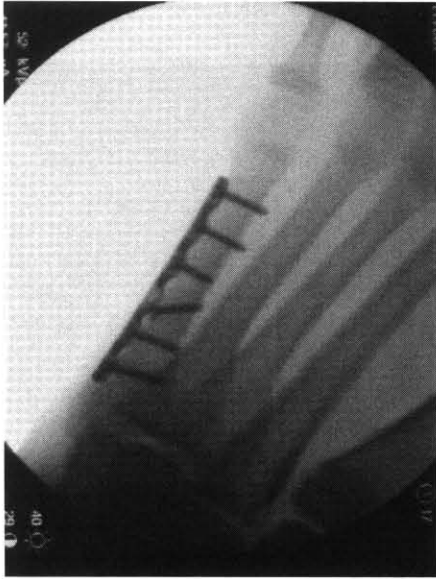
**FIGURE 52-105.** Intramedullary nail hindfoot and ankle postoperative.



**FIGURE 52-104.** Intramedullary nail hindfoot and ankle postoperative.



**FIGURE 52-106.** Fifth metatarsal fracture postoperative.



**FIGURE 52-107.** Fifth metatarsal fracture postoperative.

the base of the fifth metatarsal and all soft tissues are freed from the proximal region of the metatarsal, exposing the fracture. The fracture is accurately reduced and fixated with either tension band wire or a screw inserted from the base of the metatarsal into the medullary canal with a 4.0 cancellous screw, larger cortical (4.5) screw, or cancellous (6.5) screw based on the patient's size. An attempt should be made to insert a larger and longer screw when possible. Another option is to use a one-quarter tubular plate and 2.0 cortical screws. Depending on the situation, sometimes the surgeon may need to use autogenous bone graft with the plates and screws.

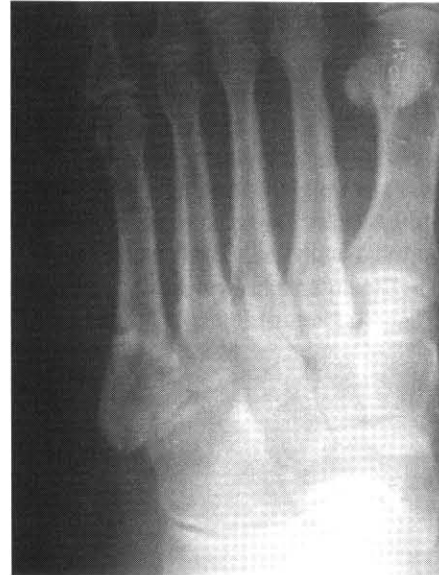### Postoperative care

A Jones compression bandage is applied for two weeks, followed by a nonweightbearing below-the-knee cast for an additional six to eight weeks. A removable walking cast is used for an additional four weeks based on clinical and radiographic evaluation.

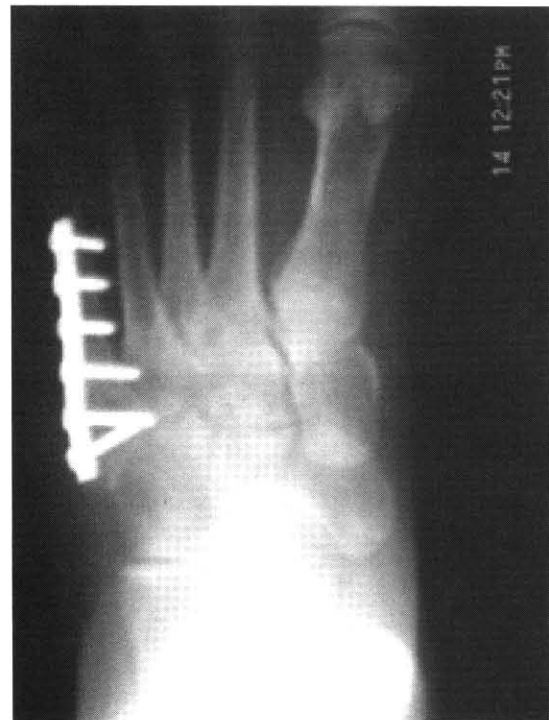## Navicular Body Fractures

### Indications

Displaced navicular body fractures. ORIF is indicated for navicular body fractures that cannot be anatomically reduced by closed means and are amenable to fixation.<sup>29</sup>



**FIGURE 52-108.** Preoperative nonhealing Jones fracture following months of immobilization.



**FIGURE 52-109.** Postoperative repair of nonhealing Jones fracture using 2.0 screws and one-fourth tubular plate and autogenous bone graft.

## Procedure

The patient is positioned supine for surgery, prepped, and draped, and a tourniquet is applied. A dorsomedial longitudinal incision is placed lateral to the anterior tibial tendon and extending from the talus to the cuneiform. Dissection is carried down to the periosteum overlying the fracture. All soft tissue structures are removed from the fracture site and the fracture ends are prepared. The fracture is then reduced and provisionally fixated with a guide wire placed from medial to lateral. A 4.0-mm cannulated cancellous screw is then inserted over the guide wire from medial to lateral. This screw should not purchase the far cortex. Fluoroscopy is used to ensure the fixation is adequate.

## Postoperative care

A Jones compressive bandage is applied for two weeks, followed by a nonweightbearing below-the-knee cast for an

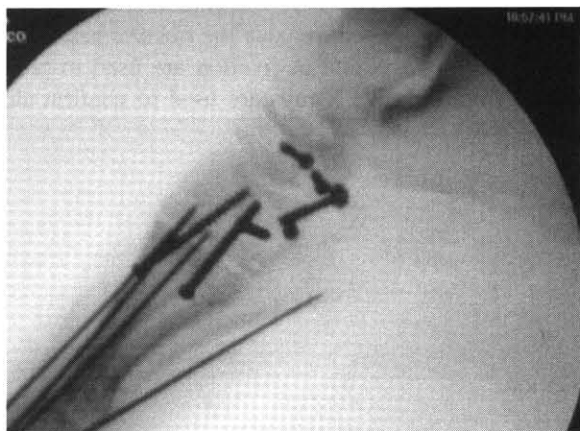


FIGURE 52-110. Intraoperative navicular fracture.

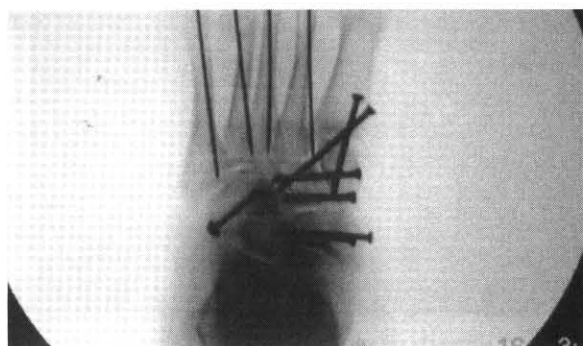


FIGURE 52-111. Intraoperative navicular fracture.

additional six weeks. A removable walking cast is used for an additional four weeks based on clinical and radiographic evaluation.

## Talar Body Fractures

### Indications

Displaced talar body fractures. ORIF is indicated for talar body fractures that cannot be anatomically reduced by closed means and are amenable to fixation.<sup>29</sup>

### Procedure

The patient is positioned supine for surgery, prepped, and draped, and a tourniquet is applied. A lateral oblique incision is made extending from the calcaneus just inferior to the lateral malleolus up to the anterior aspect of the talar neck. Dissection is carried down to the periosteum overlying the fracture. All soft tissue structures are removed from the fracture and the fracture ends are prepared. The fracture is then reduced and provisionally fixated with K-wires. Next a medial incision is made and dissection is carried down to the periosteum overlying the fracture. The fracture is checked to be sure it is anatomically reduced and there is

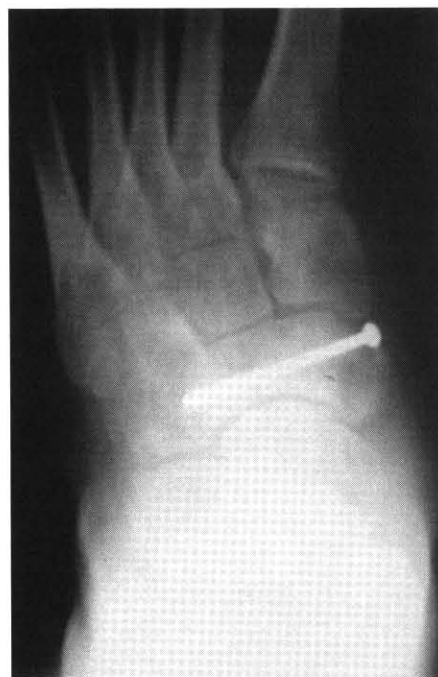

FIGURE 52-112. Navicular fracture postoperative.

no component of rotation. Fluoroscopy is used to ensure adequate reduction. The fracture is then fixated with a 4.0-mm cancellous lag screw under compression. The screw is inserted from the talar head into the body and should not purchase the far cortex. This can be done from either the medial or lateral side. A second 4.0-mm cannulated cancellous screw is inserted to prevent rotation. If extremely comminuted, bone graft may be used to fill any voids or gaps.

### Postoperative care

A Jones compressive bandage is applied for two weeks, followed by a nonweightbearing below-the-knee cast for an

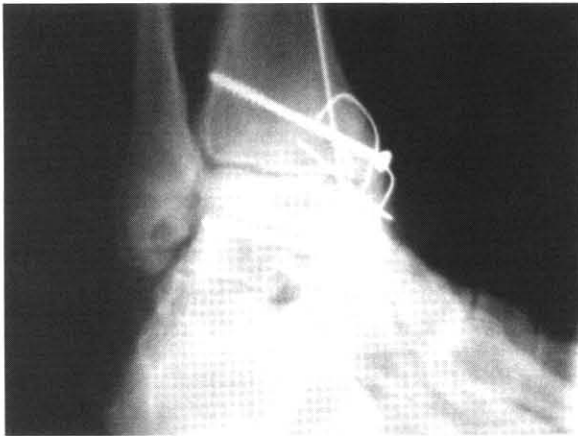

FIGURE 52-113. Talar body fracture postoperative.

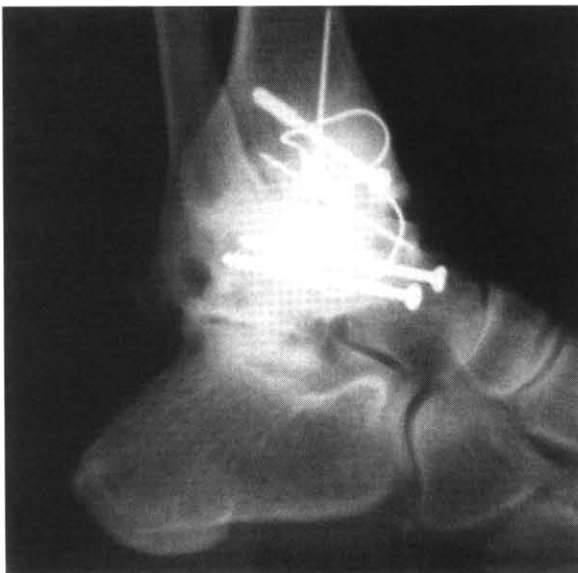

FIGURE 52-114. Talar body fracture postoperative.

additional six weeks. A removable walking cast is used for an additional four weeks based on clinical and radiographic evaluation.

### Talar (Lateral Process Fracture)

#### Indications

Displaced lateral process fracture.

#### Procedure

The patient is positioned supine for surgery, prepped, and draped, and a tourniquet is applied. A lateral oblique incision is made extending from the calcaneus just inferior to the lateral malleolus up to the anterior aspect of the talar neck. Dissection is carried deep to the tissues overlying the fracture. The fracture is mobilized and all soft tissue and hematoma are debrided and removed from the fracture site. The fracture is then reduced and provisionally fixated with K-wires. Two 2.7 or two 2.0 or a combination of a larger and smaller screw is used to fixate the fracture based on the fracture size. Two points of fixation are used to prevent rotation. Intraoperative X-rays are used to confirm alignment; Broden's view is most useful.

#### Postoperative care

A Jones compressive bandage is applied for two weeks, followed by a nonweight bearing below-the-knee cast for an additional four weeks. A removable walking cast is used for an additional four weeks based on clinical and radiographic evaluation.

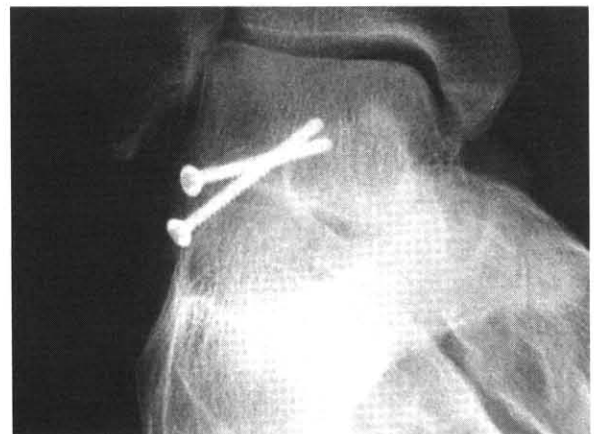

FIGURE 52-115. Postoperative lateral process talar fracture.

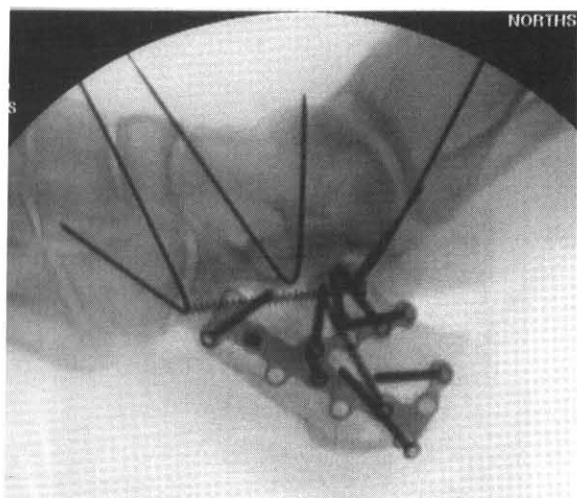


FIGURE 52-116. Calcaneal fracture intraoperative.

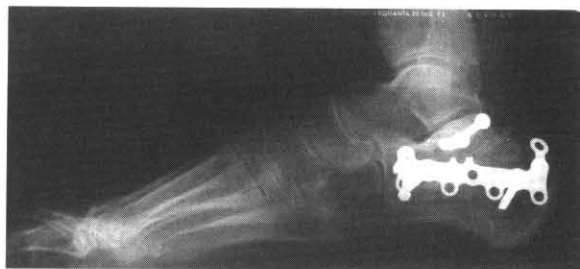

FIGURE 52-117. Calcaneal postoperative.

## Calcaneal Fracture

### Indications

Fractures involving the subtalar joint, lateral wall displacement, shortened calcaneus, varus calcaneus, and anterior ankle impingement.<sup>30</sup> Respect for the soft tissue envelope is paramount, and skin wrinkles (demonstrating a decrease of soft tissue edema) should be present prior to surgery being performed.

### Procedure

The patient is positioned in a lateral position for surgery, prepped, and draped above the knee to allow visualization of the alignment of the entire lower extremity, and a tourni-

quet is applied. The incision is a right-angle incision beginning proximal and parallel to the Achilles tendon and continuing distally to the plantar skin and parallel to the floor. This incision is a full-thickness flap to preserve the sural nerve, peroneal tendons and calcaneal fibular ligament. Subperiosteal dissection is performed to allow for good exposure. The flap is retracted anterior and proximal with K-wires. A Schanz screw is inserted into the posterior-inferior portion of the calcaneus or from lateral to medial in the most inferior posterior section of the calcaneus. Portions of the lateral wall are retracted and manipulation of the fracture is performed to restore anatomical alignment. Anatomical reduction necessitates maneuvers of the Schanz pin in an inferior-valgus attitude. After reduction of the fragments, 3.5 cortical screws are utilized to stabilize the fracture into the sustentaculum tali. A calcaneal plate is then applied utilizing 3.5 cortical screws while maintaining the inferior and valgus pull on the Schanz pin. These screws should purchase the far cortex. Restoration of Bohler's and Gissane's angle should be accurately restored. Radiographic evaluation of lateral, axial, and Broden's view are used to confirm anatomical restoration. K-wires are removed and the soft tissue flap is closed with great care.

### Postoperative care

A Jones compressive bandage is applied for two weeks, followed by a nonweightbearing below-the-knee cast for an additional six weeks. A removable walking cast is used for an additional four weeks based on clinical and radiographic evaluation.

## Ankle Fractures

### Indications

Any ankle fracture with displacement which is not reducible by closed means and is amenable to fixation. Restoring the articular surface and maintaining fibula length are mandatory.

### Procedure

The patient is positioned supine for surgery, prepped, and draped, and a tourniquet is applied. If a bimalleolar fracture exists, the fibular fracture should be fixated first. A posterolateral incision is performed over the fibula. Dissection is then carried down to the periosteum overlying the fracture. The periosteum is freed from the fracture edges and any soft tissue structures are removed from the fracture site. The fibular fracture is then reduced and held in place with a bone clamp. Next a 3.5-mm cortical screw is inserted

as a lag screw across the fracture site. This screw should be perpendicular to the fracture. Next a one-third tubular plate is applied as a neutralization plate to the fibula. The distal screws should be 4.0-mm cancellous screws and should not exit the far cortex, so they do not violate the ankle joint. The proximal screws should be 3.5-mm cortical screws, and two threads should exit the far cortex. These screws will not act as lag screws, so the near cortex does not have to be overdrilled.

For an isolated medial malleolar fracture an anteromedial incision is made overlying the medial malleolus. Dissection is carried down, protecting the saphenous vein and nerve, to the ankle joint capsule. The capsule is incised and the talus is inspected for any osteochondral fragments or lesions. Next the periosteum is elevated off the fracture edges and any soft tissues are removed from the fracture site. The fracture ends are then prepared and then reduced and held in place with a bone clamp. The fracture can be fixated using the tension band wire or with screw fixation. If screw fixation is being applied then two guide wires are then inserted perpendicular to the fracture and act as temporary fixation. Fluoroscopy is used to ensure the articular surface of the ankle joint is reduced. The guide wires are then measured and two 4.0-mm cannulated cancellous screws are inserted over the guide wires.

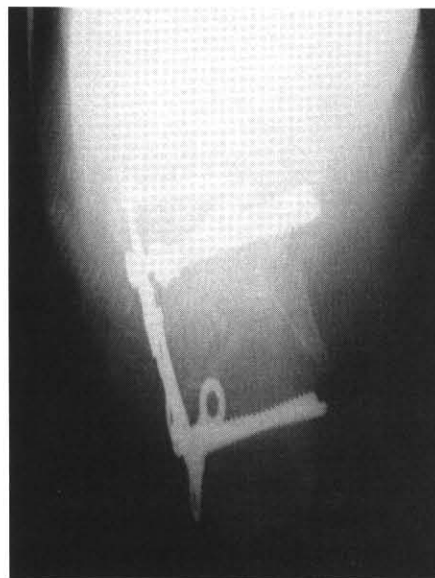If a syndesmotomic injury is suspected, this should be assessed and fixed if necessary. This can be performed by inserting one or two 3.5-mm cortical, 4.0 cortical, or 4.5-mm syndesmotomic screws 2–5 cm above and parallel to the joint. The ankle should be placed in 5° of dorsiflexion when drilling. The screw should be placed at a 30° angle from posterior to anterior when drilled and inserted to accommodate for the external rotation of the fibula relative to the tibia. The syndesmotomic screw may be placed through the holes in a fibular plate or by itself if the fibular fracture is proximal. The screw should not be lagged or compressed and should purchase three or four cortices.

Posterior malleolus fractures should be fixated if 25% or more of the tibial articular surface is involved. This should be evaluated after fibular reduction and stabilization, as reducing the fibula will aid in reduction of the posterior fragment due to its ligamentous attachments. Fixation may be made posterior to anterior or vice versa depending on the fragment size. If smaller, the posterior approach is preferred. Once the fracture is reduced, a 4.0-mm cancellous screw is inserted. A washer may be needed depending on the quality of bone.

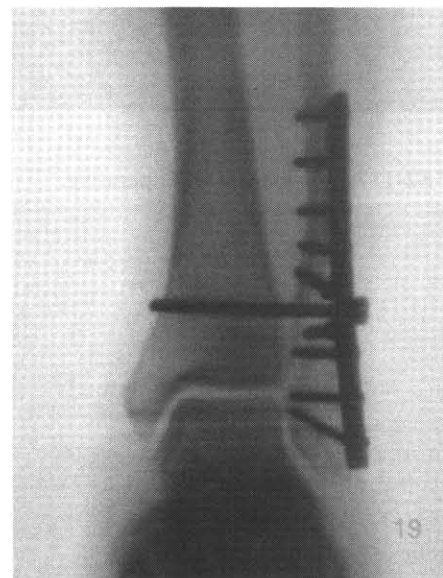
### Postoperative care

A Jones compression bandage is applied for two weeks, followed by a nonweightbearing below-the-knee cast for an additional four to six weeks. A removable walking cast is

used for an additional four weeks based on clinical and radiographic evaluation.

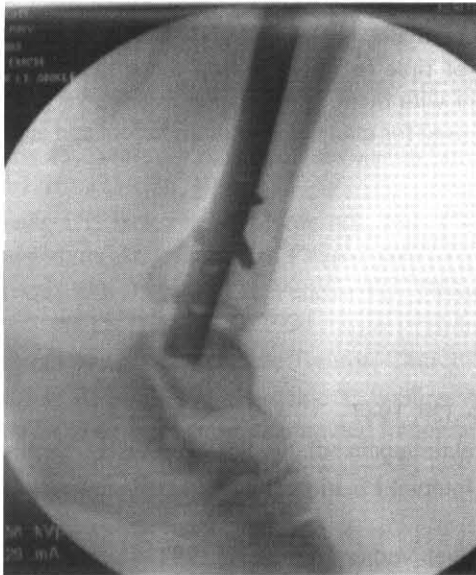


**FIGURE 52-118.** Calcaneal fracture postoperative axial.

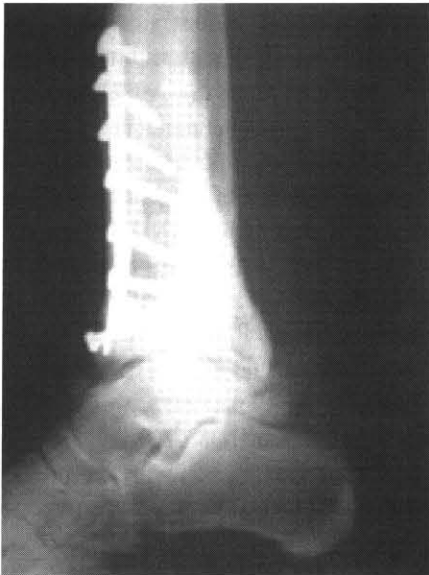

**FIGURE 52-119.** Ankle fracture with a syndesmotomic postoperative injury.

## Pilon Fractures



**FIGURE 52-120.** Ankle fracture with a syndesmotic injury postoperative.



**FIGURE 52-121.** Pilon fracture.

### Indications

Displaced pilon fractures. ORIF is indicated for any pilon fractures that cannot be anatomically reduced by closed means and are amenable to fixation.<sup>31</sup> These fractures are typically treated with an external fixator to hold the anatomy out to length while waiting for reduction of edema and soft tissue integrity. Respect for the soft tissue envelope is paramount.

### Procedure

Initial treatment usually consists of an application of an external fixator to maintain length and alignment while the soft tissue edema subsides. After the soft tissue edema has subsided (sometimes this can take up to three weeks), the patient is prepared for either treatment with open reduction and internal fixation or percutaneous fixation.

The patient is positioned supine for surgery, prepped, and draped above the knee to allow visualization of the alignment of the entire lower extremity, and a tourniquet is applied. When the fibula is fractured, it must be reduced and fixated first. A posterolateral incision is performed over the fibula. Dissection is then carried down to the periosteum overlying the fracture. The periosteum is freed from the fracture edges and any soft tissue structures are removed from the fracture site. The fibular fracture is then reduced and held in place with a bone clamp. Next, a 3.5-mm cortical screw is inserted as a lag screw across the fracture site. This screw should be perpendicular to the fracture. Next a one-third tubular plate is applied as a neutralization plate to the fibula. The distal screws should be 4.0-mm cancellous screws and should not exit the far cortex, so they do not violate the ankle joint. The proximal screws should be 3.5-mm cortical screws, and two threads should exit the far cortex. These screws will not act as lag screws, so the near cortex does not have to be overdrilled.

Next a second anterior incision is made which starts about 1 cm lateral to the tibial crest proximally and extends distally, curving over the anteriomedial aspect of the medial malleolus. There should be a bridge of at least 5–10 cm between the two incisions. Dissection is then carried down through the subcutaneous fat in line with the incision. Do not undermine the soft tissues and be sure to preserve the paratenon of the tibialis anterior tendon. Continue dissection down to the periosteum, which can be subperiosteally elevated. The tibial articular surface must be restored. Small tibial fragments should be stabilized with K-wires, while larger fragments should be reconstructed tibia with a buttress plate. Plates that can be applied to the medial aspect are the cloverleaf, T-plate, and dynamic compression plate. Plates that work well when

applied anteriorly are the spoon and T-plate. This will help to prevent a late varus deformity.

## CONCLUSION

This chapter discussed the four basic principles utilized by the AO group to enhance the results of surgical treatment

while using rigid internal fixation in forefoot, rear foot and ankle surgery. It reviewed the basic instrumentation and techniques learned over the years. These techniques and skills should not be taken lightly—it takes a substantial amount of time to fully develop these skills and become proficient with them. The chapter reviews various types of fixation used for many of the common foot and ankle procedures.

## REFERENCES

1. Danis R: The operative treatment of bone fractures. *J Int Chir* 7:318–320, 1947
2. Muller ME, Allgower M, Willenegger H: *Technik der operativen Frakturenbehandlung*. Springer-Verlag, Berlin, 1963
3. Muller ME, Allgower M, Schneider R, Willenegger H: *Manual of Internal Fixation: Techniques Recommended by the AO-ASIF Group*. Springer-Verlag, New York, 1969
4. Schatzker J, Tile M: *The Rationale of Operative Fracture Care*. Springer-Verlag, New York, 1987
5. Singer JK: *Hershey Board Certification Review Outline Study Guide*. 1998
6. Schatzker J, Sanderson R, Murnaghan JP: The holding power of orthopedic screws in vivo. *Clin Orthop Relat Res* (108):115–126, 1975
7. Schatzker J, Horne JG, Sumner-Smith G: The effect of movement on the holding power of screws in bone. *Clin Orthop Relat Res* (111):257–262, 1975
8. Schatzker J, Horne JG, Sumner-Smith G: The reaction of cortical bone to compression by screw threads. *Clin Orthop Relat Res* (111):263–265, 1975
9. Schatzker J, Manley PA, Sumner-Smith G: In vivo strain gauge study of bone response to loading with and without internal fixation. Pp 306–314. In Uthoff HK (ed): *Current Concepts of Internal Fixation of Fractures*. Springer-Verlag, Berlin, 1980
10. Kelikian AS (ed): *Operative Treatment of the Foot and Ankle*. Appleton & Lange, Stamford, CT, 1999
11. ASTM A 276. *Standard Specification for Stainless Steel Bars and Shapes*. American Society for Testing and Materials, West Conshohocken, PA
12. Perren SM: Physical and biological aspects of fracture healing with special reference to internal fixation. *Clin Orthop Relat Res* (138):175–196, 1979
13. Hansen ST: *Functional Reconstruction of the Foot and Ankle*. Lippincott Williams & Wilkins, Philadelphia, 2000
14. McGlamry ED, Banks AS, Downey MS (eds): *Comprehensive Textbook of Foot Surgery*. 2nd ed, Vol 1. Williams & Wilkins, Baltimore, 1992
15. Akin O: The treatment of hallux valgus: A new operative procedure and its results. *Med Sentinel* 33:678–679, 1925
16. Manoli A 2nd, Hansen ST Jr: Screw hole preparation in foot surgery. *Foot Ankle* 11(2):105–106, 1990
17. Reverdin J: Anatomie et operation de l'hallux valgus. *Int Med Congr* 2:408, 1881
18. Austin DW, Leventen EO: A new osteotomy for hallux valgus: a horizontally directed V displacement osteotomy of the metatarsal head for hallux valgus and primus varus. *Clin Orthop Relat Res* (157):25–30, 1981
19. Kalish SR, Bernbach MR: Modification of the Austin bunionectomy. In McGlamry ED (ed): *Reconstructive Surgery of the Foot and Leg, Update '87*. Podiatry Institute, Tucker, GA, 1987
20. Lapidus PW: Operative correction of the metatarsus varus primus in hallux valgus. *Surg Gynecol Obstet* 58:183–191, 1934
21. Dull JM, DiDomenico LA: Percutaneous displacement calcaneal osteotomy. *J Foot Ankle Surg* 43(5):336–337, 2004
22. Hoke M. An operation for the correction of extremely relaxed flat feet. *J Bone Joint Surg* 13:773–783, 1931



23. Alvarez RG, Trevino SG: Surgical treatment of the Charcot foot and ankle. Pp 147–178. In Kelikian AS (ed): *Operative Treatment of the Foot and Ankle*. Appleton & Lange, Stamford, CT, 1999
24. Sticha RS, Frascone ST, Wertheimer SJ: Major arthrodeses in patients with neuropathic arthropathy. *J Foot Ankle Surg* 35(6):560–566, 1996
25. Brodsky JW, Rouse AM: Exostectomy for symptomatic bony prominences in diabetic Charcot feet. *Clin Orthop Relat Res* (296):21–26, 1993
26. Early JS, Hansen ST: Surgical reconstruction of the diabetic foot: a salvage approach for midfoot collapse. *Foot Ankle Int* 17(6):325–330, 1996
27. Huang CT, Jackson JR, Moore NB, Fine PR, Kuhlemeier KV, Traugh GH, Saunders PT: Amputation: energy cost of ambulation. *Arch Phys Med Rehabil* 60(1):18–24, 1979
28. Alvarez RG, Barbour TM, Perkins TD: Tibiocalcaneal arthrodesis for nonbraceable neuropathic ankle deformity. *Foot Ankle Int* 15(7):354–359, 1994
29. Scurran BL: *Foot and Ankle Trauma*. Churchill Livingstone, New York, 1996
30. Sanders R, Fortin P, DiPasquale T, Walling A: Operative treatment in 120 displaced intraarticular calcaneal fractures. Results using a prognostic computed tomography scan classification. *Clin Orthop Relat Res* (290):87–95, 1993
31. McGlamry ED, Banks AS, Downey MS (eds): *Comprehensive Textbook of Foot Surgery*. 2nd ed, Vol 2. Williams & Wilkins, Baltimore, 1992

### ADDITIONAL READING

- AMS 2249C, Chemical Check Analysis Limits, Titanium and Titanium Alloys. Society of Automotive Engineers, Warrendale, PA
- ASTM A 262, Practices for Detecting Susceptibility to Intergranular Attack in Austenitic Stainless Steels. American Society for Testing and Materials, West Conshohocken, PA.
- ASTM A 276, Standard Specification for Stainless Steel Bars and Shapes. American Society for Testing and Materials, West Conshohocken, PA
- ASTM A 967, Standard Specification for Chemical Passivation Treatments for Stainless Steel Parts. American Society for Testing and Materials, West Conshohocken, PA
- ASTM B 600, Standard Recommended Practice for Descaling and Cleaning Titanium and Titanium Surfaces. American Society for Testing and Materials, Philadelphia, PA
- ASTM E 45, Standard Test Methods for Determining the Inclusion Content of Steel. American Society for Testing and Materials, West Conshohocken, PA
- ASTM F 55-65T, Standard Specifications for Stainless Steel Bar and Wire for Surgical Implants, American Society for Testing and Materials, West Conshohocken, PA
- ASTM F 55-66, Standard Specification for Stainless Steel Sheet and Strip for Surgical Implants (Special Quality). American Society for Testing and Materials, West Conshohocken, PA
- ASTM F 86, Standard Practice for Surface Preparation and Marking of Metallic Surgical Implants. American Society for Testing and Materials, West Conshohocken, PA
- ASTM F 138-71, Standard Specification for Stainless Steel Bar and Wire for Surgical Implants (Special Quality). American Society for Testing and Materials, West Conshohocken, PA
- ASTM F 138, Standard Specification for Wrought 18 Chromium-14 Nickel-2.5 Molybdenum Stainless Steel Bar and Wire for Surgical Implants (UNS S31673). American Society for Testing and Materials, West Conshohocken, PA
- ASTM F 139, Standard Specification for Wrought 18 Chromium-14 Nickel-2.5 Molybdenum Stainless Sheet and Strip for Surgical Implants (UNS S31673). American Society for Testing and Materials, West Conshohocken, PA
- ASTM F 139-76, Standard Specification for Stainless Steel Sheet and Strip for Surgical Implants (Special Quality). American Society for Testing and Materials, West Conshohocken, PA

- ASTM F 981, Assessment of Compatibility of Biomaterials (nonporous) for Surgical Implants with Respect to Effect of Materials on Muscle and Bone. American Society for Testing and Materials, Philadelphia, PA
- ASTM F 981, Standard Practice for Assessment of Compatibility of Biomaterials for Surgical Implants with Respect to Effect of Materials on Muscle and Bone. American Society for Testing and Materials, West Conshohocken, PA
- ASTM F 1295, Standard Specification for Wrought Titanium-6 Aluminum-7 Niobium Alloy for Surgical Implant Applications. American Society for Testing and Materials, Philadelphia, PA
- ASTM F 1314, Standard Specification for Wrought Nitrogen Strengthened-22 Chromium-12.5 Nickel-5 Manganese-2.5 Molybdenum Stainless Steel Bar and Wire for Surgical Implants. American Society for Testing and Materials, West Conshohocken, PA
- ASTM F 1350, Standard Specification for Stainless Steel Surgical Fixation Wire. American Society for Testing and Materials, West Conshohocken, PA
- ASTM F 1408, Practice for Subcutaneous Screening Test for Implant Materials. American Society for Testing and Materials, Philadelphia, PA
- ASTM F 1586, Standard Specification for Wrought Nitrogen Strengthened-21 Chromium-10 Nickel-3 Manganese-2.5 Molybdenum Stainless Steel Bar for Surgical Implants. American Society for Testing and Materials, West Conshohocken, PA
- Barbosa MA: Corrosion mechanisms of metallic biomaterials. Pp 250–253. In Barbosa MA (ed): Biomaterials Degradation: Fundamental Aspects and Related Clinical Phenomena. Elsevier, Amsterdam, 1991
- Blunt JW Jr, Hudack SS, Murray CR: Metals and Plastics in Orthopedic Surgery and General Surgery. Clinical Congress, American College of Surgeons, New York, 1952
- Brown SA, Merritt K: Fretting corrosion of plates and screws: an in vitro test method. Pp 105–116. In Fraker AC, Griffin CD (eds): Corrosion and Degradation of Implant Materials: Second Symposium, ASTM STP 859. American Society for Testing and Materials, Philadelphia, 1985
- Carpenter Technology Corporation Alloy Data, Biodur™ 316LS Stainless, Medical Implant Alloys. Carpenter Technology Corp, Reading, PA, Feb 1995
- Desai RJ, Sinkford JC: Tissue response to intraosseous implants in albino rats. *Oral Surg Oral Med Oral Pathol* 37(1):26-34, 1974
- Disegi J: AO/ASIF Unalloyed Titanium Implant Material, 2nd ed. AO/ASIF Technical Publication, SYNTHES (USA), July 1991
- Disegi J: Internal correspondence, SYNTHES (USA), Paoli, PA
- Disegi J: Magnetic resonance imaging of AO/ASIF stainless steel and titanium implants. *Injury* 23 Suppl 2:S1–4, 1992
- Frey N, Buchillier T, Le V-D, Steinemann SG: Properties of surface oxides on titanium and some titanium alloys. In Froes FH, Caplan I (eds): Titanium '92: Science and Technology. TMS, Warrendale, PA, 1993
- Gerber H, Perren S: Evaluation of tissue compatibility of in vitro cultures of embryonic bone. Pp 307–314. In Winter GD, Leray JL, deGroot K (eds): Evaluation of Biomaterials. John Wiley & Sons, New York, 1980
- Gerber H et al: Bioactivity of metals. Tissue tolerance of soluble solid metal tested on organ cultured embryonic bone rudiments. In Buchhorn GH, Wiliert HG (eds): Technical Principles, Design and Safety of Implants. Hogrefe & Huber, Toronto, 1994
- Gold J, Schmidt M, Steinemann SG: XPS Study of Retrieved Titanium and TiAlloy Implants. Pp 69–74. In Heimke G, Soltesz U, Lee AJC (eds): Advances in Biomaterials, vol 9. Elsevier Science, Amsterdam, 1990
- Hierholzer S, Hierholzer G: Internal Fixation and Metal Allergy. Thieme, New York, 1992
- Irving CC Jr: Electropolishing stainless steel implants. Pp 136–143. In Fraker AC, Griffin CD (eds): Corrosion and Degradation of Implant Materials: Second Symposium. ASTM STP 859. American Society for Testing and Materials, Philadelphia, 1985
- ISO 5832-1, Implants for Surgery—Metallic materials—Part 1: Wrought stainless steel. International Organization for Standardization, Geneva
- ISO 6892, Metallic materials—Tensile testing. International Organization for Standardization, Geneva
- ISO/DIS 5832-11, Implants for surgery—Metallic materials—Part II: Wrought titanium—6 Aluminum—7 Niobium alloy. International Organization for Standardization, Geneva

- Laing PG: Clinical experience with prosthetic materials: historical perspectives, current problems, and future directions. P 202. In Syrett B, Achyara A (eds): Corrosion and Degradation of Implant Materials. ASTM STP 684. American Society for Testing and Materials, West Conshohocken, PA, 1979
- Lucas L, Ong JL, Lemons JE, Reddrick T, Rigney ED: Corrosion and auger surface chemistry analyses of surface modified porous titanium. P 201. In Transactions of the 17th Annual Society for Biomaterials, May 1–5, 1991
- Mausli P, Bloch PR, Geret V, Steinemann SG: Surface characterization of titanium and Ti-alloys. Pp 57–62. In Christel P, Meunier A, Lee AJC (eds): Biological and Biomechanical Performance of Biomaterials. Elsevier Science, Amsterdam, 1986
- Millar BG, Frame JW, Browne RM: A histological study of stainless steel and titanium screws in bone. *Br J Oral Maxillofac Surg* 28(2):92–95, 1990
- Mils K, Davis JR, Dietricj DA, Crankovic GM, Frissell HJ: Metallographic techniques and microstructures: specific metals and alloys. Pp 284–289. In *Metals Handbook*, 9th ed. American Society for Metals, Metals Park, OH, 1985
- Niobium. Pp 3–4. In product brochure, Teledyne Wah Chang, Albany, OR  
Severn Engineering Company, Inc., Annapolis, MD
- Olmstead M, Pohler O: Report on long term compatibility testing of new titanium alloys. AO Research Grant 1987/88, Stratec Medical, Waldenburg, Switzerland, January 17, 1990
- Perren S et al: Quantitative evaluation of biocompatibility of vanadium free titanium alloys. Pp 397–402. In *Biomechanical Performance of Biomaterials*. Elsevier Science, Amsterdam, 1980
- Peterson L: Fixation of bones by plates and screws. *J Bone Joint Surg* 29:335–347, 1947
- Pflunger G et al: Bone reactions to porous and grooved stainless steel, tantalum, and niobium implants. Pp 45–50. In Winter GD, Gibbons DF, Plenk H Jr (eds): *Biomaterials*. John Wiley & Sons, New York, 1980
- Pohler O: Failures of metallic orthopedic implants. Pp 683–688. In *Metals Handbook*, 9th ed, vol 11. American Society for Metals, Metals Park, OH, 1985
- Pohler O, Straumann F: Characteristics of the Stainless Steel ASIF/AO Implants. Institute Straumann AG, Waldenburg, Switzerland, September 1975
- Protasul® 100 (Ti-6Al-7Nb) vanadium-free, high strength titanium alloy. Technical report, Protek Inc, Indianapolis, IN, 1988
- Ruedi TP: *Titan und Stahl in der Knochenchirurgie*. Springer-Verlag, Berlin, 1975.
- Semlitsch M, Staub F, Weber H: Development of a vital, high-strength titanium-aluminum-niobium alloy for surgical implants. Pp 69–74. In Christel P, Meunier A, Lee AJC (eds): *Biological and Biomechanical Performance of Biomaterials*. Elsevier Science, Amsterdam, 1986
- Semlitsch M, Staub F, Weber H: Titanium-aluminum-niobium alloy, development for biocompatible high strength surgical implants. *Biomed Tech* 30(12):334–339, 1985
- Sheehan JP, Morin CR, Packer KF: Study of stress corrosion cracking susceptibility of type 316L stainless steel in vitro. Pp 57–72. In Fraker AC, Griffin CD (eds): *Corrosion and Degradation of Implant Materials: Second Symposium*, ASTM STP 859. American Society for Testing and Materials, Philadelphia, 1985
- Sherry RH, Ottersberg WH: Metals in orthopedic surgery. Pp 509–540. In Wise DL, Trantolo DJ, Altobelli DE (eds): *Encyclopedic Handbook of Biomaterials and Bioengineering*, Part B, vol 1. Marcel Dekker, New York, 1995
- Simpson J: The electrochemical behavior of titanium and titanium alloys with respect to their use as surgical implant materials. Pp 63–68. In Christel P, Meunier A, Lee AJC (eds): *Biological and Biomechanical Performance of Biomaterials*. Elsevier Science, Amsterdam, 1986
- Simpson J: Re: ASTM-Norm titanium alloy Ti-6Al-7Nb. Internal Report, Sulzer Innotec, Winterthur, Feb 3, 1990
- Solar, R, Pollack SR, Korostoff E: Titanium release from implants: a proposed mechanism. Pp 161–172. In Syrett B, Achyara A (eds): *Corrosion and Degradation of Implant Materials*. ASTM STP 684. American Society for Testing and Materials, West Conshohocken, PA, 1979
- Steinemann SG: Corrosion of surgical implants—in vivo and in vitro tests. Pp 11–34. In Winter GD, Leray JL, deGroot K (eds): *Evaluation of Biomaterials*. John Wiley & Sons, New York, 1980
- Steinemann SG, Mausli P-A: Titanium alloys for surgical implants < biocompatibility from physiochemical principles. Pp 535–540. In Lacombe P, Tricot R, Beranger G (eds): *Proceedings of Sixth World Conference on Titanium*, Cannes 1988. Editions de physique, Les Ulis, France, 1989

- Steinemann SG, Mausli P-A, Szmukler-Moncler S, Semlitsch M, Pohler O, Hintermann H-E, Perren SM: Beta-titanium alloy for surgical implants. In Froes FH, Caplan I (eds): Titanium '92: Science and Technology. TMS, Warrendale, PA, 1993
- Steinemann SG, Perren SM: Surgical implant and alloy for use in making an implant. US Patent 4,040,129, August 9, 1977
- Surgical Implant Alloy JML 367. Producer Bulletin. IMI Titanium Limited, Birmingham, England, Kynoch Press
- Technical Committee of European Titanium Producers: ETCC2 Monograph. IMI Titanium Ltd, Birmingham, England, Kynoch Press
- Ungersbock A, Pohler OEM, Perren SM: Evaluation of soft tissue reactions at the interface of titanium limited contact dynamic compression plate implants with different surface treatments: an experimental sheep study. *Biomaterials* 17(8):797-806, 1996
- Zweymuller K, Lindner F, Semlitsch M: Biological fixation of a press-fit titanium hip joint endoprosthesis. *Clin Orthop Relat Res* (235): 195-206, 1988