

# 34

## Intramedullary Nailing for “Charcot” Arthropathy of the Hindfoot and Ankle

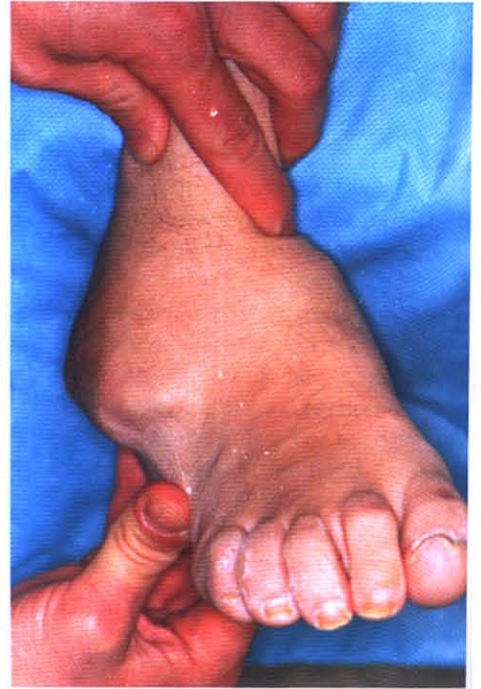Lawrence A. DiDomenico,  
Heiko B. Adams

---

### INDICATIONS/CONTRAINDICATIONS

Indications for the surgical reconstruction of “Charcot” arthropathy of the ankle and hindfoot are the result of failure of conservative treatment to properly address the following: chronic recurrent ulcerations, bony deformities, unstable joints, a nonbraceable and unshoeable ankle and foot, acute displaced fractures, and malalignment (1) (Figs. 34-1 and 34-2). Inadequate stabilization of the existing disease process may result in further breakdown and continued progression of the deformity. Often times with multiple joint involvement such as the ankle, subtalar joint, and midfoot it is a good idea to initiate surgical stabilization and realignment as early as possible in an attempt to avoid the often inevitable severe deformity and skin breakdown (2). The surgical goal is to restore stability and alignment so that shoe gear and bracing are possible and achieve a plantar grade weightbearing surface free of ulceration.

A recent study by Simon et al. (2) compared the average cost of operative intervention for destructive “Charcot” arthropathy with that of below the knee amputations during the same period. He found that the average cost for operative intervention was between \$9527 and \$16,417.00 and the cost for below-the-knee amputations between \$17,261 and \$39,045. Historically, surgical intervention for severe “Charcot” arthropathy has resulted in less than favorable results, with less than 50% of patients maintaining a weightbearing functional extremity. However, in recent years improved hardware design and strength and improvements in osseous healing capabilities, such as bone stimulators and platelet rich additives, surgical outcomes for the severe destruction of “Charcot” arthropathy has resulted in a greater number of successful outcomes.

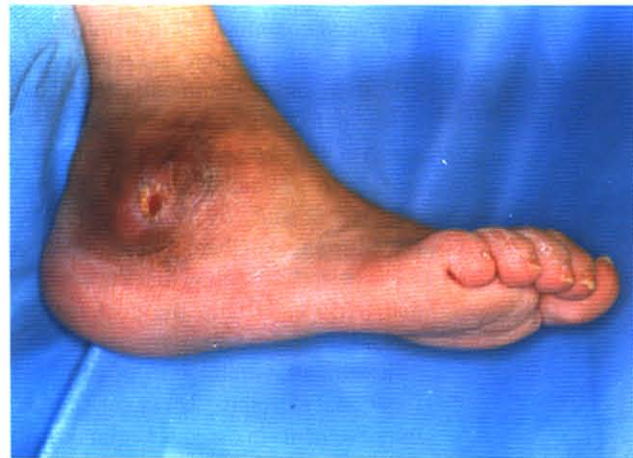

**Figure 34-1.** Clinical photograph: anterior view of the lower extremity showing the angulation and malalignment associated with severe Charcot disease.

Contraindications to the use of intramedullary nailing for stabilization and realignment of severe hindfoot and ankle deformities are active infection and a dysvascular limb. Relative contraindications are acute phase Charcot disease, poor glycemic control and nutritional status, peripheral vascular disease, severe comorbidities such as cardiac and renal disease, ulceration, osteomyelitis, and osteoporosis (3).

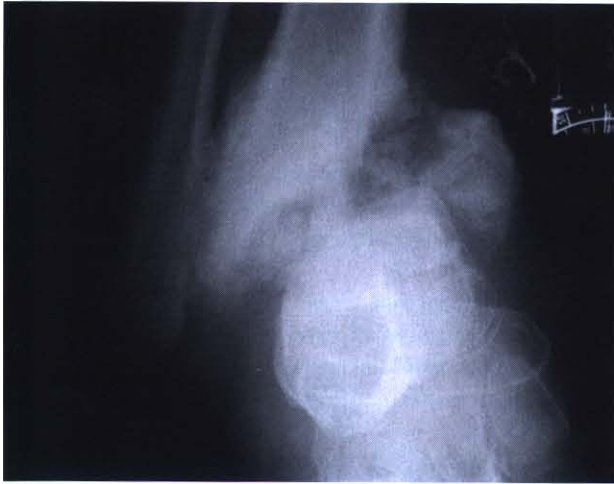### PREOPERATIVE CONSIDERATIONS

Proper identification of the specific disease processes that have resulted in Charcot arthropathy is important in postoperative management. For instance, the union rate of a di-

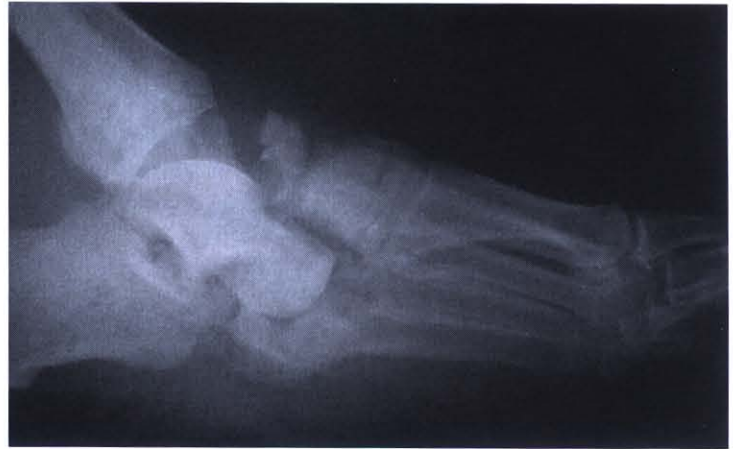

**Figure 34-2.** Clinical photograph: lateral view of the lower extremity showing the angulation and malalignment associated with severe Charcot disease. Note the open pressure ulcer from weightbearing on the distal tip of the fibula. It is important to clear up any signs of soft tissue/bone infection prior to surgical reconstruction.





**Figure 34-3.** Radiographic image: anterior view of the lower extremity showing the severe destruction associated with this Charcot ankle.



**Figure 34-4.** Radiographic image: lateral view of the lower extremity showing the severe destruction associated with severe Charcot disease.

abetic patient will be approximately 163% longer and the healing time for displaced fractures requiring open reduction and internal fixation is increased by about 187%, resulting in prolonged immobilization (4).

It is imperative that adequate identification of all joints involved in the deformity be made. Based on the Brodsky classification, the ankle joint is involved 10% of the time, the hindfoot 20%, the calcaneus 5%, and the midfoot is 60% in Charcot arthropathy (5). Adequate identification of all affected joints is needed prior to realignment planning. Plain film radiographs are adequate for the identification of joint involvement and degree of destruction (Figs. 34-3 and 34-4). Areas of skin breakdown should be evaluated for infection, tracking, and underlying bony involvement. Occasionally, with open ulcerations and underlying bony involvement the need for aggressive bony debridement, intravenous antibiotics, antibiotic beads, or split thickness skin grafting may be required prior to reconstruction. With traditional operative techniques for Charcot arthropathy the surgeon waited until the disease process had "calmed down," or reached a late stage II or stage III, based on the modified Eichenholtz classification (Table 34-1), before surgery was performed (6,7). Although controversial, it has been suggested that early intervention in the acute phase, stage I, may reverse the Charcot process and enable satisfactory healing without complications (2). We feel that the earlier surgical intervention occurs the better the outcome and the less difficult the reconstruction.

Clinical examination should consist of an evaluation of both entire lower extremities. A thorough lower extremity biomechanical and musculoskeletal exam should also be performed. Proper identification of specific joint involvement and the extent of destruction may be accomplished with the use of plain film radiographs, CT, or MRI. If vascular status is in question lower extremity vascular studies should be evaluated prior to surgical intervention.

**Table 34-1.** Modified Eichenholtz classification for Charcot arthropathy

Stage	Phase	Description
0	Acute	Sudden onset of rubor, calor, and tumor, dolor may be present
I	Development	Capsular distention, bony fragmentation
II	Coalescence	Absorption of small fragments, fusion of joints, subchondral sclerosis
III	Remodeling	Decreased sclerosis and revascularization, new bone formation



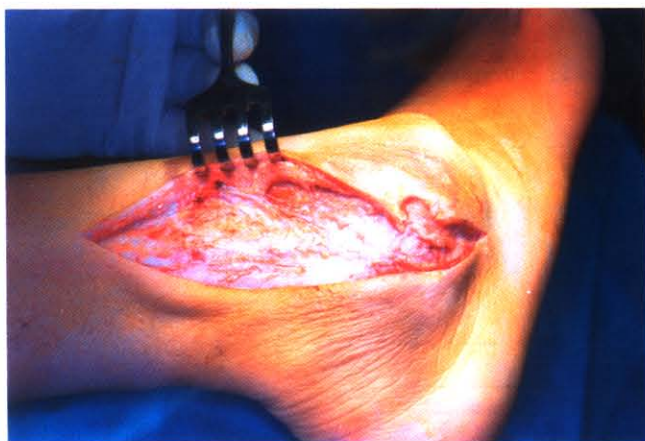Along with the routine laboratory work-up, evaluation of digital pressures,  $TcpO_2$ , serum albumin, hemoglobin A1c, and a total lymphocyte count will help to optimize the postoperative course. The patient must understand the severe nature of the disease process and have a thorough understanding of the demands that surgical reconstruction will require. The patient should understand that extreme compliance, avoidance of smoking, and a well balanced diet will offer the best chance for optimal results. The patient should also be informed of all risks of the procedure, including the loss of limb or life. The reconstructive procedure is considered a limb salvage procedure and often times the only alternative is leg amputation.

When severe disease is present with associated soft tissue infection, a staged surgical reconstruction should be performed. The application of external fixation for temporary management of bone and soft tissue infections should be utilized until infection has been resolved. It is extremely important that the ankle and hindfoot are infection free prior to the insertion of the intramedullary nail system.

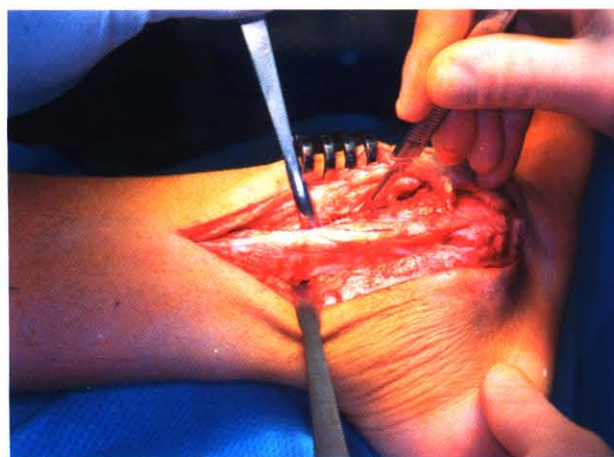### SURGICAL TECHNIQUE

The patient is given prophylactic antibiotics as well as a low molecular weight heparin for postoperative DVT prophylaxis one hour prior to surgery. The patient is placed on the operating room table in the supine position with a hip roll placed under the involved extremity. This positioning will offer the greatest access to the lateral and anterior ankle regions. At this time a pneumatic lower leg boot is applied to the opposite extremity with a compressive support hose. This will help decrease the chance of DVT formation during the surgery. Next a well-padded thigh tourniquet is applied and set for 200 mm/Hg above the patient's preoperative systolic blood pressure. The lower extremity is then prepped just above the knee and draped in the usual sterile manner.

The lateral approach is preferred and begins with a longitudinal incision made over the posterior lateral aspect of the distal one third of the fibula, then curves to extend to the level of the cuboid (Fig. 34-5). Occasionally a posterior approach is required in patients who have previously experienced soft tissue compromise. The preferred lateral incision is deepened to full thickness to the level of bone. At this level care should be taken to avoid sural nerve compromise. If identified, the sural nerve is gently retracted to the closest skin edge. All soft tissue from the distal one third of the fibula is retracted to allow for complete visualization of the bone (Fig. 34-6). This is best performed with use of a

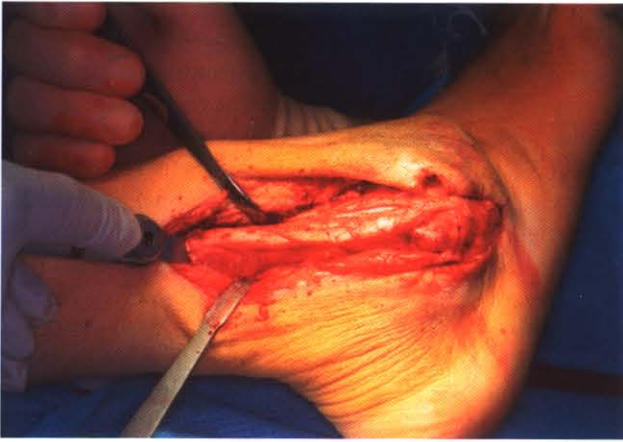

**Figure 34-5.** Incision placement at the posterior border of the fibula extending distally towards the cuboid. Care is taken to avoid injury to the sural nerve in this area.

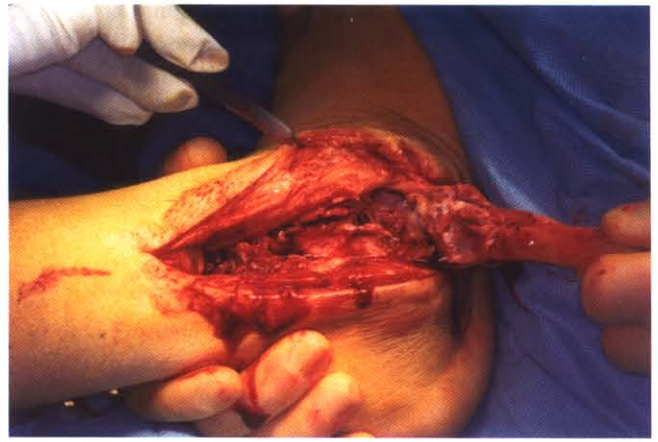

**Figure 34-6.** The fibula is exposed after retraction of the sural nerve. The peroneals are retracted within the posterior full-thickness soft tissue envelope. Maintain full-thickness tissue flaps both anterior and posterior.





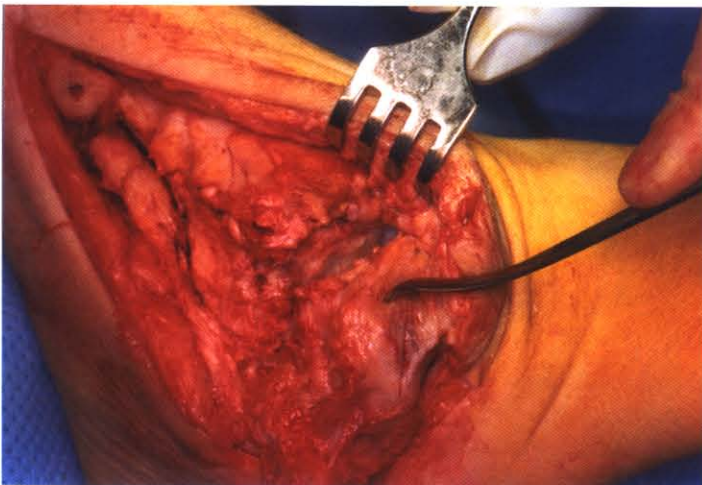
**Figure 34-7.** Intraoperative lateral view showing oblique osteotomy to the distal fibula. The orientation is proximal lateral to distal medial.



**Figure 34-8.** The fibula is now dissected and flapped distally. The calcaneal fibular ligament can be left intact if attachment of the fibula is to be maintained during the case. Usually it is removed and stored on the back table for later use as an on-lay graft.

periosteal elevator and/or a No. 15 blade. At this time a sagittal bone saw is utilized to perform an oblique osteotomy in the fibula in a proximal lateral to distal medial orientation, approximately 8.0–10.0 cm proximal from the distal tip (Fig. 34-7). Depending on the degree of destruction to the ankle and subtalar joint, an attempt is made to free all soft tissue attachments to the fibula with the exception of the calcaneal fibular ligament. This will allow the fibula to be reflected distally and provides excellent visualization of the ankle and subtalar joint (Fig. 34-8). However, in cases of severe destruction complete resection of the distal one third of the fibula may be necessary. If complete resection of a healthy fibula is required, it should be placed on the back table in normal saline for later use as an on-lay graft.

Now that direct visualization of the ankle and subtalar joints can be made, aggressive resection of all diseased bone should be performed (Fig. 34-9). Next, an Achilles tendon

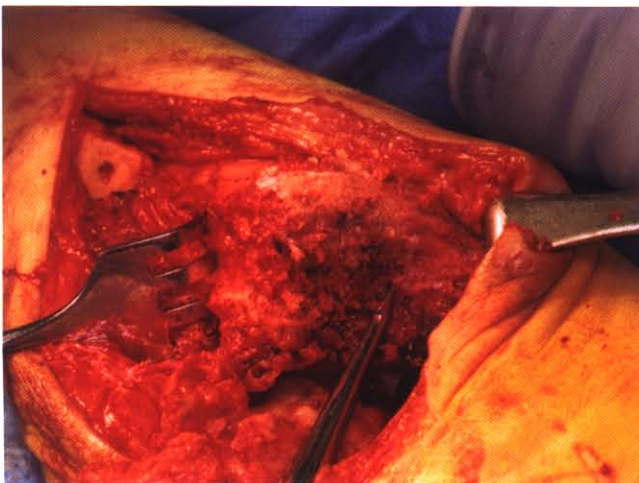


**Figure 34-9.** Exposure to the lateral ankle showing the ankle and subtalar joint with the fibula removed. Hypertrophic and reactive bone tissue is removed at this time.

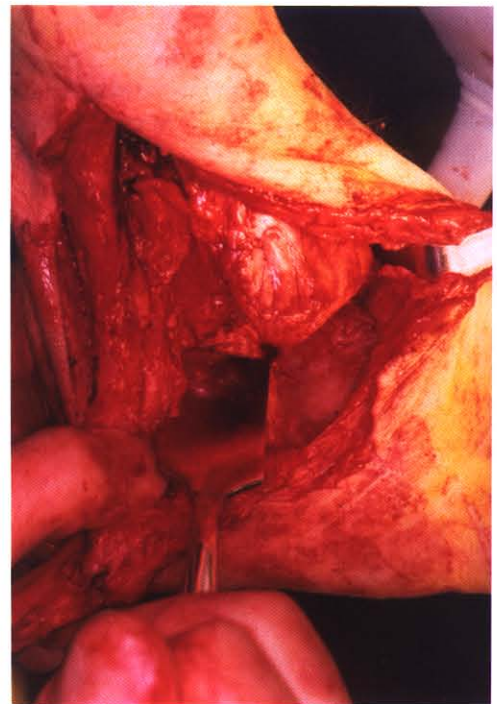


lengthening is performed for those patients with an equinus component. This will allow for easier resection of joint spaces and proper alignment (8). Depending on the degree of deformity and the amount of hypertrophic bone present, a rongeur, osteotome, or sagittal saw may be needed for adequate resection. The diseased bone, depending on the stage of activity, may appear porous and somewhat gray in color compared with normal healthy bone (Fig. 34-10). Rotation of the image counterclockwise 90 degrees was performed for anatomic alignment. It is often difficult to identify joint locations as the diseased bone has “washed” over identifiable joint locations. A Sayer elevator or small osteotome is used to probe through the diseased bone and assist with identification of joint locations and bony anatomy (Fig. 34-11). After all joints are located and resection of all diseased bone has been performed, resection of any articular cartilage remaining from the proposed arthrodesis sites is performed (Fig. 34-12). In our experience the pituitary rongeur is an invaluable instrument for resection of cartilage deep within the medial aspect of the ankle and subtalar joints (Fig. 34-13). Based on the degree of destruction and viability of the talus, a partial or complete talectomy may be required. It has been our experience that a partial talectomy allows for a better, more stable foot to leg construct. At this time, alignment and temporary stabilization of the ankle, hindfoot, and midtarsal joints relative to the leg are performed.

After adequate joint preparation and temporary stabilization have been performed, the first step in intramedullary nailing is placement of a large guide wire through the plantar heel, approximately 3.0 cm distal to the plantar fascial insertion, in direct alignment with the medullary canal of the tibia. It is critical that the guide wire be placed into the central medial aspect of the calcaneus and centered in the medullary canal of the tibia. Note that the body of the calcaneus is lateral relative to the alignment of the tibia in a normal anatomic structure (Fig. 34-14). It is usually necessary to medialize the calcaneus after debridement is performed to get the calcaneus under the central portion of the tibia. Guide wire placement is evaluated using intraoperative fluoroscopy. It is very important at this time to evaluate the entire lower extremity for foot placement at 90 degrees to the lower

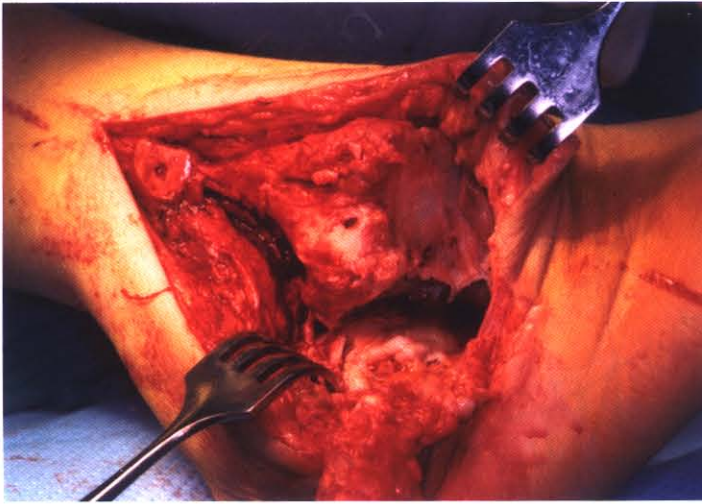


**Figure 34-10.** Intraoperative view showing gray, porous appearance of bone seen in active Charcot disease. All diseased, nonviable tissue needs to be removed from the surgical field in preparation for the arthrodesis.



**Figure 34-11.** The use of a small osteotome to help identify joint spaces and facilitate removal of cartilage tissue.

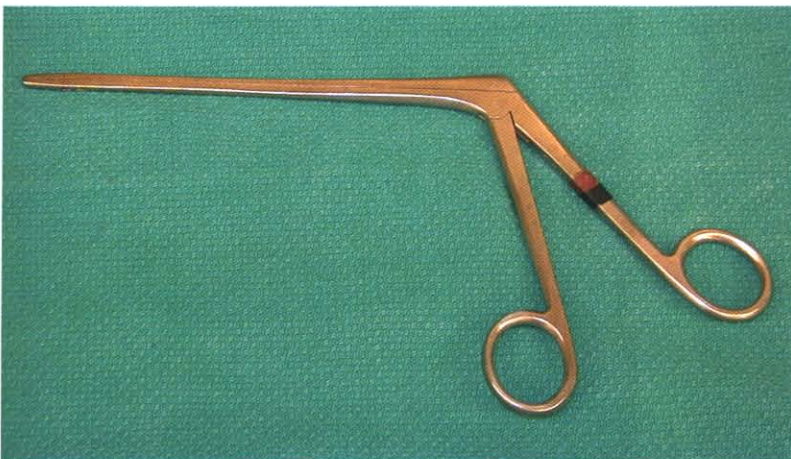




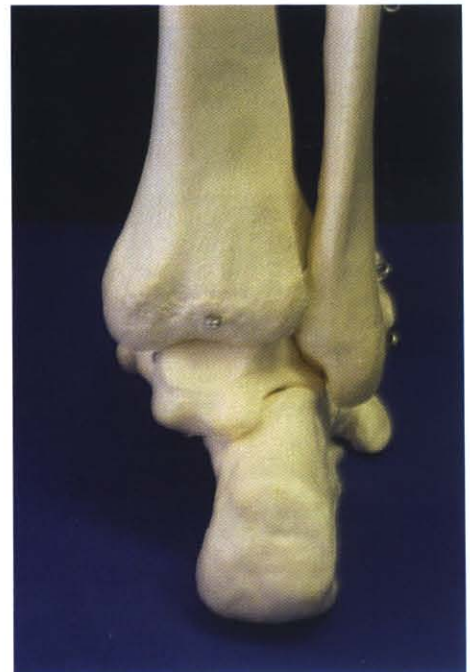**Figure 34-12.** Intraoperative view showing removal of remaining articular cartilage prior to arthrodesis and final joint preparation.

leg, maintaining the heel in a neutral position with 10–15 degrees of external rotation. It is also imperative to avoid excessive transverse plane rotation. It is critical that at this point—prior to the application of the intramedullary nail—the most optimal alignment is obtained.

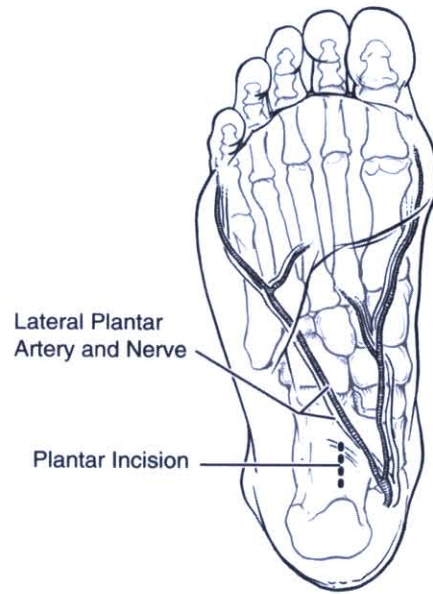
There are many types of intramedullary nail systems with either static or dynamic types of compression, each offering a host of pitfalls and advantages. Attention is directed at the large central guide wire in the plantar heel, which is utilized as a guide for intramedullary



**Figure 34-13.** Example of the pituitary rongeur. This type of instrument has the ability to assist with removal of articular cartilage from the “hard-to-reach” areas, such as the medial subtalar joint.

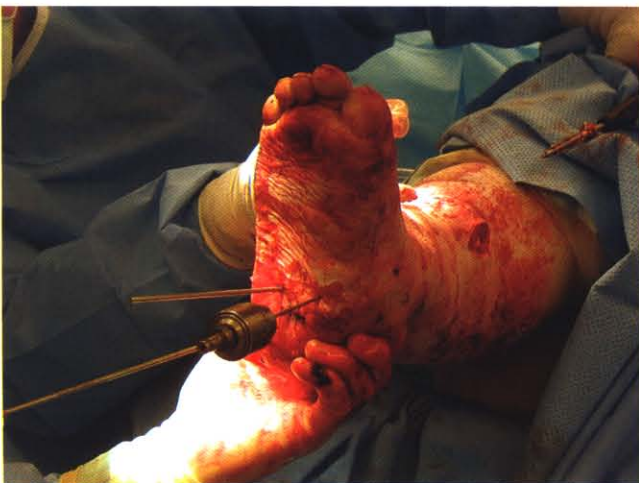

**Figure 34-14.** The ideal alignment of the tibia and the hindfoot bones. Note the calcaneus normally positioned lateral to the longitudinal axis of the tibia.

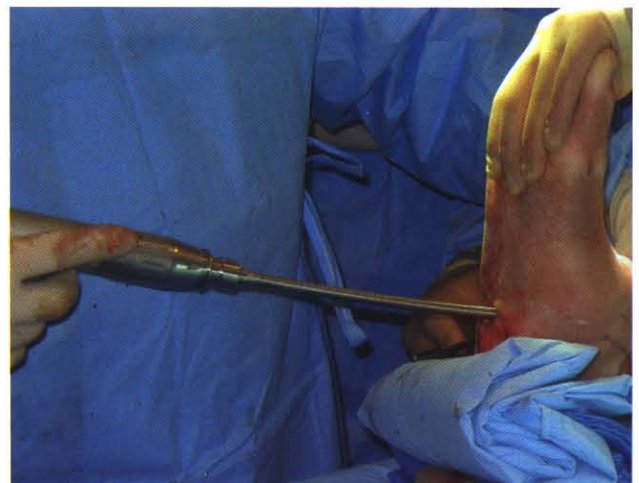


**Figure 34-15.** Plantar view of the calcaneus showing optimal incision placement for avoidance of vital structures and proper alignment with respect to the medullary canal of the tibia.

nail placement. A No. 10 blade is used to make a small transverse incision parallel to the relaxed skin tension lines into the plantar hindfoot (Fig. 34-15). Blunt dissection is carried down to the bone and care is taken to avoid any neurovascular structures, especially the lateral plantar vessels in this area. Next a large drill is used to drill through the calcaneus and into the distal one third of the tibial canal (Fig. 34-16). It is important to continuously recheck alignment in all planes with fluoroscopy throughout the procedure in order to detect any shifting or malalignments that may occur. The reamer is utilized to help determine the optimal length and diameter of nail to be used (Figs. 34-17 and 34-18). If large angular corrections are required, large autogenous corticocancellous bone wedges are incorporated for adjustment in length and for realignment. During the reaming process the surgeon will experience what is referred to as “chatter.” This occurs when maximal diameter has been obtained. It is important to be aware that “fatty” emboli may develop during the reaming process. It is desirable to obtain the largest diameter nail that will fit within the medullary

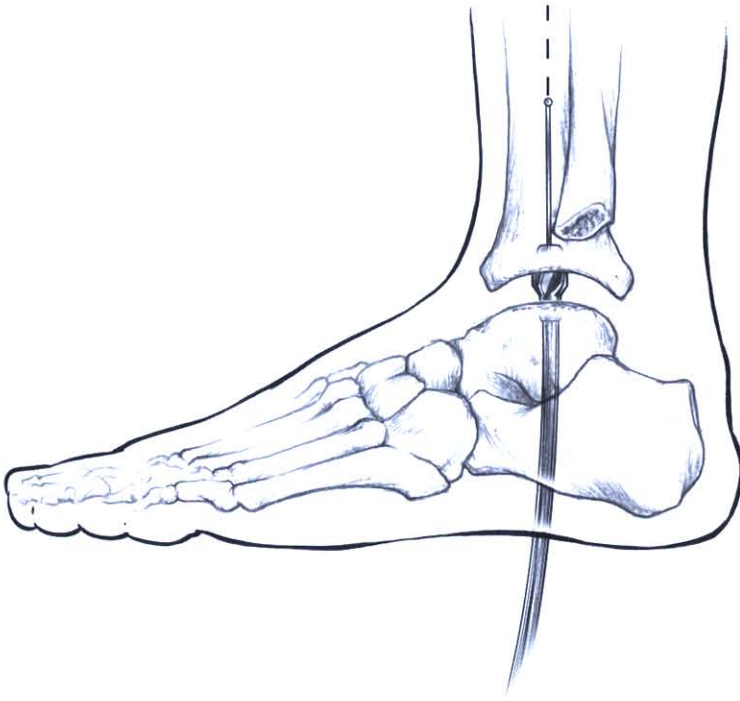


**Figure 34-16.** Intraoperative image showing drilling of the plantar calcaneus into the medullary canal of the tibia. Accurate placement of the drill should be confirmed with intraoperative fluoroscopy before moving further.



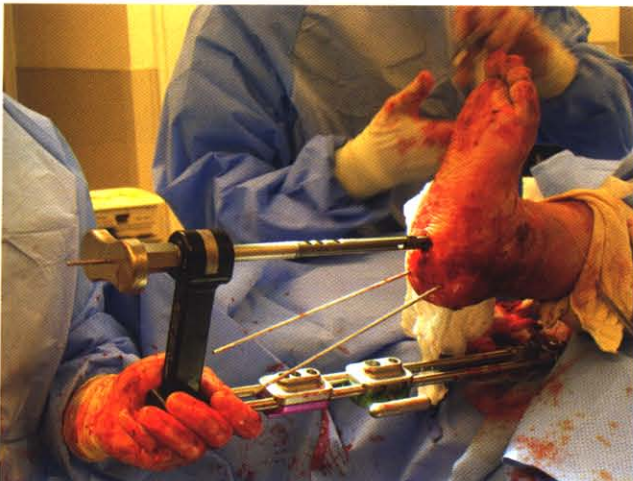
**Figure 34-17.** Intramedullary reaming of the distal tibia is now performed over the central guide wire.



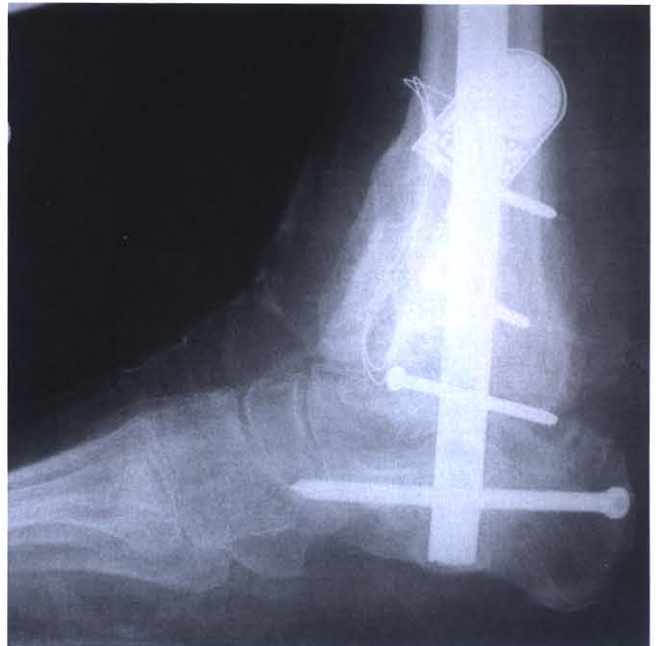

**Figure 34-18.** Drawing showing placement of the intramedullary reamer.

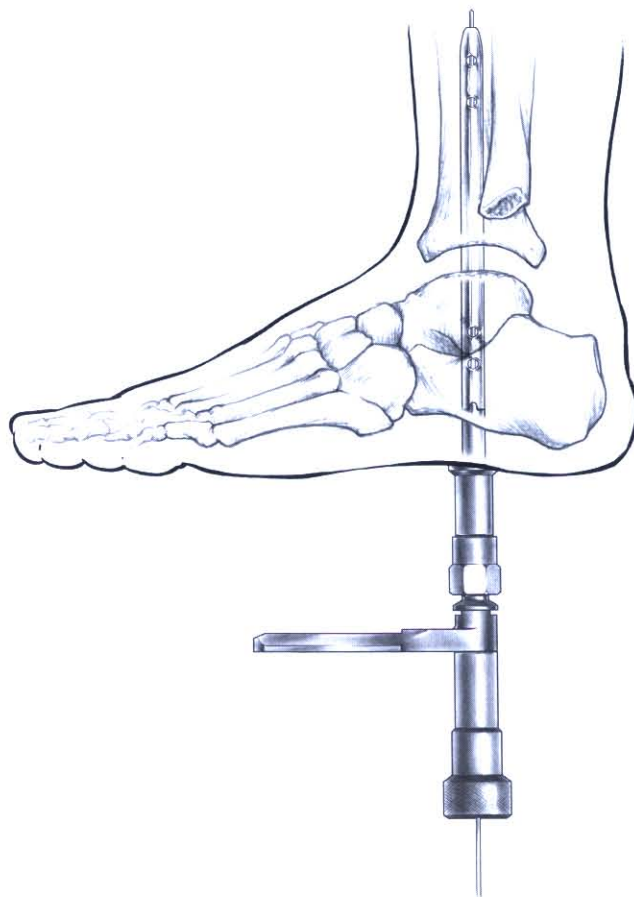
canal for optimal results. Once the nail size has been determined, it is attached to the alignment jig and placed into the canal (Fig. 34-19). The nail is then carefully driven into the tibia until it is slightly recessed into the plantar calcaneus (Figs. 34-20 and 34-21). If a dynamic-type nail system is utilized, the proximal screws are inserted first through the guide assembly and then into the tibia (Fig. 34-22). At this time compression is applied by tight-



**Figure 34-19.** Photograph showing nail placement with the assistance of the alignment jig prior to insertion. The jig will greatly facilitate alignment and placement of all the bone screws.

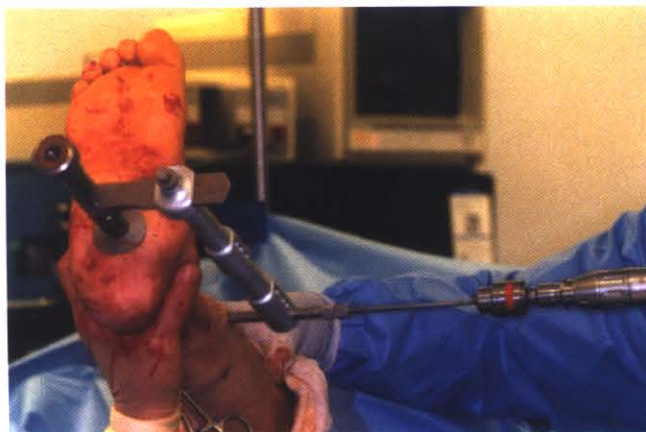

**Figure 34-20.** Intraoperative radiograph showing orientation of the intramedullary nail with respect to the plantar calcaneus. Note the distal tip of the nail is just within the cortical surface of the bone.

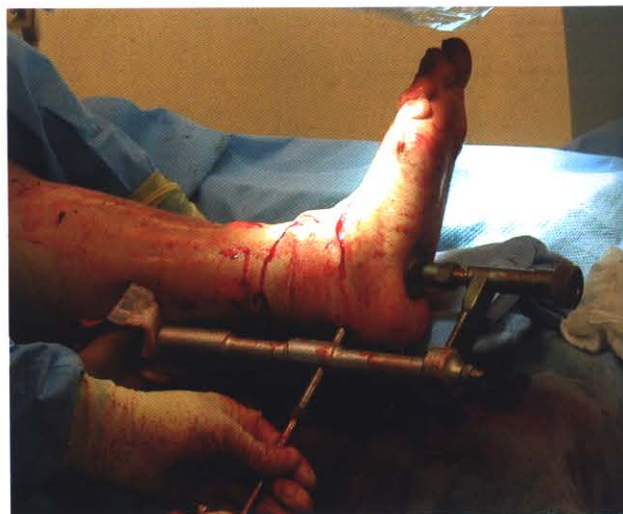

**Figure 34-21.** Drawing showing orientation of the distal nail with the calcaneus.

ening the compression nut until the desired compression is achieved. When the desired amount of compression has been achieved, the distal screws are inserted in the calcaneus to maintain compression and position (Fig. 34-23). If a static type nail system is employed, an attempt to align the distal most nail with the plantar calcaneus is made and the distal-most transfixation screw is placed first. At this time manual compression is applied from



**Figure 34-22.** Intraoperative image showing proximal screw insertion into the medial tibia. This is placed after compression is applied within a dynamic nail system.

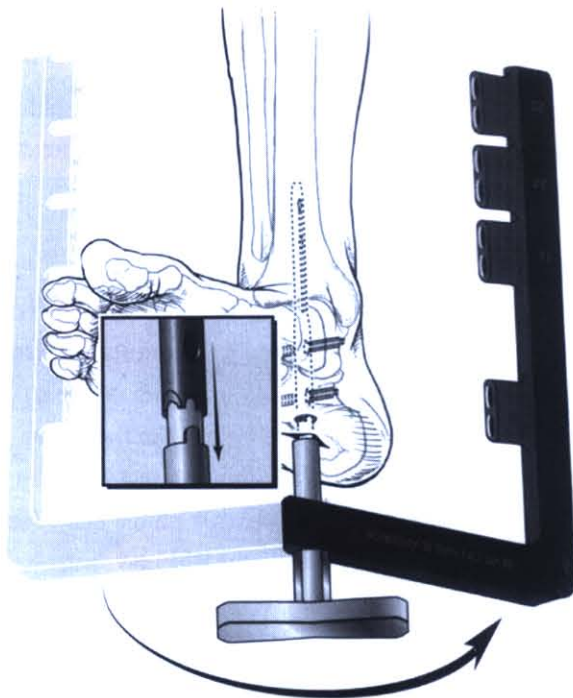


**Figure 34-23.** Intraoperative image showing distal posterior screw insertion.

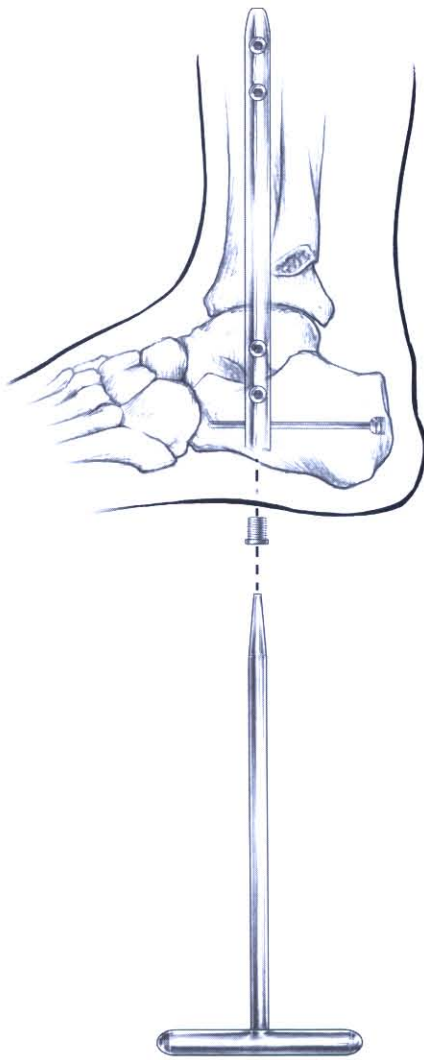


distal to proximal and the proximal tibia transfixation screws are inserted. With select nail systems a posterior to anterior screw placement is offered. This is more desirable than the lateral to medial placement due to the increased amount of bone purchase. If a posterior to anterior screw is not offered, the desired distal calcaneal transfixation screw is optimally placed in a lateral to medial direction, offering the least risk to vital structures. When inserting the proximal screws, the jig is partially loosened; the notch at the nail jig interface is carefully distracted only enough to allow for 180-degree rotation. This will offer proximal transfixation screw placement from a medial to lateral orientation, again avoiding vital structures (Fig. 34-24). After removal of the guide assembly an optional end cap can be inserted to prevent any fibrous ingrowth (Fig. 34-25). It will offer an advantage only if removal of the nail is required.

Now that the ankle and hindfoot are stabilized any osseous voids should be packed with some form of bone graft, preferably mixed with 10 mL of the patients own blood to create a "slurry," or autogenous bone graft factor can be used (Figs. 34-26 and 34-27). This slurry is then crushed up with rongeurs into a fine mixture and placed into all voids. If desired, the incorporation of internal bone stimulation can be inserted at this time along the arthrodesis site to help stimulate osseous union and shorten recovery time (Fig. 34-28). Care must be taken to avoid any contact with internal fixation as this may decrease the effectiveness of internal stimulation. The distal fibula is decorticated medially and the ankle joint complex laterally to allow the fibula to be reinserted as an on-lay graft for added stability (Figs. 34-29 and 34-30). The incision is then flushed with irrigation solution. Care is taken not to wash away any bone graft. The tourniquet is deflated and visual inspection of the incision for any large bleeders is performed. Any bleeders found should be cauterized or ligated as necessary. A closed suction drain is inserted through the plantar midfoot and placed along the incision site to reduce hematoma formation. Closure of the incision is performed in layers and the incisions are covered with a compressive, dry, sterile dressing (Fig. 34-31). The lower extremity is then placed into a modified Jones compressive cast.



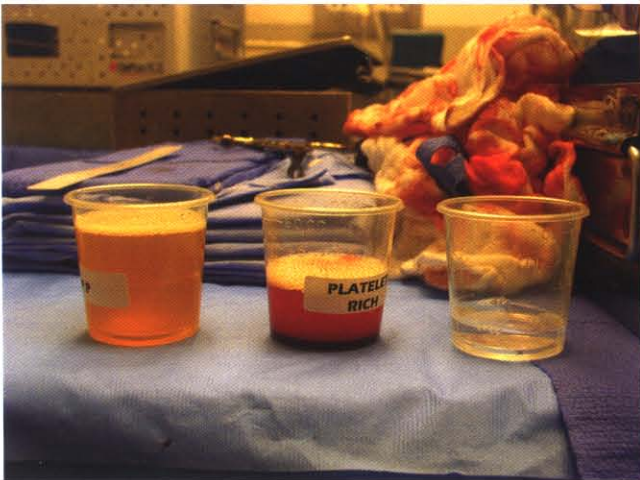**Figure 34-24.** Illustration showing the medial to lateral orientation of the proximal transfixation screw. This is nicely facilitated by reorientation of the jig from lateral to medial.



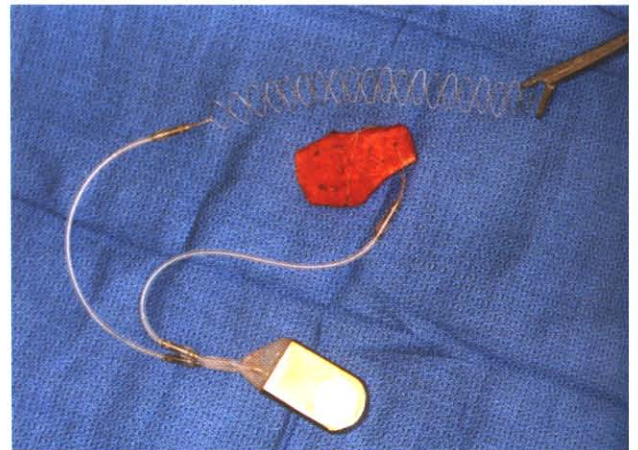**Figure 34-25.** Drawing showing the incorporation of the distal end cap.



**Figure 34-26.** Preparation of the bone graft for the procedure. In this case, the graft is made from allogenic cancellous bone chips. This can be mixed with the patient's own blood to create a "slurry" of osteoinductive bone tissue for packing all open areas.

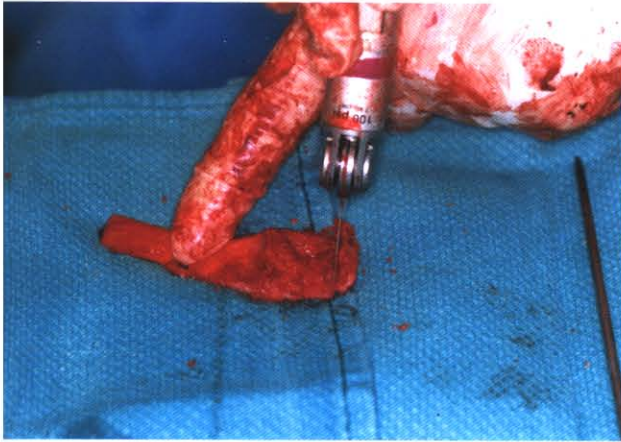


**Figure 34-27.** Platelet rich autogenous mixture can also be prepared in the operating room to facilitate bone healing. The blood is centrifuged to separate the growth factors from remaining serum.

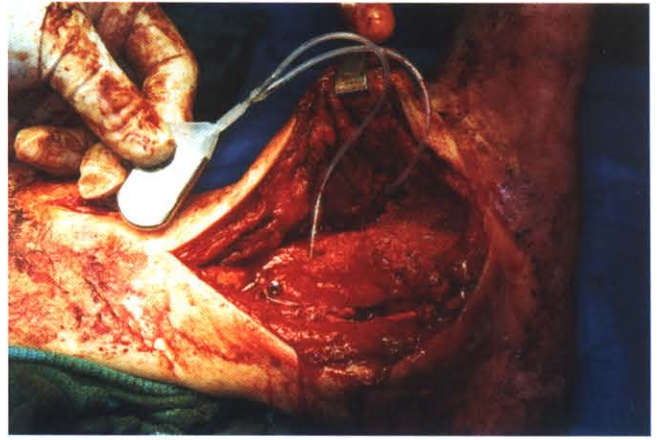


**Figure 34-28.** Intraoperative image showing internal bone stimulator incorporation into the fibular on-lay graft. This stimulator has two leads for placement and the second lead will be woven within the arthrodesis site. Care is taken to avoid contact of the stimulator leads with internal/external fixation.





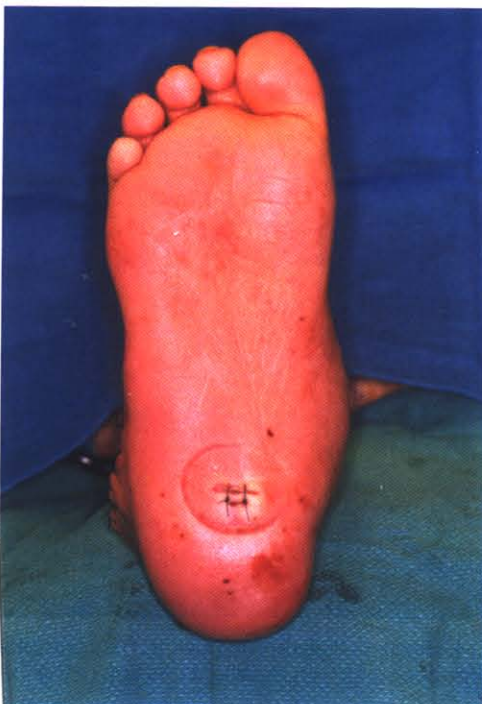**Figure 34-29.** Decortication of the fibula with a sagittal saw in preparation for the on-lay graft. The medial cortex is removed and this is applied to the decorticated lateral tibial-talar-calcaneal construct.



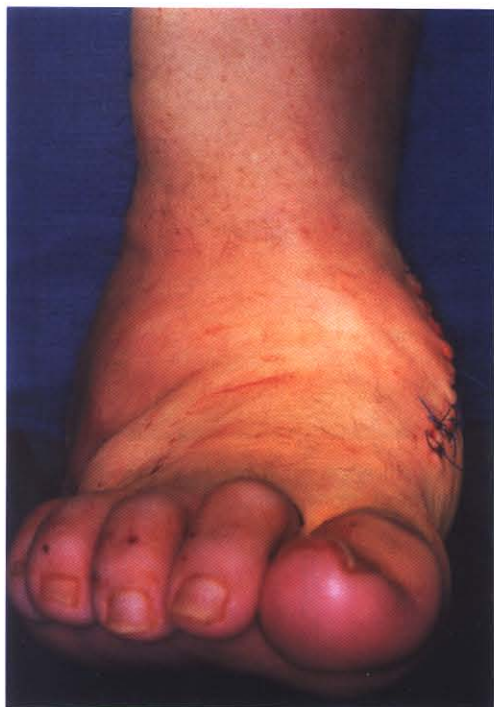**Figure 34-30.** Intraoperative image showing incorporation of fibular on-lay graft, bone stimulator, and allograft bone-chip "slurry."

## POSTOPERATIVE MANAGEMENT

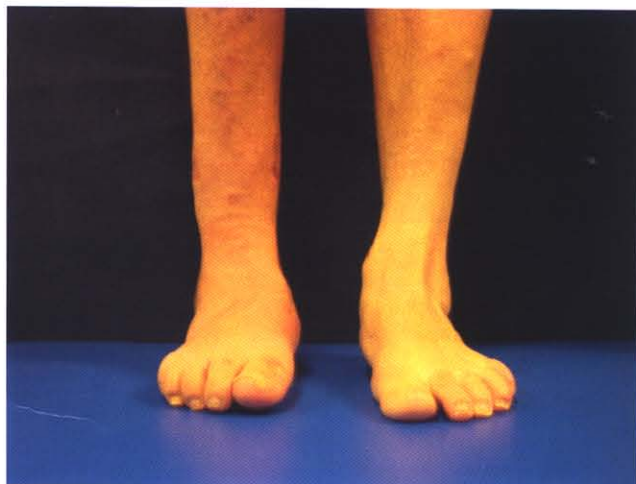The patient is generally kept as an inpatient for 2 or 3 days, remaining nonweightbearing in the hospital to ensure adequate control of any bleeding and pain management. The drain is pulled on postoperative day 2, unless significant drainage continues, at which time an additional day before the drain is removed is recommended. The patient is kept nonweightbearing until radiographic osseous union occurs, generally 8 weeks. The original cast is removed after the second week and incision site inspection is performed. A new below-the-knee cast is applied and the patient followed up accordingly. At this time the patient is seen every 4 weeks and radiographic evaluation performed. Once radiographic and clinical union has occurred the patient is placed in a removable walking cast for an addi-



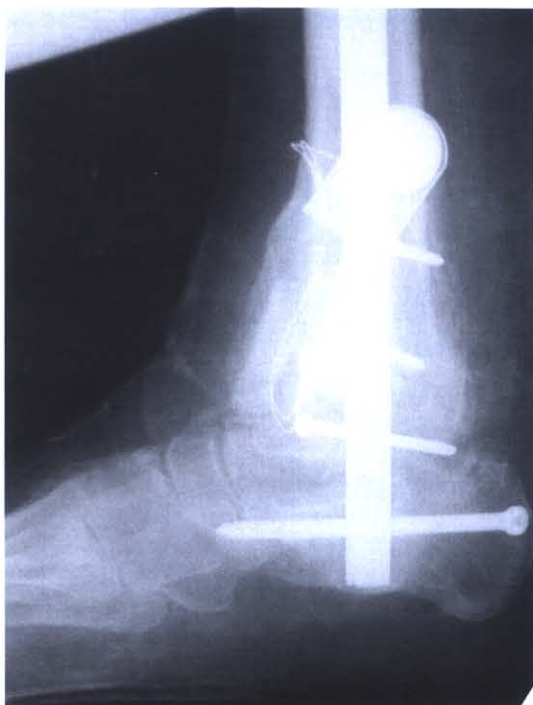**Figure 34-31.** Postoperative plantar view showing residual compression ring impression and site of hardware placement.



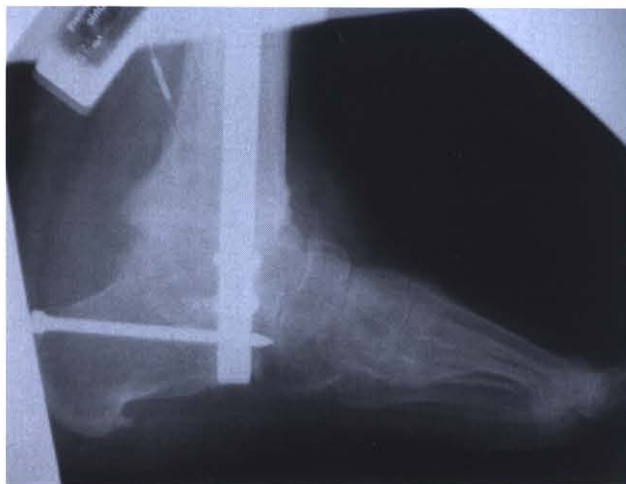**Figure 34-32.** Immediate postoperative clinical view of the patient in Figure 34-1 showing correction and alignment obtained.



**Figure 34-33.** Postoperative follow-up weightbearing view of the same patient showing correction maintained at 8 weeks with minimal edema present.



**Figure 34-34.** Postoperative lateral view radiograph showing proper placement of hardware. The cortical screws are holding the on-lay graft in place along the lateral ankle.



**Figure 34-35.** Lateral radiograph showing radiographic union at the arthrodesis site with excellent position of the foot and leg.



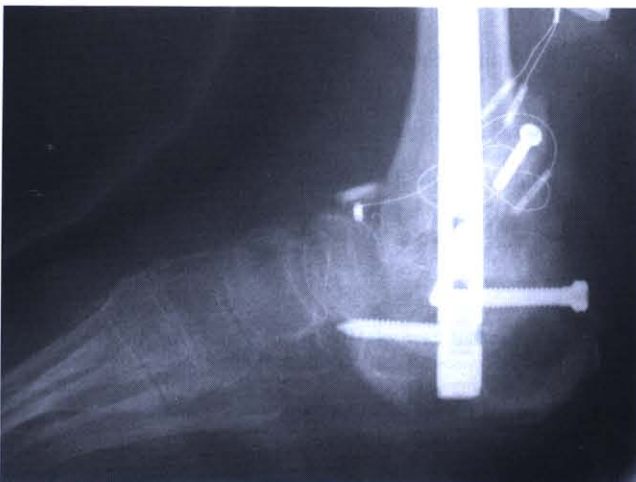tional 4–6 weeks. After complete union has occurred the patient is allowed full weight-bearing and instructed to wear compressive stocking to help reduce edema (Figs. 34-32 through 34-35). The patient will most likely require some form of custom molded shoe gear or inserts to help eliminate breakdown of any high pressure areas.

## COMPLICATIONS

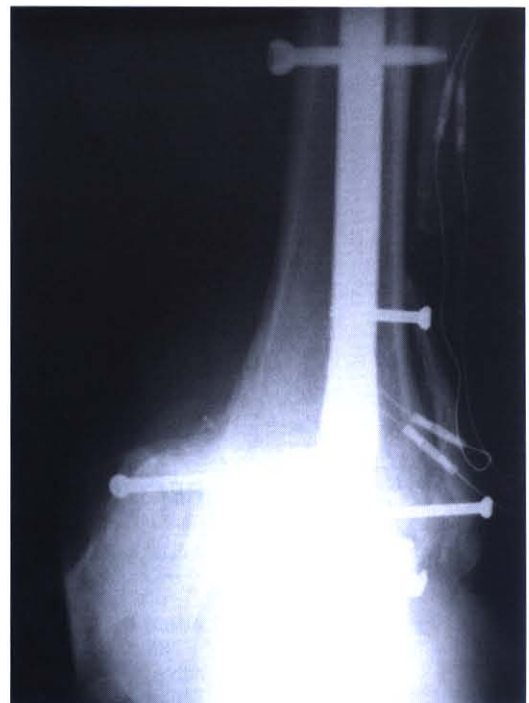General complications include nonunion, delayed union, and malunion and may result from an inadequate amount of resection of diseased bone and possible hardware failure. If a nonunion occurs with no gross evidence of hardware failure, the result may be uneventful as long as clinical stability and alignment is maintained. Nonunions generally are not painful in this population due to the degree of neuropathy present. Malunion, on the other hand, can be very difficult to manage and may require additional surgery for correction. Other complications include wound dehiscence, infection, proximal tibia fracture, stress fracture while inserting the nail, and fracture of the calcaneus (Figs. 34-36 through 34-38). At the first sign of wound dehiscence or infection aggressive treatment is instituted with the appropriate wound care management and antibiotics. It is important to address any complication, whether it is soft tissue breakdown or hardware failure, with extreme urgency as these failures often result in below-the-knee amputation.

## CLINICAL TIPS AND PEARLS

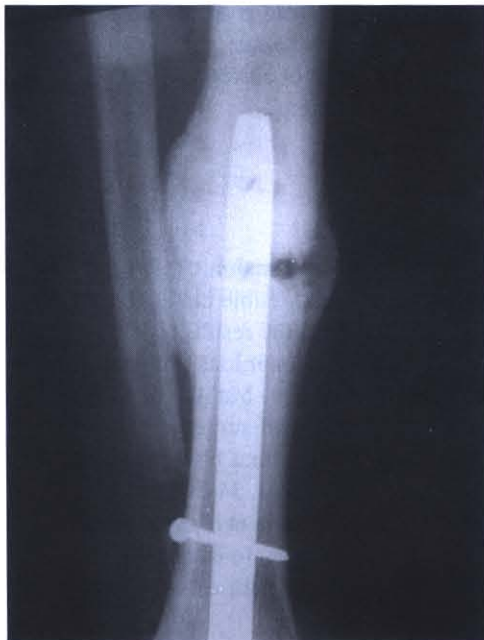1. We have found adequate patient preparation, including a thorough discussion of surgeon/patient goals and expectations, to be an invaluable key to perioperative compliance.
2. Always ensure that tissue handling is delicate and respectful. This will minimize the risk of postoperative wound dehiscence.



**Figure 34-36.** Lateral view radiograph showing nonunion of the ankle joint resulting from calcaneal fracture and hardware failure



**Figure 34-37.** Anterior view radiograph showing nonunion of the ankle joint with malalignment resulting from calcaneal fracture and hardware failure.



**Figure 34-38.** Radiographic image showing a patient who experienced a proximal tibial stress fracture. The proximal screws were removed and the patient was immobilized.

3. Intraoperative, aggressive, diseased bone resection is imperative to successful alignment and reconstruction of the lower extremity to foot complex.
4. Adequate resection of all cartilage will help ensure a timely union. Utilization of the pituitary rongeurs will help with the “hard to reach” areas.
5. Always ensure that proper foot to leg positioning is obtained prior to insertion of the intramedullary nail system.

## REFERENCES

1. Myerson, MS, Alvarez RG, Lam PW: Tibiocalcaneal arthrodesis for the management of severe ankle and hindfoot deformities. *Foot Ankle Int* 21: 643–650, 2000.
2. Simon SR, Tejwani SG, Wilson DL, et al.: Arthrodesis as an early alternative to nonoperative management of Charcot arthropathy of the diabetic foot. *J Bone Joint Surg* 82-A: 939–950, 2000.
3. Fox IM, Shapero C, Kennedy A: Tibiotalocalcaneal arthrodesis with intramedullary interlocking nail fixation. *Clin Podiatr Med Surg* 17: 19–31, 2000.
4. Loder T: The influence of diabetes mellitus on the healing of closed fractures. *Clin Orthop* 232: 210–216, 1998.
5. Brodsky JW, Rouse AM: Exostectomy for symptomatic bony prominences in the diabetic Charcot feet. *Clin Orthop* 296: 21–26, 1993.
6. Eichenholtz SN: *Charcot Joints*. Springfield, Ill: Charles C. Thomas, 1966: 7–8.
7. Yu GV, Hudson JR: Evaluation and treatment of stage 0 Charcot’s neuroarthropathy of the foot and ankle. *J Am Podiatr Med Assoc* 92: 210–220, 2002.
8. Armstrong DG, Peters EJ: Charcot’s arthropathy of the foot. *J Am Podiatr Med Assoc* 92: 390–394, 2002.

## RECOMMENDED READING

- Adams HB, Blasko GA, DiDomenico LA: An unusual case of bilaterally symmetrical neuropathic osteoarthropathy of the midfoot as a result of Lyme disease-induced peripheral neuropathy: a case report. *Foot Ankle Int* 23: 155–157, 2002.
- Adams JC: Arthrodesis of the ankle joint: experiences with the transfibular approach. *J Bone Joint Surg* 20: 506–511, 1948.
- Albee FH: *Bone Graft Surgery*. Philadelphia: W. B. Saunders, 1915: 335.
- Berend ME, Glisson RR, Nunley JA: A biomechanical comparison of intramedullary nail and cross screw fixation for tibiotalocalcaneal arthrodesis. *Foot Ankle Int* 18: 639–643, 1997.
- Bingold AC: Ankle and subtalar fusion by a transarticular graft. *J Bone Joint Surg* 38: 862–870, 1956.
- Fleming S, Moore TJ, Hutton WC: Biomechanical analysis of hindfoot fixation using an intramedullary rod. *J South Orthop Assoc* 7: 19–26, 1998.



- Johnson KA, Gehrke JC: Intramedullary fixation for ankle arthrodesis. Proceeding of the Annual Summer Meeting of the American Orthopedic Foot and Ankle Society, 1993.
- Kile TA, Donnelly RE, Gehrke JC, Werner ME, Johnson KA: Tibiotalocalcaneal arthrodesis with an intramedullary device. *Foot Ankle Int* 15: 669–672, 1994.
- Kirkpatrick JS, Goldner JL, Goldner RD: Revision arthrodesis for tibiotalar pseudoarthrosis with fibular onlay-inlay graft and internal screw fixation. *Clin Orthop* 268: 29–36, 1991.
- Kitaoka HB, Anderson PJ, Morrey BF: Revision of ankle arthrodesis with external fixation for non-union. *J Bone Joint Surg* 74: 1191–2000, 1992.
- Leikkonen O: Astragalectomy as an ankle stabilizing operation in infantile paralysis sequelae. *Acta Chir Scand Suppl* 152: 13–149, 1948.
- Levine SE, Myerson MS, Lucas P, Schon LC: Salvage of pseudoarthrosis after tibiotalar arthrodesis. *Foot Ankle Int* 18: 580–585, 1997.
- Myerson MS, Alvarez RG, Lam PW: Tibiocalcaneal arthrodesis for the management of severe ankle and hindfoot deformities. *Foot Ankle Int* 21: 643–650, 2000.
- Moore TJ, Prince R, Pochatko D, Smith JW, Fleming S: Retrograde intramedullary nailing for ankle arthrodesis. *Foot Ankle Int* 16: 433–436, 1995.
- Pinzur MS, Kelikian A: Charcot ankle fusion with a retrograde locked intramedullary nail. *Foot Ankle Int* 18: 699–704, 1997.
- Quill GE Jr: The use of a second generation intramedullary nail in fixation of difficult ankle and hindfoot arthrodeses. *Am J Orthop* (suppl), 1999.
- Russotti GM, Johnson KA, Cass JR: Tibiotalocalcaneal arthrodesis for arthritis and deformity of the hind part of the foot. *J Bone Joint Surg* 79: 1304–1307, 1988.
- Steinberg J: Diabetes watch: what NIH statistics reveal about diabetes prevalence. *Podiatry Today* 15: 16–18, 2002.
- Stephenson KA, Kile TA, Graves SC: Estimating the insertion site during retrograde intramedullary tibiotalocalcaneal arthrodesis. *Foot Ankle Int* 17: 781–782, 1996.